



MRI in Clinically Suspected Uterine and Adnexal Lesions- the Conflict Resolved

Authors

Dr Divyashree¹, Dr Surabhi Mehrotra², Dr Arjun Raju P³

M.D. Radiodiagnosis , Department of Radiodiagnosis , Government Medical College and Dr Susheela Tiwari Memorial Hospital , Haldwani, Nainital, Uttarakhand- 263139

Email: divya.pulakpuneet@gmail.com, surabhimehrotra175@gmail.com, arjunraju1988@yahoo.com

Abstract

Background: *The purpose of this study was to evaluate the role of Magnetic Resonance imaging (MRI) in evaluation of clinically suspected uterine and adnexal lesions.*

Aim of Study: *To evaluate the role of Magnetic Resonance Imaging in evaluation of uterine and adnexal lesions and to document the imaging characteristics and accuracy rates of MRI in patients with clinically suspected lesions.*

Methods: *The study was a prospective study conducted on conducted on a number of 97 patients with clinically suspected uterine and adnexal lesions.*

Results: *MRI was highly accurate in diagnosis and characterization of uterine and adnexal lesions. It proved effective in diagnosing early cases of cervical and endometrial carcinoma. It had a better accuracy in characterization of lesions as benign and malignant.*

Key Words: *MRI , uterine , adnexal lesions.*

INTRODUCTION

Magnetic Resonance Imaging (MRI) is being increasingly used to evaluate various female pelvic pathologies. It has the advantage of nonuse of ionizing radiation which is an important consideration in women of reproductive age. Another advantage is that MRI is less observer dependent than the classic imaging techniques as Ultrasonography (USG). Also MRI has high contrast resolution with complete view of entire pelvis. It has good tissue resolution and has multiplanar imaging capabilities. Owing to its multiplanar imaging capabilities and excellent tissue characterization, MRI can facilitate definitive diagnosis of conditions of the female

pelvis. Magnetic Resonance imaging is considered to be a problem-solving technique in the assessment of adnexal masses⁽¹⁾. Another advantage of MRI is its excellent tissue-differentiating capabilities.

MRI of the pelvis in some clinical situations can obviate surgery or change a planned surgical procedure, alter medical treatment, and decrease health care costs, particularly after an inconclusive sonogram of the adnexa has been obtained.

Magnetic Resonance imaging continues to be an integral problem-solving modality in the evaluation of congenital uterine anomalies and acquired diseases of the female genital tract organs and provides effective clinical information

to the practicing gynaecologist. MRI is often used as a problem-solving tool in patients where ultrasound is inconclusive or sub-optimal. MRI has a pivotal and established role in detection and staging of gynaecological malignancy. The exquisite soft tissue resolution of MRI allows accurate demonstration of tumour size, location, extension and nodal involvement⁽²⁾.

MRI is a useful non invasive tool for demonstrating anatomy and pathology of female pelvis. It is used to determine the origin and characterization of the mass lesion and to determine the likelihood of malignancy. Since MRI is more expensive and potentially less readily available than USG, it is important to know when patients should undergo MRI. The use of MRI will prove to be cost-effective in that it reduces unnecessary surgical procedures by its ability to differentiate benign and malignant lesions accurately.

Also MRI is the most accurate imaging technique for detection and localization of leiomyomas. Magnetic resonance imaging has also a role in treatment of leiomyomas by assisting in surgical planning and monitoring the response to medical therapy⁽³⁾.

It is now the primary technique of choice in the staging of pelvic malignancy, with the exception of staging ovarian malignancy, where CT is the preferred technique⁽⁴⁾. MRI is a reliable staging method for preoperative assessment of endometrial and cervical carcinoma. MRI can obviate invasive procedures, such as cystoscopy, proctoscopy, and sigmoidoscopy, and thus can reduce staging costs and morbidity. For the detection of advanced stage disease, sensitivities for MR imaging is higher than CT and International Federation of Gynecology and Obstetrics (FIGO) clinical staging. Also the parametrial spread and staging cannot be assessed accurately by other modalities like Ultrasonography (USG), which largely decides the surgeon plan of management. So MRI is the preferred modality of choice.

Adnexal masses which are found to be sonographically indeterminate of uncertain origin and solid or cystic content can be further evaluated with MRI, which is highly accurate for identifying the origin of a mass and characterizing its tissue content.

Thus, MRI can be very useful in characterization and origin of uterine and adnexal masses, staging of known endometrial and cervical cancers, differentiating benign from malignant lesions where other imaging modalities are inconclusive.

AIMS AND OBJECTIVES

The present study was aimed at evaluating the role of Magnetic Resonance Imaging in evaluation of uterine and adnexal lesions and to document the imaging characteristics Haldwani (Nainital).

The primary objectives were to assess the role and evaluate accuracy of magnetic resonance imaging in diagnosis and characterization of uterine and adnexal lesions. Other objectives were to determine which patients may benefit from magnetic resonance imaging and to characterize the uterine and adnexal lesions as benign or malignant. Also to assess its role in staging of cancer when a mass is noted to have malignant changes. To assist the surgeons in deciding on further line of management. To determine the origin, tissue content and characterization of sonographically inconclusive uterine and adnexal masses.

MATERIALS AND METHODS

A prospective study was conducted on a total number of 97 patients with clinical suspected uterine and adnexal lesions at Susheela Tiwari Hospital Haldwani, Uttarakhand. Imaging was done with 1.5 Tesla Siemens machine using abdominal surface coils with appropriate sequences which included axial, sagittal and coronal T1W and T2W spin echo sequences, a Trufi sagittal sequence and post contrast gadolinium T1W fat suppressed study as and when required.

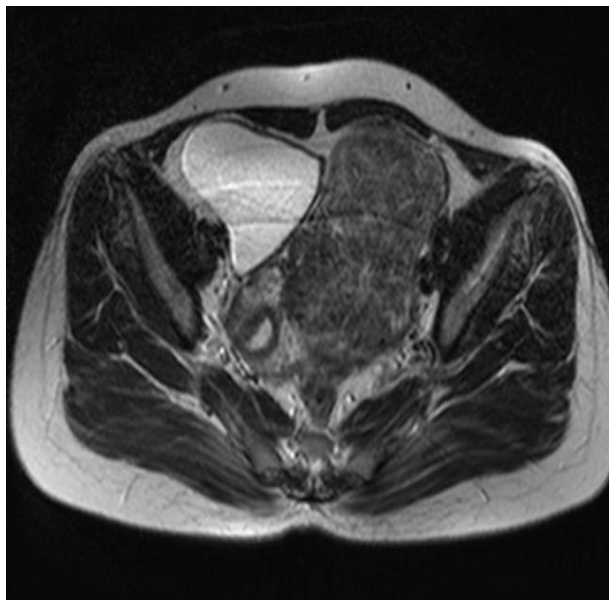


Figure 1. MRI axial T2 W images of Broad ligament fibroid. A large well defined mass lesion is seen in the left adnexal region closely abutting the left lateral wall of uterus and displacing the uterus towards the right side.

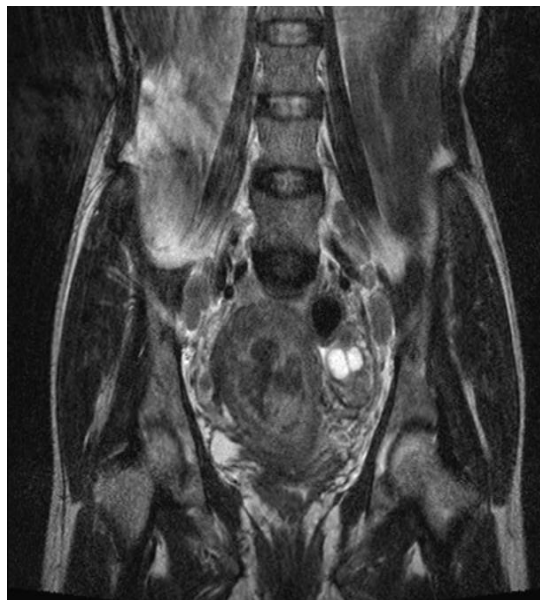

Figure 3. MRI coronal T2 W image of endometrial carcinoma. Reveals bulky uterus with ill defined heterogenous altered signal intensity mass lesion within the endometrial canal focally invading the myometrium. Also multiple enlarged bilateral common iliac lymph nodes seen.

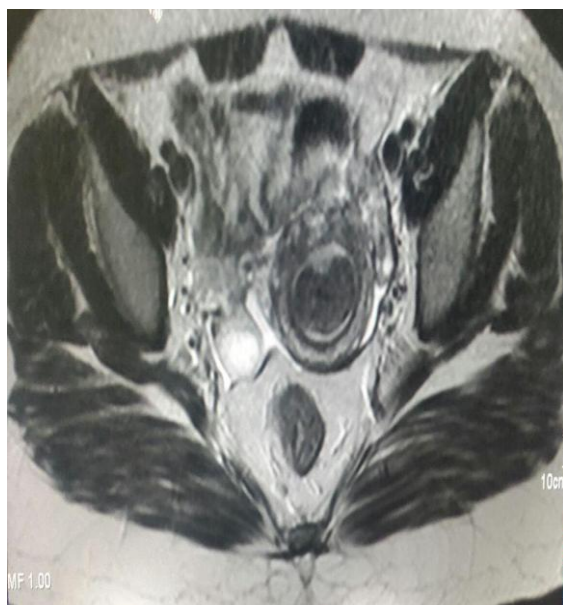

Figure 2. MRI axial T2 W image of submucosal fibroid. Showing a well marginated typically hypointense lesion within the endometrial cavity.

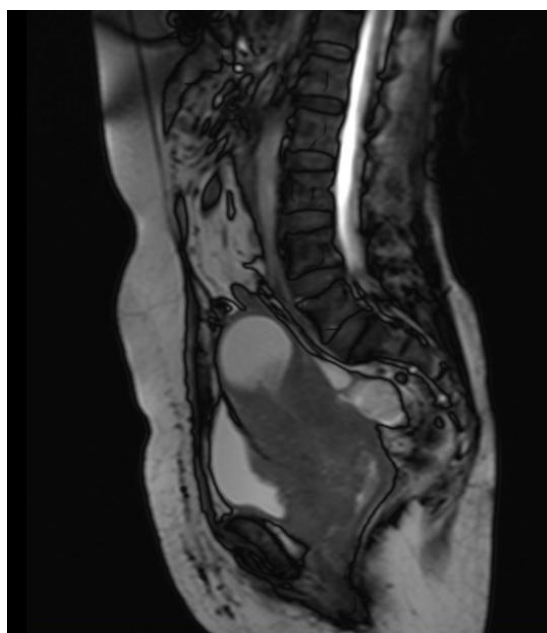


Figure 4. Saggital T2 W image of carcinoma cervix. Showing growth at the endocervical canal with consequent stenosis and formation of pyometra. There is extension and infiltration of the mass lesion anteriorly into the posterior wall of urinary bladder.

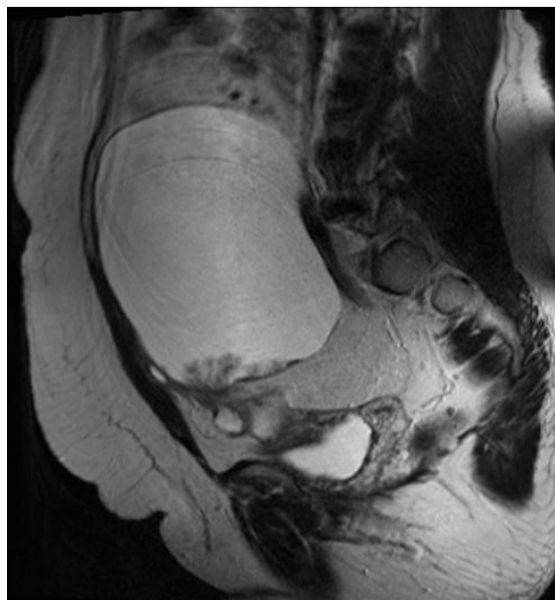


Figure 5. MRI saggital T2 W image of malignant ovarian mass lesion. Showing a large ovarian cystic lesion with papillary projections (Later on proved to be a malignant surface epithelial ovarian carcinoma).

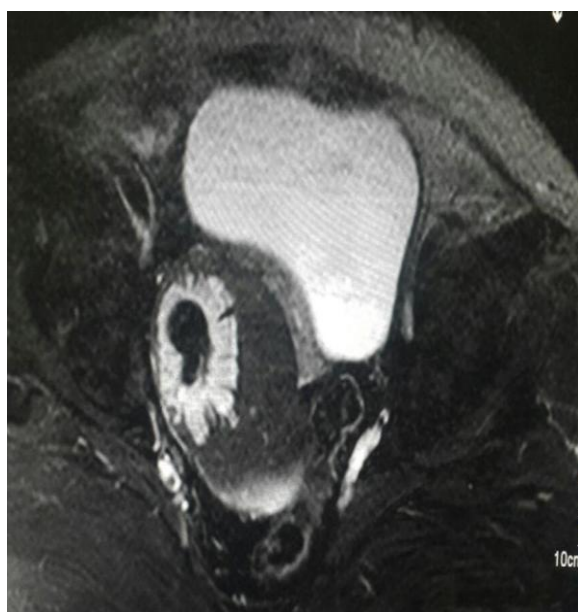

Figure 6. Fat suppression of the right adnexal mass lesion is seen, suggestive of fat component within the lesion.

RESULTS AND DISCUSSION

This was a prospective cross sectional study carried out in Kumaon region of Uttarakhand at Dr Susheela Tiwari Government Hospital in the department of Radiodiagnosis from October 2014 to September 2016 in patients with clinical

suspicion of uterine and adnexal pathologies and / or sonographically indeterminate uterine and adnexal lesions during the study period. In the present study, a total of 97 patients having uterine and adnexal masses were subjected to Magnetic resonance imaging and were evaluated. Most common site in the study was uterine region (79.4%) followed by adnexae (20.4%).

In our study, the maximum patients were in the age group of 41 -50 years (31.9%). The next age group with maximum number of patients was 31-40 years (22.7%).

The most common presentations in patients were menorrhagia (36%), irregular bleeding per vaginum (36%) followed by pelvic pain (20.6%).

In our study, MRI was the most accurate in imaging of leiomyomas with an accuracy of 96.7%. In our study, 40 patients of leiomyomas were included. The patients were kept in follow up and the MRI findings were finally confirmed with the operative findings. The accuracy of MRI was superior to that of USG in detection and localization of leiomyomas (80%).

A total of 8 patients of endometrial carcinoma were included. Correlation of the diagnostic accuracy of MRI for endometrial cancer in early stages was done with final histopathology report. Diagnostic accuracy of MRI in detection of myometrial invasion and cervical stromal invasion in patients with early stage of endometrial carcinoma in our study was 87.5% (7 out of 8 cases were pathologically correlated) and was accurate in diagnosing staging of endometrial carcinoma and aiding in deciding the further plan of management.

The diagnostic accuracy of MRI in detection of appropriate staging cases of carcinoma cervix in our study was 85%, while the diagnostic accuracy of USG (TAS + TVS) in detection of appropriate staging of carcinoma cervix in our study was 50%. MRI was better predictor over FIGO staging in cases of carcinoma cervix with accuracy of 80% (16 out of 20 cases).

Total 20 patients with adnexal masses were studied. MRI was highly accurate for identifying

the origin of a mass and characterizing its tissue content. Diagnostic accuracy of MRI in our study was 95% and was superior to USG which had an accuracy of 60%. In our study, out of 9 malignant adnexal masses, MRI was able to diagnose malignancy in 8 cases with an accuracy of 88.8%. The important predictive features of malignancy were thick septations, mural nodules, pelvic adenopathy and ascites.

CONCLUSION

MRI is highly accurate in characterization and origin of uterine and adnexal masses, staging of known endometrial and cervical cancers, and differentiating benign from malignant lesions where other imaging modalities are inconclusive. Accurate staging of carcinoma cervix and endometrium is crucial to patient management and hence an accurate pretreatment staging is important.

REFERENCES

1. Hricak H, Chen M, Coakley F, et al. Complex adnexal masses: Detection and characterization with MR imaging-multivariate analysis. *Radiology*.2000; 214: 39-46.
2. Punwani S. Contrast enhanced MR imaging of female pelvic cancers: Established methods and emerging applications. *Eur J Radiol*.2011; 78: 2-11.
3. Eiko Murase, Evan S. Siegelman, Eric K. Outwater, et al., Uterine leiomyoma's: Histopathologic features, MR Imaging findings, Differential diagnosis and Treatment. *Radiographics*.1999; 19: 1179-197.
4. David Sutton. *Textbook of Radiology and Imaging*. 7th Edition. Elsevier Science Ltd. 2003.