



## Study of KETODEX; Combination of Dexmedetomidine and Ketamine in Upper Gastrointestinal Scopy in Adults: Observational Study

Authors

Dr Bindya Kour Bali, Dr Alpa Patel

### Abstract

**Background:** Aim of the study was to know clinical effects, safety and observe side effects of using the combination of dexmedetomidine and ketamine in upper gastrointestinal endoscopy in adults.

**Material and Methods:** A total of Sixty patients between the age group of (18 -60yrs) with American Society of Anesthesiologists class I, II or III undergoing UGIE were enrolled and an observational study was conducted over a period of 1 year. Dexmedetomidine (1.5 µg/kg) iv bolus was given slowly over 5min followed by ketamine (0.5 mg/kg) before starting the endoscopic procedure. Dexmedetomidine infusion was continued (0.5µgm/kg) and supplemental dose of ketamine was given if required .Heart rate, blood pressure and oxygen saturation, time to achieve Ramsay sedation score of 3-4 were recorded before induction, then every 5min untill recovery. The duration, ease of the procedure, time to recovery (Modified Aldrete Recovery Score) and complications if any were also recorded.

**Results:** UGIE could be performed with ease in 53 of the 60 cases (88.33%). No significant change in HR, Blood pressure, and Saturation (spo2) from the baseline values ( $p > 0.001$ ). None of the cases experienced respiratory depression. No active airway intervention was required. Recovery profile was good.

**Conclusion:** Combination of dexmdetomidine and ketamine in UGIE procedure promises to be clinically effective and safe with good recovery profile .

**Keywords:** Dexmedetomidine, Ketamine ,Ketodex, Upper Gastrointestinal Endoscopy.

### Introduction

The indications for endoscopy have increased enormously as it has matured from a purely diagnostic procedure to a therapeutic subspecialty .Endoscopic procedures are performed with patient under conscious sedation (moderate sedation, the patient, while maintaining ventilation and cardiovascular function, is able to make purposeful responses to verbal or tactile stimulation.<sup>2</sup>

The challenge to the anesthesiologist is to provide a deep level of sedation in order for the patient to tolerate the endoscope in the upper airway without

gagging as well as to maintain an un obstructed airway during the entire procedure. Dexmedetomidine, a short-acting selective alpha2-agonist, possesses anxiolytic, hypnotic, sedative, analgesic, sympatholytic properties, lacks respiratory depression and is hemodynamically stable and,<sup>1,4,7.</sup> Ketamine produces dissociative anesthesia (thalamo cortical junction), has analgesic, bronchodilatory and sympathostimulatory properties and maintains spontaneous ventilation<sup>1</sup>, So with the above concepts in mind the current study of Ketodex; a combination of Dexmedetomidine and Ketamine, was designed

which aimed to study the clinical effects, safety and complications of combination of dexmedetomidine and ketamine as a procedural sedation in upper gastrointestinal endoscopy in adults.

### Materials and Methods

The protocols used in this study were approved by Research and Ethical committee of Shree Krishna Hospital (SKH) Karamsad, Anand Gujrat ,India. An Observational study was conducted in patients undergoing upper gastrointestinal endoscopy for a period of 1 year. Sixty patients between the age group of 18-60 yrs with American Society of Anesthesiologists class I,II, and III who were undergoing upper gastrointestinal endoscopy were included in the study. Those subjects who were on beta blockers, having persistent sinus bradycardia (Heart rate less than 60 beats per min), history of allergy to any of the drugs used in study, Pregnant females, patient having any ophthalmic pathology, renal disease were excluded from the study.

All the patients underwent thorough pre-anesthetic evaluation prior to the UGIE A written and informed consent was taken. All the patients were kept nil by mouth (NBM) for 8 hours .Basic routine investigations were conducted On arrival in the recovery room after confirming NBM status baseline heart rate, blood pressure and oxygen saturation was recorded. An intravenous line was secured and appropriate fluid was started. Premedication was given Inj ranitidine 1mg/kg and .inj odensterone 0.8mg/kg Inj glycopyrolate 0.2mg and patient was shifted endoscopy room. With the patient position supine on the endoscopy table monitors were attached including ECG with pulse oxymeter and non invasive blood pressure. Oxygen was administered routinely through nasal prongs at 4l/min Dexmedetomidine (1.5 µg/kg) iv bolus was given slowly over 5min followed by ketamine (0.5 mg/kg) before starting the endoscopic procedure<sup>2,6</sup>.

Dexmedetomidine infusion was continued (0.5µgm/kg) and supplemental dose of Ketamine (0.5mg/kg were given if needed to maintain Ramsay Sedation Score of3- 4 during the

procedure). The following parameters were monitored and recorded before induction, then every 5min during the procedure and in the recovery room Heart rate, blood pressure and oxygen saturation values, time to achieve RSS of 3-4, FPS (facial pain score) .[Figure1] , 0-10 to evaluate pain and patient comfortability performed by anaesthesiologist at 5 min intervals throughout procedure and time to achieve Aldrete Recovery Score of 9-10.

During procedure, any of the following complications were observed, recorded and treated accordingly. Oxygen desaturation was considered when SpO2 level dropped below 92% for more than 10sec. A HR under 50 beats/min or a 20% decrease from the baseline was labeled as bradycardia, whereas a HR over 100 beats/min or an increase of more than 20% from the baseline level was considered as tachycardia. Blood pressure levels that were 20% less than the baseline and lower than 100/60 mmhg were regarded as hypotension. Vasopressors (inj mephentermine ) Inj Atropine and intubation equipments were kept checked and ready for any active intervention if required.

Statistical Analysis: Data was entered on excel sheet. Statistical analysis were performed using STAT 4 windows system. HR, MAP, and SpO2 were noted as the mean ± standard deviation and analyzed using two-way repeated measures analysis of variance. Comparisons were made to the baseline values, and a p<0.001 was considered to indicate significance. The assessment data of the endoscopist satisfaction , the recovery score, and adverse effects were recorded as percentages

### Results

Sixty patients of age group of 18-60yrs belonging to American Society of Anesthesiologists GradeI, II ,and III admitted to Shree Krishna Hospital (SKH) satisfying the inclusion and exclusion Criteria and undergoing UGIE after obtaining the ethical committee clearance were included in the study.

The endoscopists assessed the ease of procedure as satisfactory in 53 cases (88%) and as difficult in 7 cases where there was slight patient movement during the procedure. Additional ketamine (0.5 mg/kg) was required in these latter 7 cases [Table 1]. There were no significant changes in the hemodynamic parameters from the baseline. P VALUES >0.001(p valve <0.001 was considered significant). There was no statistically significant difference in the heart rate and oxygen saturation from baselineduring the procedure and recovery. (p value.>0.001) There was no significant change in the BP from the base line during the procedure and recovery. P value >0.001 which was clinically not significant. [Table 2 3,4] There were no major complications or side effects during the procedure and recovery of the patient's .Out of 60 patients only 7 had

some minor side effects which were managed accordingly [Table 2].

**Ramsay Sedation Score**

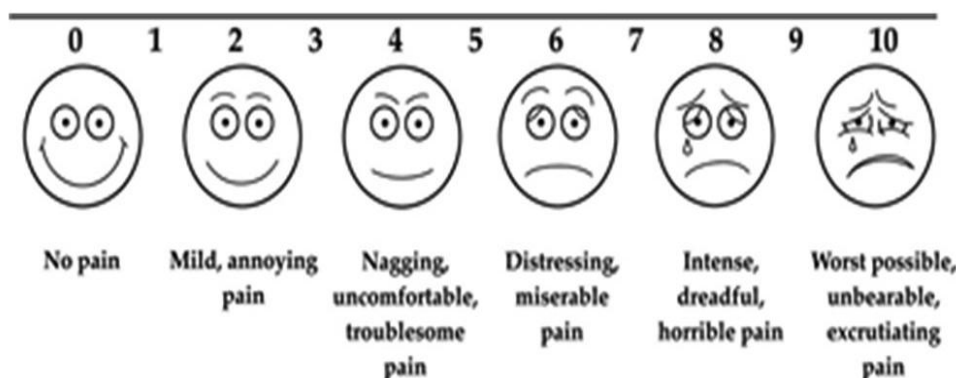
Out of 60 patients 59 achieved desired RSS of 3-4 in 5 min. Maximum and minimum time to achieve RSS OF 3-4 was

Mean time to achieve desired Ramsay Sedation Score (RSS) of 3-4 was 3.7±0.4 min. [Table 3]

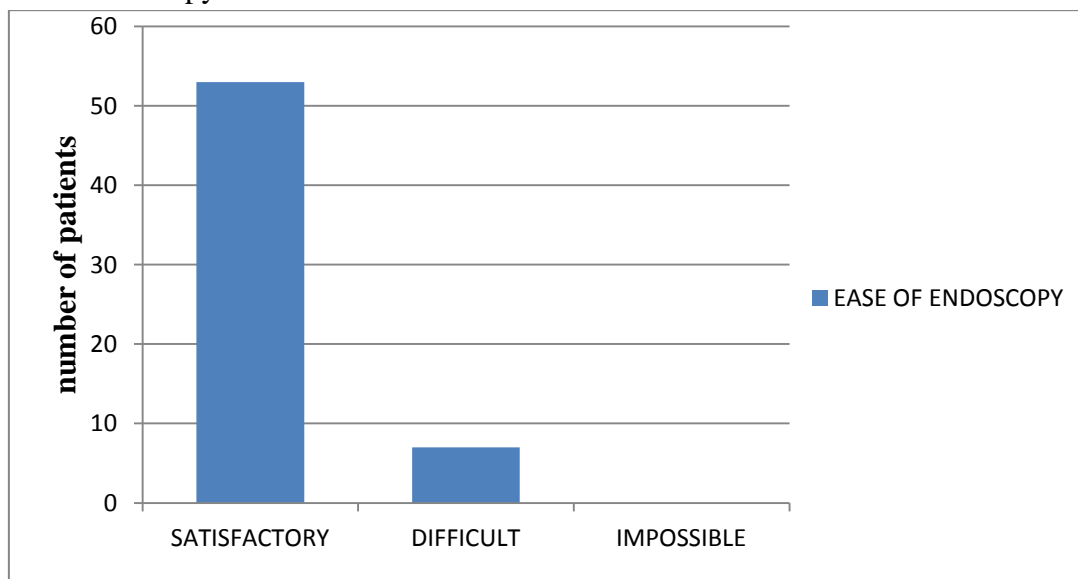
**Modified Aldrete Recovery score**

Out of 60 patient who had undergone Upper Gastrointestinal Endoscopy 52 attained ARS of 9 - 10 within five minutes of completion of procedure. Maximum and Minimum ARS attained within five min of completion of procedure was 10 and 8. Mean ARS attained in first five min was 9.18. [Table 4]

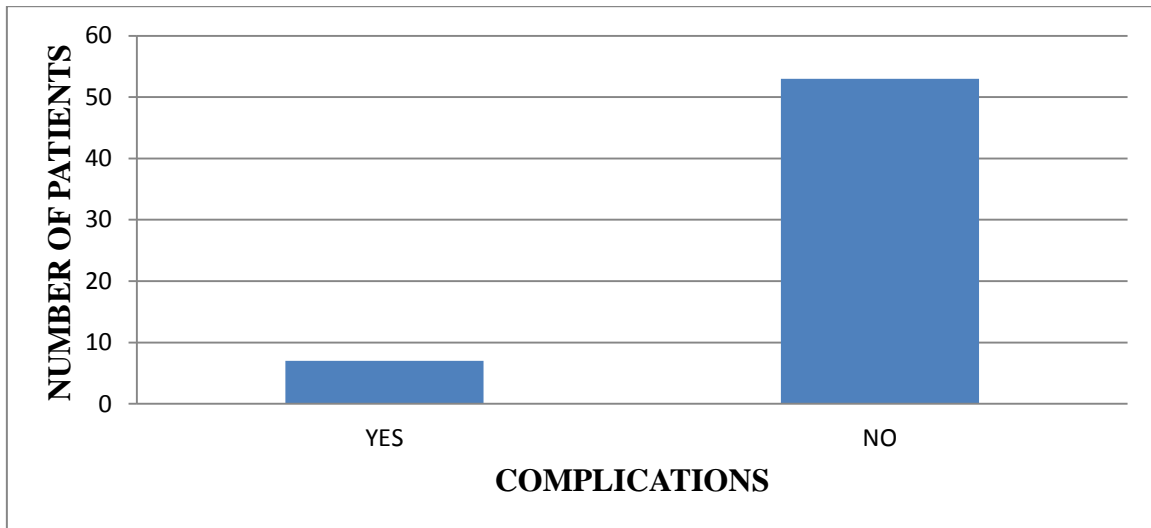
**Figure1.** Facial Pain Scale



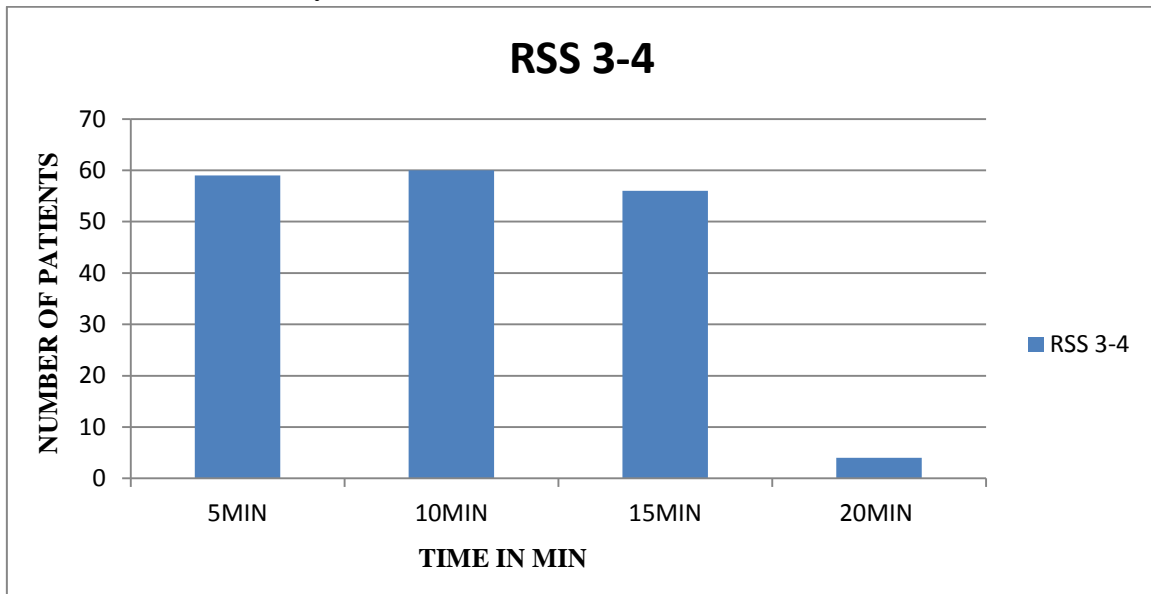
**Table1:** Ease of Endoscopy



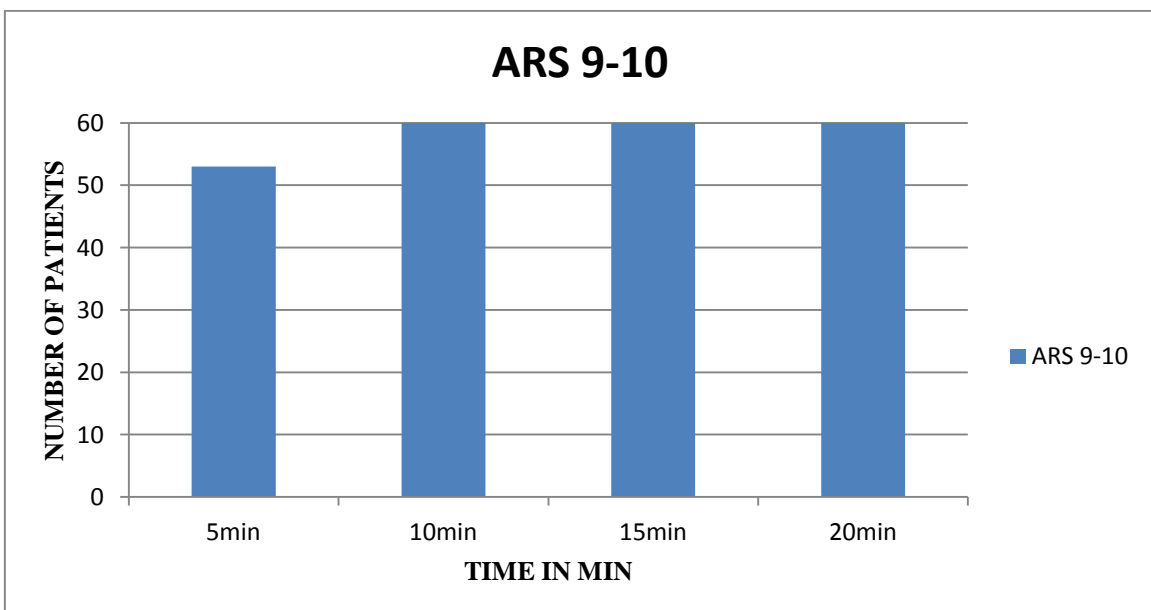
**Table 2 : Complications**



**Table 3 : Time to achieve Ramsay Sedation Score of 3-4**



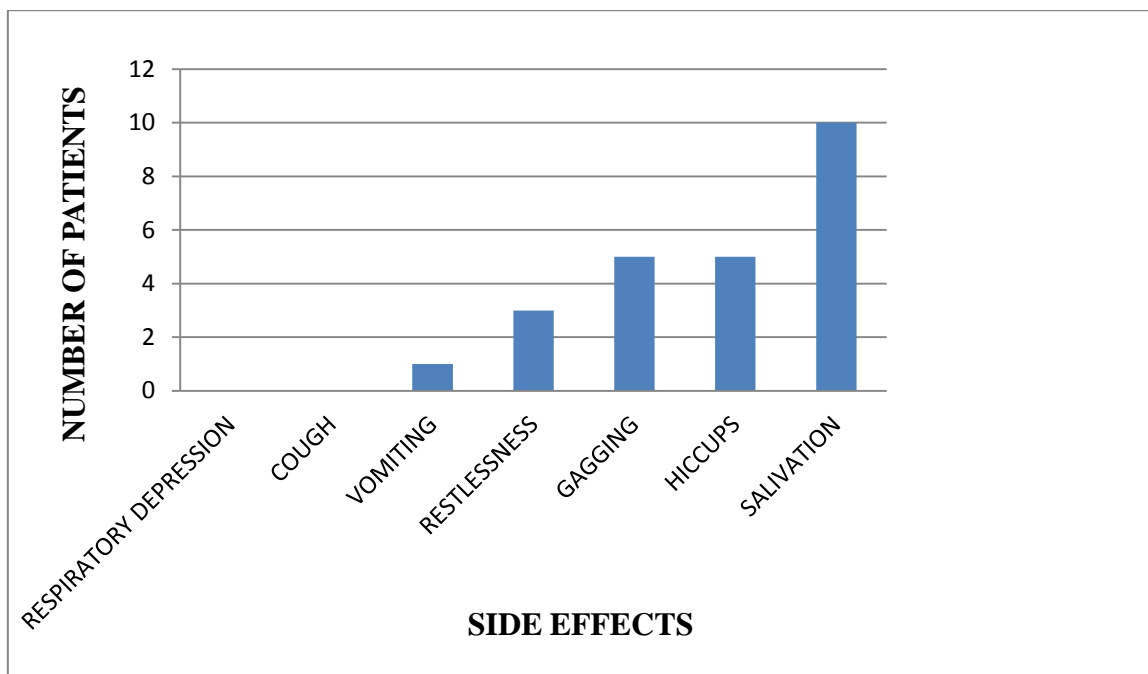
**Table 4: Time to achieve ARS 9-10**



**Table 5:** Hemodynamic Parameters

Parameters	Baseline	Hemodynamic				P value
		Time from beginning of procedure				
	5 min	10 min	15 min	20 min		
Heart rate (bpm)	90.8±5.5	87.7±5.4	86.7±5.4	88.0±5.4	90.8±5.4	>0.001
SBP (mmHg)	115.8±6.8	112.7±6.3	112.6± 6.7	116.4± 6.7	118.2± 6.3	>0.001
DBP (mmhg)	74.8 ±4.6	73.1± 4.3	73.6±4.0	75.3± 4.3	76.9±4.4	>0.001
Oxygen saturation (SpO2)	97.7 ± .54	99.8 ± .34	99.9 ± .12	100 ± .00	100 ± .0	>0.001

**Table 6:** Side Effects



**Discussion**

Upper gastrointestinal endoscopies are unpleasant common non invasive procedures (GIE), performed for diagnosis and management .On the one hand they require a deeper level of sedation, while on the other hand airway interventions are difficult during the procedure as this entails sharing of airway between the endoscopist and anesthetist. Ketodex, a combination of dexmedetomidine and ketamine, balances the sympatho-inhibitory effects of the former with the cardio-stimulatory effects of the latter, provides

adequate sedation and analgesia and maintains spontaneous ventilation while concomitantly attenuating the undesirable central nervous system effects of ketamine Our study showed no significant difference in Hemodynamic parameters from the baseline, level of sedation was adequate, no respiratory depression and endoscopy could be performed with ease in all the cases without any intervention. These results are in accordance with previous studies by Goyal, R., Singh, S., Shukla, R.N. et al. (2013)<sup>2</sup> conducted study of dexmedetomidine and ketamine for upper

gastrointestinal endoscopies (UGIE) 46 children aged 2–12 years over a 6-month period. The HR, MAP, and SpO<sub>2</sub> did not change significantly from the baseline. No airway intervention was required in any patient. There was no laryngospasm or shivering in any of the children and one, four, and 11 children had hiccup, vomiting, and increased salivation, respectively. The Pediatric Anesthesia Emergence Delirium score was 4 in all except for two cases. The results of this case series show that this drug combination not only promises to be clinically effective but also safe for UGIE in children. In another study conducted by Ashraf S. Hasanin, Ahmad M452013)<sup>9</sup> Dexmedetomidine versus propofol for sedation during gastrointestinal endoscopy in pediatric patients.. No significant differences were found in MAP, RR and SPO<sub>2</sub> values between groups at all time points. None of the patients in Dexmedetomidine group demonstrated oxygen desaturation versus 6 patients (15%) within propofol group (p-value 0.026).hence it was concluded that Dexmedetomidine sedation during GIE provides more respiratory safety and HR stability presenting itself as a suitable alternative agent especially for the relatively longer procedures In the study conducted by Hashiguchi, K., Matsunaga, et.al (2008)<sup>6</sup> he investigated the safety and efficacy of dexmedetomidine for sedation during upper gastrointestinal endoscopy. Forty middle-aged patients were randomized to receive an initial loading dose infusion of dexmedetomidine 6.0 µg/kg per h over 10 min followed by a maintenance infusion of 0.6 µg/kg per h (group A) or rapid infusion of midazolam 0.05 mg/kg (group B) as sedation for routine endoscopy. Sixty patients did not receive sedative agent (group C). Heart rate (HR), blood pressure (BP), oxygen saturation, and endoscopy duration were monitored. Hemodynamic stability was also demonstrated in group A during and after the endoscopic procedure.

In our study we gave Dexmedetomidine (1.5 µg/kg) iv bolus slowly over 5min followed by ketamine (0.5 mg/kg) before starting the

endoscopic procedure in 60 patients of ASA Grade I, II, and III between age group of 18 to 60 years, scheduled for Upper Gastrointestinal Endoscopy. There were no significant changes in the hemodynamic parameters from the baseline. P VALUES >0.001(p valve <0.001 was considered significant) None of the patients had Bradycardia, hypotension or desaturation .There was no respiratory depression in any of the patients in our study and there was no need of any active airway intervention [Table 5] .In our study the level of sedation was adequate, and endoscopy could be performed in all cases without any airway intervention Out of 60 patients in the study group endoscopy was performed with ease in 53 cases as assessed by surgeon 7 cases had some minor difficulty and required additional dose of ketamine. Retching was found to be significantly lower and endoscopists satisfaction was higher. Decreasing of retching reflex may be due to its sympatholytic and vagomimetic effects of dexmedetomidine .The findings of our study were similar to the study of Yavuz Demiraran, Esin Korkut and et al( 2005-2006)<sup>4</sup> who did a prospective randomised study to compare efficacy of dexmedetomidine versus midazolam used for sedation during upper endoscopy .Hemodynamic parameters were similar in both groups High satisfaction levels were seen in both groups The anxiety score after the procedure was lower in patients receiving dexmedetomidine than those receiving midazolam Endoscopist satisfaction on sedation of patients was significantly higher in the patients receiving dexmedetomidine than those receiving midazolam Hence it was concluded that ,Dexmedetomidine being safe and effective, seems to be a good alternative to midazolam for sedation of patients during upper endoscopy.

In our study 5 cases experienced gagging and hiccup, 10 cases has increased salivation which was managed by suctioning and positioning the patient in lateral position .No other active intervention was required One case had vomiting., during the procedure and required additional dose of ketamine. Gagging and hiccups subsided in 3



cases after additional dose of ketamine .In 2 cases rescue drug propofol 10mg iv was given to achieve RSS of 3-4 for conduction of UGIE with ease [Table 6]. Our finding were almost similar to study of Goyal, R., Singh, and et al (2013)<sup>2</sup> and Nam Kim, Young-Chul Yoo, and et.al in (2015)<sup>3</sup>

### Conclusion

From this study it can be inferred that use of KETODEX combination of dexmedetomidine and ketamine in UGIE procedures is safe with good recovery profile There is no significant variation in hemodynamic parameters from the baseline. Endoscopic procedure could be performed with ease in almost 90% cases .Both endoscopists and patients satisfaction score was excellent. Sedation and analgesia was adequate without any respiratory depression for smooth conduction of procedure and early recovery of the patient. There were no major side effects like hypotension, Bradycardia, gagging ,vomiting and Respiratory depression. However there is a need for further multicentric RCT to confirm the findings of our study. So that combination of dexmedetomidine and ketamine can become standard of care for conscious sedation in short invasive procedures

### References

1. Miller D Ronald, Miller's Anesthesia, 8th edition, 2015, Elsevier Inc Publications, USA); 30:845-58
2. Goyal R, Singh S, Shukla R.N ,Patra A.k ,Bhargav D.V Ketodex, combination of dexmedetomidine and ketamine for upper gastrointestinal endoscopy in children. Indian J Anesth( 2013)27:461-463
3. Kim N, Yoo YC, Lee SK, Kim H, Ju HM, Min KT Comparison of the efficacy and safety of sedation between dexmedetomidine-remifentanyl and propofol-remifentanyl during endoscopic submucosal dissection World J Gastroenterol. 2015 Mar 28;21(12):3671-8
4. Y Demiraran, E Korkut, A Tamer, et al. The comparison of dexmedetomidine and midazolam used for sedation of patients during upper endoscopy: A prospective, randomized study. Can J Gastroenterology 2007;21(1):25-29
5. Takimoto, K., Ueda, T., Shimamoto, F., Kojima, Y., Fujinaga, Y., Kashiwa, A., Yamauchi, H., Matsuyama, K., Toyonaga, T. and Yoshikawa, T. (2011), Sedation With Dexmedetomidine Hydrochloride During Endoscopic Submucosal Dissection Of Gastric Cancer. Digestive Endoscopy, 23: 176–181.
6. Hashiguchi K, Matsunaga H, Higuchi H, Miura S. Dexmedetomidine for sedation during upper gastrointestinal endoscopy. Dig Endosc. 2008;20:178–83.
7. Tobias JD Dexmedetomidine and ketamine: an effective alternative for procedural sedation? Pediatr Crit Care Med. 2012 Jul;13(4):423-7
8. Mester R, Easley RB, Brady KM, Chilson K, Tobias JD. Monitored anesthesia care with a combination of ketamine and dexmedetomidine during cardiac catheterization. Am J Ther 200 8;15:24-30
9. Ashraf S. Hasanina, Ahmad M. Sira Dexmedetomidine versus propofol for sedation during gastrointestinal endoscopy in pediatric patients 10.1016/j.egja. 2013.09.006
10. Desai PM, Umbarkar SR, Sarkar MS, Lohiya R. Conscious sedation using dexmedetomidine for percutaneous transcatheter closure of atrial septal defects: A single center experience. Ann Card Anesth 2016;19:463-7
11. Levänen JI, Mäkelä ML, Scheinin H Dexmedetomidine premedication attenuates ketamine-induced cardiostimulatory effects and post anesthetic delirium. Anesthesiology. 1995 May;82(5):1117-25.
12. Raman V, Yacob D, Tobias JD. Dexmedetomidine-ketamine sedation during upper gastrointestinal endoscopy and biopsy in a patient with Duchenne

- muscular dystrophy and egg allergy. Int J Crit Illn Inj Sci 2012;2:40-3
13. K. Sudheesh, S. Harsoor Dexmedetomidine in anesthesia practice: a wonder drug? Indian J Anesth, 55 (2011),
  14. Ralph Gertler H. Cleighton Brown, Donald H. Mitchell, and Erin N. Silvius, Dexmedetomidine: a novel sedative-analgesic agent Proc (Bayle Unit Med Cent). 2001 Jan; 14(1): 13–21PMCID: PMC1291306
  15. Stoeltings Pharmacology and Physiology in anesthetic Practice 5th edition Published by Wolters Kluwer 2015;5:186-95, 8:257-59,