



## A Prospective Study on Ocular Manifestations in Different Varieties of Spondyloarthropathies

Authors

**Dr Subhabrata Parida, Assoc Prof, Dr Gajal Pattnaik MS**

Department of Ophthalmology, SCB Medical College, Cuttack Odisha, India

Corresponding Author

**Dr Subhabrata Parida. MS**

Associate Professor, Department of Ophthalmology, SCB Medical College, Cuttack

Ph: +91-99370-41560, Email: [drkitusraban@gmail.com](mailto:drkitusraban@gmail.com)

### ABSTRACT

**Background:** Ocular inflammation is common in many rheumatologic diseases but with variable prevalence.

**Aim:** To clinically evaluate ocular manifestations of all patients diagnosed with Spondyloarthropathy attending the Regional Institute of Ophthalmology, S.C.B. Medical College & Hospital from September 2015 –October 2016

**Materials & Methods:** Patients for this study will be selected among Spondyloarthropathy, presenting to the Regional Institute of Ophthalmology, S.C.B. Medical College, Cuttack will be evaluated for any ocular manifestations.

**Results:** A total number of 207 spondyloarthropathy (SpA) patients were evaluated for ocular manifestations. The most common manifestation was found to be acute anterior uveitis (AAU) in almost all types of SpA with variable prevalence. In Ankylosing Spondilosis (AS) 53.70% had AAU, 28.70% had CAU (Chronic anterior uveitis), and 12.03% had dry eye features. In ReA (Reactive arthropathy) 37.50% had AAU, 16.66% had CAU (Chronic anterior uveitis), and 12.50% had dryeye features and 8.33% had Episcleritis. In Psoriatic arthropathy (PsA) 14.70% had AAU, 5.88% had CAU (Chronic anterior uveitis), and 8.82% had dryeye features and 17.64% had mild conjunctival congestion. In IBD associated arthropathy 15.38% had AAU, 7.69% had CAU (Chronic anterior uveitis), 7.69% had Episcleritis and 7.69% had posterior segment finding (CME, cystoid macular edema). In Undifferentiated SpA 14.28% had AAU, 7.14% had CAU (Chronic anterior uveitis), and 3.57% had dryeye features and 7.14% Episcleritis.

**Conclusion:** In our study we found around 37.68% of SpA had AAU, 19.32% had CAU, 9.66% had dry eye features, 5.31% had Episcleritis and 10.62% had Conjunctival congestion.

**Keywords-** Spondyloarthritis, acute anterior uveitis, Episcleritis.

### INTRODUCTION

Spondyloarthritis (SpA) comprises at least five diseases: ankylosing spondylitis (AS), psoriatic arthritis (PsA), reactive arthritis (ReA), arthritis of inflammatory bowel disease (AIBD), juvenile

spondylitis (jSpA) and undifferentiated spondyloarthritis (uSpA). These diseases all share a common clinical pattern and pathophysiological mechanisms. [1] They may present not only spinal and peripheral joint involvement but also a series of extra-articular manifestations such as uveitis,

enthesitis, skin lesions, apical lung fibrosis, valvular aortic incompetence and cardiac blocks.<sup>[2,3]</sup>It has been found that the most common extra-articular manifestation was ocular manifestations. We here document our study of different ocular manifestations in varieties of spondyloarthropathies .

**MATERIALS & METHODS**

Patients for this study will be selected among Spondyloarthropathy, presenting to the Regional Institute of Ophthalmology, S.C.B. Medical College, Cuttack will be evaluated for any ocular manifestations

**INCLUSION CRITERIA:**

All Patients diagnosed as Spondyloarthropathy (juvenile and adults) are considered for this study.

**EXCLUSION CRITERIA:**

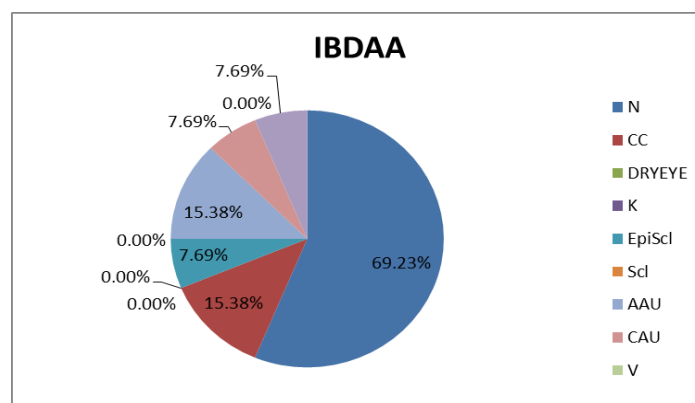
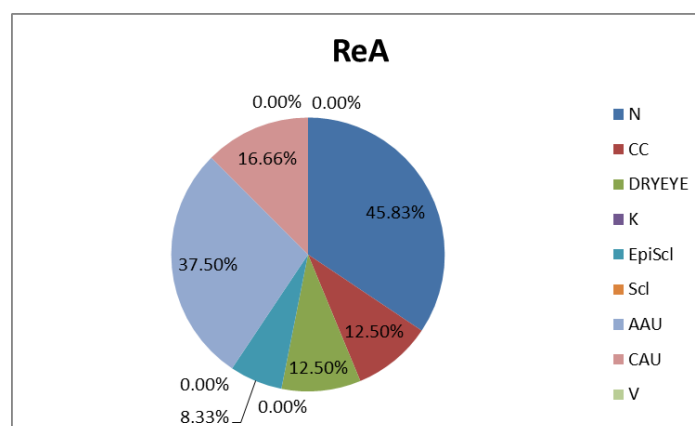
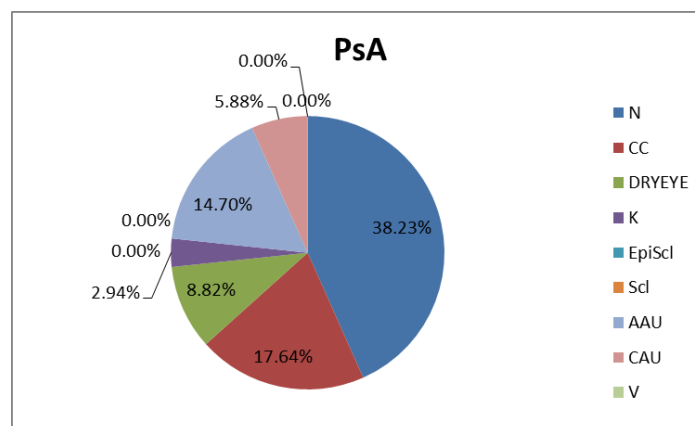
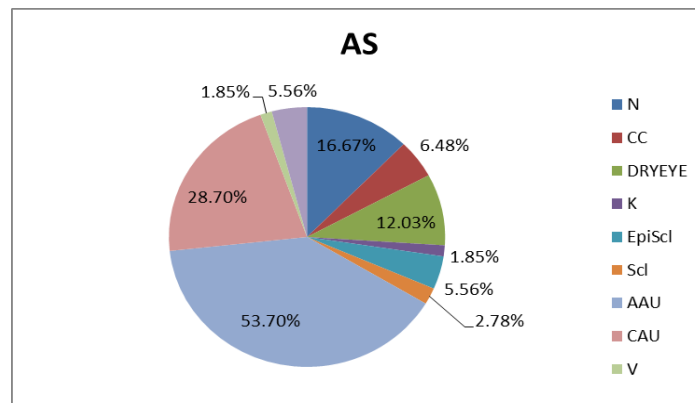
Following patients will be excluded from the study,

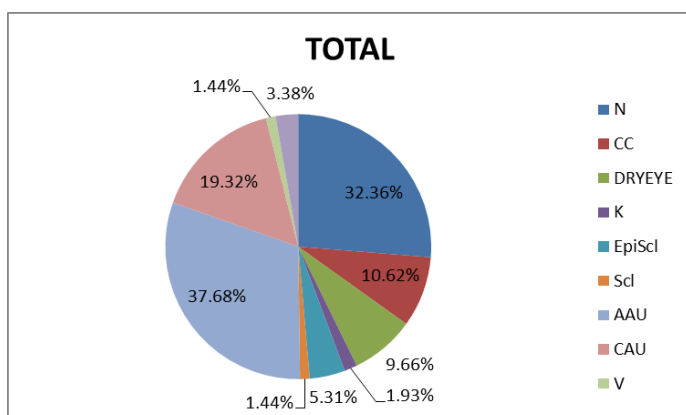
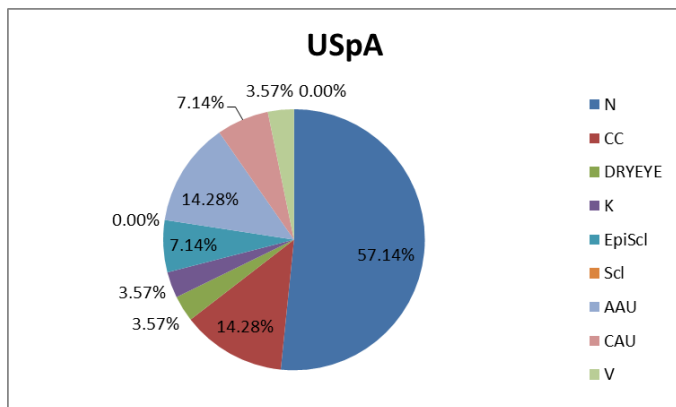
- Patients who will not give consent.
- Patients lost to follow up.
- Moribund Patients.
- In these patients detailed Ophthalmological investigations carried out-
- Visual acuity using Snellen’s Chart.
- Refraction and correction.
- Slit-lamp biomicroscopy.
- IOP measurement.
- Direct and indirect ophthalmoscopy.
- TBUT, Schirmer test and those diagnosed with dry eye are divided in mild, moderate and severe category according to Schirmer scores.
- OCT
- Perimetry
- FFA

(as and where required)

**RESULTS**

Ocular manifestations found in different types of SpA are being presented in following representation -





**DISCUSSION**

The most frequent extraarticular manifestation in spondyloarthropathies (SpA) is eye involvement, which is found in 30%-50% of patients.<sup>[4]</sup> Uveitis may occur in up to 37% of spondyloarthropathy patients.<sup>[5]</sup>

Many studies have been conducted to document the ocular findings in SpA patients.

Among the seronegative spondyloarthropathies, uveitis in ankylosing spondylitis is the most common ocular manifestation. It occurs in approximately 25 percent of patients with ankylosing spondylitis, in up to 37 percent of patients with Reiter’s syndrome, in approximately 20 percent of patients with psoriatic arthritis, and in up to 9 percent of patients with enteropathic arthritis.<sup>[6]</sup> A study done on a Brazilian population has shown prevalences of 14.5% for AS and 8.8% for uSpA. AS is considered to be the disease with the highest prevalence of AAU, and such manifestations are less common in ReA and PsA.<sup>[7]</sup>

In our study we found around 37.68% of SpA had AAU, 19.32% had CAU, 9.66% had dryeye

features, 5.31% had Episcleritis and 10.62% had Conjunctival congestion.

**CONCLUSION**

Ocular manifestation do affect a vast majority of spondyloarthropathy patients Around 34.29% of SpA were found to have some or the other forms of ocular manifestations, uveitis being the most common form. So I think my study will help appraise Spondyloarthropathy patients with different ocular manifestations as now-a-days ocular findings do form a diagnostic criterion for spondyloarthropathy. {the European Spondyloarthropathy Study Group (ESSG) criteria}. Hence, early detection of Ocular manifestations and better management of ocular complications helps for better prognosis of these patients.

**REFERENCES**

1. Acute Anterior Uveitis and Spondyloarthritis: More Than Meets the Eye CurrRheumatol Rep (2015)
2. Liao S, Pan YF, Huang JL, et al. An epidemiological survey of low back pain and axial spondyloarthritis in a Chinese Han population. Scand J Rheumatol. 2009;38(6):455-9.
3. Gran JT, Skomsvoll JF. The outcome of ankylosing spondylitis: a study of 100 patients. Br J Rheumatol. 1997;36(7):766-71.
4. Max R1, Lorenz HM, Mackensen F., Z Rheumatol. 2010 Jul;69(5):397-402. doi: 10.1007/s00393-009-0576-6
5. Journal of Ophthalmology Volume 2013, Article ID 928264
6. SAYJAL J. PATEL, LT, MC, USNR and DIANE C. LUNDY, CAPT, MC, USN Naval Medical Center, San Diego, California
7. Marcelo GehlenI, Kelly Cristina RegisII, Thelma Larocca SkareIII Rheumatology Service, Hospital Universitário Evangélico de Curitiba, Curitiba, Paraná, Brazil