



A Rare Case of Sudden Onset of Respiratory Distress Due to a Retrosternal Goiter Presenting to the Emergency Department

Authors

Jitesh Dhingra¹, Harmeet Rai Singh², Avi Kumar³, Mona Sharma⁴

¹GW Fellow, Emergency Medicine, Moolchand Hospital

²Program Director, Emergency Medicine, Moolchand Hospital

³Consultant, Pulmonary Medicine, Moolchand Hospital

⁴GW Fellow, Emergency Medicine, Moolchand Hospital

Corresponding Author

Dr Jitesh Dhingra

Moolchand Hospital

Email: jitesh.dhingra.ucms@gmail.com

ABSTRACT

Huge cervical and retrosternal goiters can cause acute respiratory compromise by leading to tracheal compression and airway compromise.

Substernal goiters may be asymptomatic or may present with symptoms caused by compression of adjacent organs. Acute respiratory failure is rare in cases of substernal goiter.

In cases of symptomatic substernal goiter the treatment is surgical by thyroidectomy. We present a rare case of a giant substernal nontoxic goiter which presented to the emergency department with acute respiratory insufficiency. The patient decided not to get the definitive treatment of thyroidectomy never the less it becomes an extremely important case to discuss to consider this as a probable differential diagnosis in the emergency department, a place where time is the essence of life.

Introduction

A thyroid mass that has descended in the plane of the thorax is labeled as retrosternal goiter. They may be completely asymptomatic but can present with complaints due to compression of the surrounding organs like trachea and esophagus. Nodular goiter can cause narrowing of the upper airway.

Upper airway obstruction due to an enlarged thyroid gland that needs prompt intervention is a rare condition. The incidence of BNG causing upper airway obstruction is not well defined, and

reportedly varies between 0.8 and 31% in different studies^[1]

An early diagnosis in the emergency department can not only be life saving but also can in some chronic cases give us an edge in treating the patient appropriately.

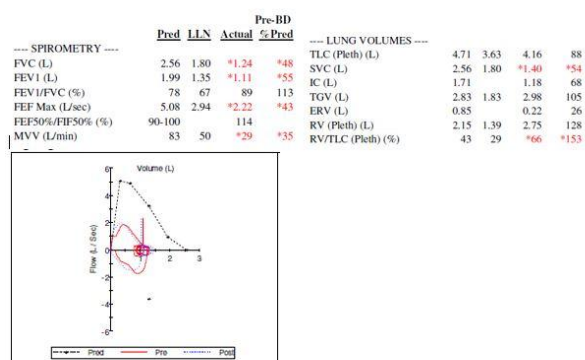
Case Report

A 61-year-old female came to our emergency department with complaints of shortness of breath for 1 day. She had been on medications for chronic obstructive lung disease empirically as

was diagnosed by her primary care physician very recently. She denied having regular or recent hospital visits. Her past medical history was significant for hypothyroidism for which she took thyroxine replacement but had stopped the medications 5 years ago. Clinical examination revealed a well nourished 70 kg female, temperature of 98.6 F, pulse was 102 /min, respiratory rate was 22/min and B.P. was 138/86, JVP was normal, there was no pedal edema. Auscultation of the chest revealed bilateral air entry was normal with no adventitious sounds. There was no cyanosis or dependent edema and there was no abnormality detected in other systemic examination.

Skiagram of chest was done which revealed a huge superior mediastinal mass shifting the trachea to the right. (Figure 1) A further examination of the thyroid thereafter revealed a huge mass extending retrosternally (confirmed by percussion). A CT of the chest revealed a left thyroid lobe displacing and narrowing the trachea.(Figure 2). . Arterial blood gas revealed a PaO2 of 68mmHg, PaCO2 of 30mm Hg, pH of 7.48, HCO3 of 32 and a normal anion gap and alveolar arterial gradient. Serum electrolytes were within normal limits.

FNAC confirmed the diagnosis of multinodular goiter. Patient was admitted to the wards and following morning her PFTs (Figure 3) were done which revealed:



This revealed a restrictive pattern or a pattern of fixed obstruction. The lung parenchyma was normal on the CT of the chest. A diagnosis of retrosternal goiter causing airflow limitation and

restrictive pattern was made. The patient was advised to get a thyroidectomy to release the compression of trachea and to cure the airflow limitation.

All other blood work including complete blood count, thyroid profile, sputum exam, cultures were within normal limits.

Patient was advised surgery but was not convinced. The PFTs have been within the range of the previous findings 6 months ago. This was a rare case of retrosternal goiter presenting to the emergency with symptoms of respiratory compromise.

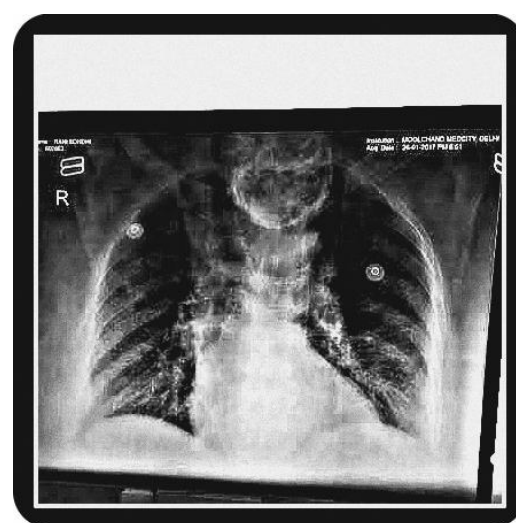


Figure 1 Superior mediastinal mass displacing the trachea to the right.

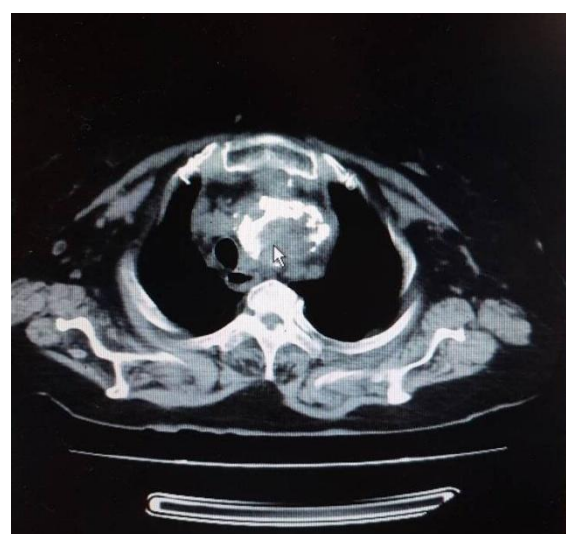


Figure 2 The CT scan on the right shows an enlarged left thyroid lobe displacing and narrowing the trachea behind the sternal notch. Lung Parenchyma was normal.

Discussion

Multinodular goiter is a rare cause of shortness of breath presenting to the emergency medicine department. This is very common during the fifth and sixth decades.

Though extremely rare retrosternal goiter can present to the emergency department with shortness of breath and difficulty in swallowing due to tracheal and esophageal compression.^{[2] [4]}

This happens only in long standing illness and in such cases this presents with a fixed airway obstruction pattern. Similar findings reported by Thusoo et al.^[3] support the idea that flow-volume loops provide an added advantage over conventional radiology alone in the detection of upper airway obstruction.

The narrowing of the upper airway due to tracheal compression can either be symptomatic (present with dyspnea) or asymptomatic. It is reported that up to 25–33% of patients with giant goiters have upper airway obstruction symptoms.^[3]

It is also reported that the symptoms are usually not due to the size of the gland, but rather to the compression of vital structures at the level of the bony thoracic inlet^[4].

As reported earlier dyspnoea occurs when more than 70% of the tracheal diameter decreases^[4].

Other causes are decompensated right-sided heart failure and pleural effusion. Venous compression can lead to superior vena cava syndrome^[4,8].

Exertional dyspnea is the most common manifestation of substernal goiter that represents 30-60% of the cases^[4]. This is a rare cause of sudden onset of shortness of breath but has to be considered with a significant history of hypothyroidism in the past.

Diagnosis is a challenge in the setting of emergency with no prior history of a goiter. The major points to focus on is the presence of a history of hypothyroidism in elderly and a recent complaint of shortness of breath with no similar complaints in the past.

The standard posterior-anterior and lateral chest X-rays are considered the single most valuable diagnostic tools with regard to the study of

substernal goiters extending into the thorax as these radiographs can provide valuable information about the compression of the trachea.

In emergent circumstances, however, a further assessment with US or CT is necessary given the severity of airway obstruction^[5]. This is however restricted to cases which present to us in respiratory failure or acute respiratory compromise.

The differential diagnosis for dyspnea is important. Keeping this as a probable differential diagnosis, Nandwani et al.^[6] report a case in which upper airway obstruction and dyspnea were confused with asthma. They used a flow-volume loop, as this test serves to aid in the diagnosis and monitoring of suspected airway obstruction.^[3] The presence of retrosternal goiter correlates with a fixed airway obstruction as was found in our patient.^[11]

Medical treatment is usually unsuccessful in such patients and surgical intervention is recommended. Surgery is the treatment of choice in patients with symptoms of compression onto adjacent structures such as the trachea, esophagus and the superior vena cava.^[7,9,10]

Asymptomatic patients with substernal goiter should also be considered for surgery to prevent complications^[7,9]. These patients may present with rapid deterioration and airway obstruction as a result of superimposed infection or haemorrhage into the mediastinal component of the retrosternal goiter. Our patient was asymptomatic and has been advised surgery as soon as possible to prevent this complication.

Definitive treatment for retrosternal goiter causing compression is thyroidectomy.^[12 13]

References

1. Miller MR, Pincock AC, Oates GD, Wilkinson R, Skene-Smith H. Upper airway obstruction due to goitre: detection, prevalence and results of surgical management. *Q J Med.* 1990;74:177–88
2. Ríos A, Rodríguez JM, Canteras M, Galindo PJ, Tebar FJ, Parrilla P: Surgical management of multinodular goiter with

- compressive symptoms. Arch Surg. 2005, 140: 49-53. 10.1001/archsurg.140.1.49.31
3. Thusoo TK, Gupta U, Kochhar K, Hira HS. Upper airway obstruction in patients with goiter studies by flow volume loops and effect of thyroidectomy. World J Surg. 2000;24:1570–2
 4. Banks C, Ayers C, Hornig J, Lentsch E, Day T, Nguyen S, et al. Thyroid disease and compressive symptoms. Laryngoscope. 2012;122:13-6
 5. Jennings A. Evaluation of substernal goiters using computed tomography and MR imaging. Endocrinol Metab Clin North Am. 2001;30:401-14, ix
 6. Nandwani N, Tidmarsh M, May AE. Retrosternal goitre: a cause of dyspnoea in pregnancy. Int J Obstet Anesth. 1998;7:46–9.
 7. MacK E. Management of patients with substernal goiters. Surg Clin North Am. 1995;75:377-94
 8. Tsang F, Wan I, Lee T, Ng S, Yim A. Management of retrosternal goitre with superior vena cava obstruction. Heart Lung Circ. 2007;16:312-4
 9. Rios A, Rodriguez J, Canteras M, Galindo P, Tebar F, Parrilla P. Surgical management of multinodular goiter with compression symptoms. Arch Surg. 2005;140: 49-53
 10. Anders H. Compression syndromes caused by substernal goitres. Postgrad Med J. 1998;74:327-9
 11. Gittoes NJL, Miller MR, Daykin J, Sheppard MC & Franklyn JA. Upper airways obstruction in 153 consecutive patients presenting with thyroid enlargement. BMJ 1996 312 484.
 12. Lang BH, Lo CY. Total thyroidectomy for multinodular goiter in the elderly. Am J Surg. 2005;190:418–23.
 13. Ríos A, Rodríguez JM, Galindo PJ, Canteras M, Parrilla P. Surgical treatment for multinodular goitres in geriatric patients. Langenbecks Arch Surg. 2005;390:236–42.