



Hiatal Hernia: A Rare Cause of Dyspnea Presenting to the Emergency Department

Authors

Jitesh Dhingra¹, Harmeet Singh Rai², Srikant Sharma³, Avi Kumar⁴

¹GW Fellow, Moolchand Hospital

²Program Director, MEM, Moolchand Hospital

³Consultant, Internal Medicine

¹Consultant, Pulmonary Medicine

ABSTRACT

Hiatal hernias mostly present at extremes of age groups in children and advanced age groups can rarely lead to pulmonary complaints like shortness of breath and pleuritic chest pain.

We are presenting a case that presented to the emergency department with sudden onset of shortness of breath in a young male presenting to the emergency department. This is a very rare presentation of diaphragmatic hernia and spontaneous diaphragmatic rupture.

INTRODUCTION

Hiatal hernia is abnormal protrusion of stomach above the diaphragm from the esophageal hiatus. Its clinical presentation may vary from usually asymptomatic to atypical symptoms like shortness of breath. Here we discuss a case of a 40 year old male coming to the emergency department with complaints of sudden onset of shortness of breath.

CASE REPORT

A 40-year-old man presented to the emergency department of a tertiary care hospital with increasing fatigue, shortness of breath over the last 3 days. He noted that shortness of breath aggravated with exertion and after the ingestion of food. The patient did not have any clinically significant history.

Clinical examination revealed a well nourished 80 kg male, temperature of 98.6 F, pulse was 102

/min, respiratory rate was 22/min and B.P. was 126/86, JVP was normal, there was no pedal edema.

Auscultation of the chest revealed bilateral air entry was normal with bowel sounds heard in the left side of chest. There was no cyanosis or dependent edema and there was no abnormality detected in other systemic examination. In the laboratory evaluations, the following results were obtained: WBC, 7400/mm³; Hgb, 12.9 g/dl, Plt, 376.000/mm³. Arterial blood gas revealed a PaO₂ of 86mmHg, PaCO₂ of 35mm Hg, pH of 7.45, HCO₃ of 32 and a normal anion gap and alveolar arterial gradient. Biochemical parameters were found to be within the normal range. Chest X Ray revealed an elevated left hemidiaphragm and a gastric air bubble in the left lung field. Figure 1

On the transthoracic echocardiography, it was found that the left ventricle systolic and diastolic

functions were normal, while the posterior wall of the left atrium was being compressed by a large mass.

A thoracoabdominal CT scan including axial and coronal sections was performed in the patient because of the suspicion of a large hiatal hernia with available image.

CT scan of chest (coronal section); showed herniation of stomach & splenic flexure of colon, along with collapse of lung and mediastinal shifting to the opposite side, can be seen. Figure 2 A pulmonary function test, which was done during the same period of time, showed forced expiratory volume in 1 second (FEV1)/forced vital capacity (FVC) 83% of predicted, FVC 62% and FEV1 64% of predicted, total lung capacity 58% of predicted, suggestive of restrictive pattern.

Emergency surgery was decided upon following consultation with the thoracic surgery department.

Figure 1

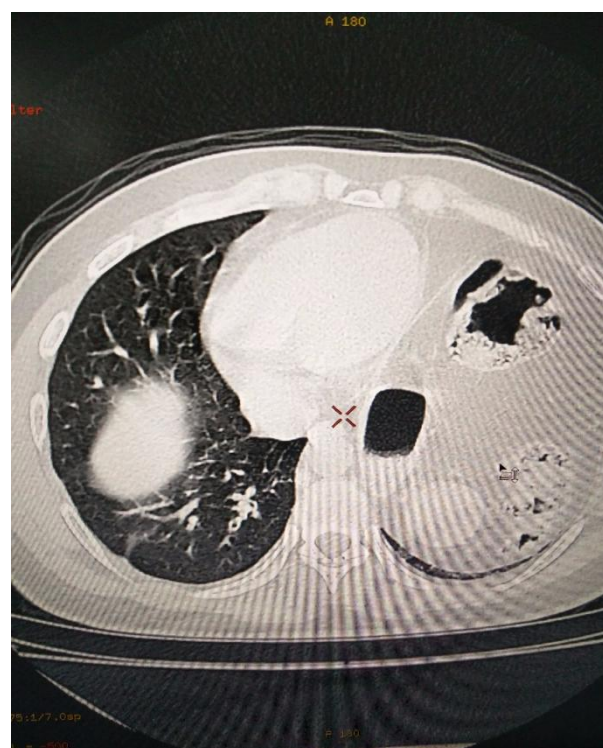
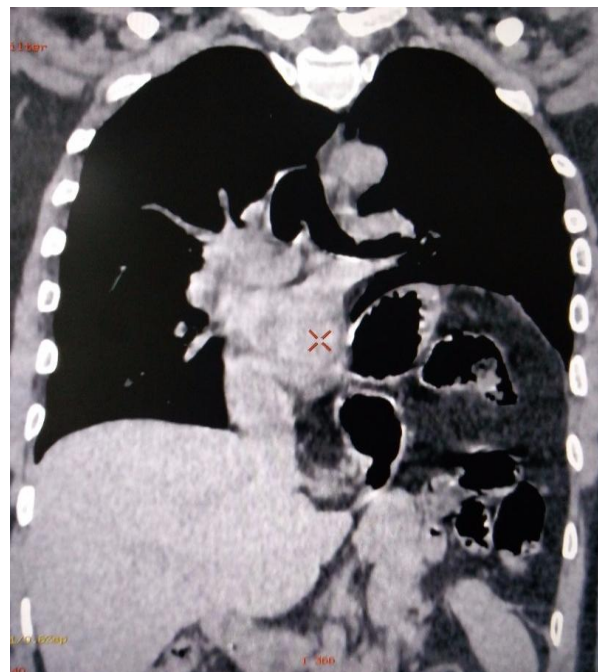
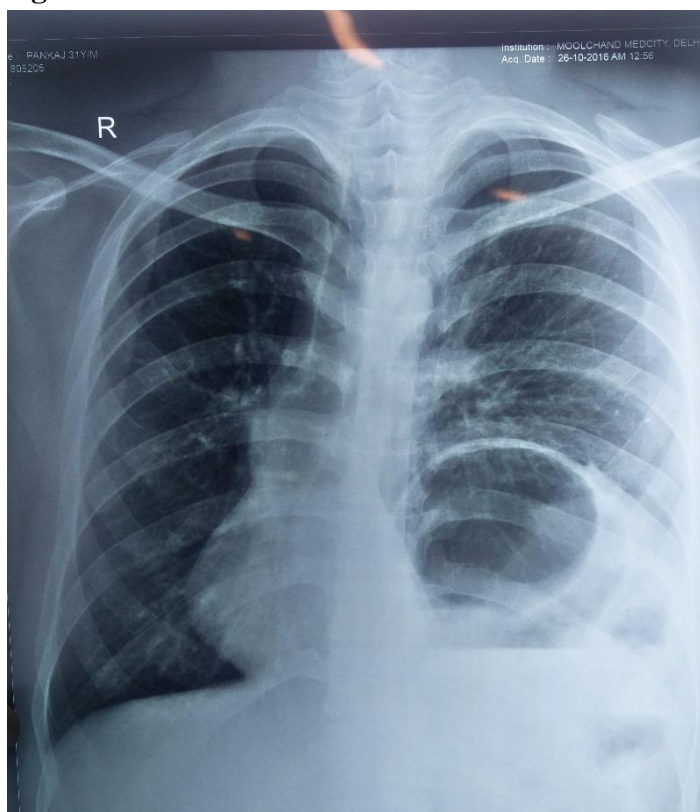


Figure 2 CT scan of chest (coronal section); herniation of stomach & splenic flexure of colon, along with collapse of lung and mediastinal shifting to the opposite side, can be seen.

DISCUSSION

The term hiatal hernia describes a condition where a part of the stomach that normally is located in the abdominal cavity pushes or protrudes through the esophageal hiatus to rest within the chest cavity.

HHs are mostly congenital in origin and are associated with various abnormalities in diaphragm development in pediatric patients and the cause of HH in adults is gradual enlargement of the hiatus, congenital defect and post-traumatic damage^[1,2]. There are four types of HHs: sliding HHs (type 1), paraesophageal hernias (PEHs; type 2), mixed hernias (type 3), and complex PEHs (type 4)^[1]. Mixed hernias involve combinations of sliding HHs and PEHs, and sliding and PEHs combined with other organic HHs are classified as type 4. Types 2, 3, and 4 are clinically classified as PEHs^[1,2].

The Type I hiatal hernia (sliding type) is the most commonly observed type in which gastroesophageal junction slides together with a part of the stomach^[2]. Although the cause for the development of hiatal hernia is unknown, its incidence increases by advancing age^[3].

An accepted theory is that relaxation at diaphragmatic crura is a result of aging process and is the cause for the observation of more frequent and larger hiatal hernias in elder population^[3].

Although large hiatal hernias are infrequent, they can lead to atypical symptoms such as chest pain and dyspnea and rare complications such as pulmonary edema and cardiac failure due to the extent of hernia and the compression to heart and pulmonary veins by organs protruded into thorax cavity. Siu et al. reported that a large hiatal hernia caused cardiac failure by the compression to the left atrium in a case presenting with recurrent acute cardiac failure attacks^[4]

In another case report, Chau et al. demonstrated a large hiatal hernia as the cause of chest pain in a patient that presented to emergency department with acute angina^[5]. Hiatal hernia can manifest as a left atrial mass on echocardiography. It can cause pulmonary edema and cardiac failure through the pulmonary venous obstruction.^[6]

There have been very few case reports of hiatal hernias with initial presenting complaints of shortness of breath.^[7,8,9] A history of such an event in the past should raise high suspicion in a patient coming to the emergency department.

Our patient had an atypical presentation with complaints of sudden onset of shortness of breath that developed over a period of 3 days.

Another point we want to illustrate in this case is that a diagnosis of diaphragmatic hernia can be made by physical examination as in our case with bowel sounds auscultated in the chest. Also we want to outline the use of a nasogastric tube in confirming the diagnosis of a diaphragmatic hernia.

The position of the nasogastric tube in the chest cavity will provide an important indicator and prompt correct diagnosis reference.

Giant hiatal hernia is responsible for 0.3–15% of all hiatal hernias.^[10] Generally, the common presentations of giant hiatal hernia include pain, heartburn, vomiting, dysphagia, and anemia.^[12]

Respiratory symptoms are considered a very uncommon clinical presentation.

In 2014, Chou and Su⁵ reported a case of an 86-year-old female who also presented with shortness of breath caused by giant hiatal hernia.^[9]

The major challenge is to diagnose Diaphragmatic hernia with spontaneous rupture especially in the absence of trauma. The diagnosis may be delayed by a few days or even several years as most of the symptoms are non-specific, especially with no trauma. The patient's history, symptoms, physical examination and CXR findings are very important in the diagnosis of DR and hernia. The presence of a thoracoabdominal trauma should be considered. In our patient, there was no history of minor or major thoracoabdominal trauma; the patient had atypical presentation of shortness of breath.

Diminution of breath sounds in the lower lobe of the left lung upon physical examination and bowel sounds heard in the left lung; and diaphragmatic elevation on the CXR were the most important findings implicating the diagnosis of diaphragmatic rupture.

Another point to be aware of is what are the stages of diaphragmatic rupture and how does it impact the treatment plan.

A literature review reveals that Rupture of the diaphragm has 3 phases according to the interval

The spontaneous diaphragm rupture has been divided into three phases in literature review: the initial or acute phase, the interval phase and the obstructive or late phase. These phases have been described in previous reports.

The acute phase, which continues for 2 weeks, clinical signs of DR may be obscured by the associated injuries^(13,14).

Classically reported symptoms, such as abdominal pain, shortness of breath, and chest pain, can often be overlooked. The interval phase may be relatively asymptomatic and DR may be discovered only by incidental radiography. Finally, during the phase of obstruction and strangulation, most patients have acute symptoms secondary to acute respiratory or bowel obstruction problems.

Also, patients most commonly have an acute abdomen secondary to incarceration and strangulation⁽¹⁴⁾.

In our patient, who had non-specific complaints such as stomach pain continuing for 3 days, nausea, vomiting, and persistent severe hiccups, DR was diagnosed in the acute phase.

The detection of diaphragmatic hernia with spontaneous diaphragmatic rupture is a big challenge in emergency medicine department and being aware of these phases can definitely be of significant importance.

CONCLUSION

In conclusion, large hiatal hernias should be considered in the differential diagnosis as a rare cause dyspnea presenting to the emergency medicine department. It should be kept in mind that large hiatal hernias can lead to cardiac symptoms and complications due to compression. This can be evaluated by complete and thorough physical examination and imaging modalities.

A very rare cause of shortness of breath, an atypical symptom of diaphragmatic rupture or hernia should be considered especially in the presence of suspicion on examination and radiographs.

REFERENCES

1. Kahrilas PJ, Kim HC. Kim, Pandolfino JE. Approaches to the diagnosis and grading of hiatal hernia; *Best Pract Res Clin Gastroenterol*; 2008; 22:601-61
2. Marchand P. The anatomy of esophageal hiatus of the diaphragm and the pathogenesis of hiatus herniation; *J Thorac Surg*; 1959; 37:81-92.
3. C.S. Winans Hiatus hernia. Its significance in the elderly patient *Geriatrics*, 27 (1972), pp. 69–78
4. C.-W. Siu, M.-H. Jim, H.-H. Ho et al., "Recurrent acute heart failure caused by sliding hiatus hernia," *Postgraduate Medical Journal*, vol. 81, no. 954, pp. 268–269, 2005
5. A. M. T. Chau, R. W.-L. Ma, and D. M. Gold, "Massive hiatus hernia presenting as acute chest pain," *Internal Medicine Journal*, vol. 41, no. 9, pp. 704–705, 2011
6. H. S. Lim, D. P. Leong, and M. Alasady, "Massive hiatus hernia mimicking a left atrial mass," *Heart, Lung and Circulation*, vol. 22, no. 10, pp. 875–876, 2011.
7. C.L. Alviar, J.P. Cordova, A. Korniyenko, F. Javed, M. Tsukayama, G. Narayanswami Bilateral Bochdalek hernias presenting as respiratory failure in an elderly patients *Respir Care*, 56 (2011), pp.691–69
8. D. Torres, G. Parrinello, M. Cardillo, M. Bellanca, G. Licata Hiatal herniation of the stomach and pancreas in a patient with oxygen desaturations
9. C.J. Chou, H.M. Sui An unusual cause of dyspnea: giant hiatal hernia followed by Takotsubo cardiomyopathy *Kaohsiung J Med Sci*, 30 (2014), pp. 484–485
10. Mitiek, R.S. Andrade Giant hiatal hernia *Ann Thorac Surg*, 89 (2010), pp. S2168–S2173
11. C. Naoum, G.L. Falk, A.C. Ng, T. Lu, L. Ridley, A.J. Ing, et al. Left atrial compression and the mechanism of exercise impairment in patients with a

- large hiatal hernia J Am Coll Cardiol, 58 (2011), pp. 1624–1634
12. Abbara S, Kalan MM, Lewicki AM. Intrathoracic stomach revisited. Am J Roentgenol. 2003;181:403–414.
 13. Akbar A, Parikh DH, Alton H, Clarke JR, Weller PH, Green SH. Spontaneous rupture of the diaphragm. Arch Dis Child 1999; 81: 341-2.
 14. Clarke DL, Greatorex B, Oosthuizen GV, Muckart DJ. The spectrum of diaphragmatic injury in a busy metropolitan surgical service. Injury 2009;40: 932-7.
 15. Athanassiadi K, Kalavrouziotis G, Athanassiou M, Vernikos P, Skekas G, Poultsidi A, et al. Blunt diaphragmatic rupture. Eur J Cardiothorac Surg 1999; 15: 469-74.