



## Clinical Study on Management of Multinodular Goitre

Authors

**Dr P.Sreenivas<sup>1</sup>, Dr Stalin Kampelly<sup>2</sup>, Dr Avinash Gottumukkala<sup>3</sup>**

<sup>1</sup>Associate Professor; Dept of General Surgery, MNR Medical College and Hospital, Sangareddy, Medak District, Telangana State, INDIA

<sup>2,3</sup>Postgraduate; Dept of General Surgery, MNR Medical College and Hospital, Sangareddy, Medak District, Telangana State, INDIA

### ABSTRACT

*Multi-nodular goiter is a commonly used term describing an enlarged thyroid gland with multiple areas of nodularity.*

*Worldwide, where MNG is the most common endocrine disorder, where iodine deficiency is often the culprit.*

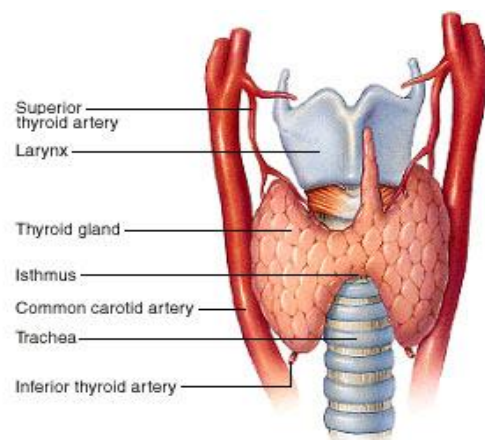
### INTRODUCTION

#### SURGICAL ANATOMY OF THYROID GLAND<sup>1,2,3,4,5</sup>

Thyroid gland averagely weighs 20-25 Gms. It is larger in females than in males and increases further during pregnancy and menstruation.

The thyroid gland has two lobes connected by isthmus. The lobes occupy the anterolateral surface of trachea extending from the middle of thyroid cartilage superiorly up to 6<sup>th</sup> tracheal ring inferiorly. The right lobe is larger than the left. The isthmus lies in the front of 2<sup>nd</sup> and 3<sup>rd</sup> tracheal rings and attached quite firmly to trachea.

Isthmus joins the anterior surface of lobes towards their lower poles. The posterior surface of isthmus is firmly adherent to the 2<sup>nd</sup> and 3<sup>rd</sup> tracheal rings. A small portion of the gland projects upward from the upper border of isthmus, named as pyramidal lobe.



**Figure 2:** Anatomy of the thyroid gland

### BLOOD SUPPLY

**(a) Superior thyroid artery:** It is the first branch from the anterior surface of the external carotid artery.

**(b) Inferior thyroid artery:** It is a branch of thyrocervical trunk which arises from the first part of the subclavian artery.

**(c) Thyroidea ima artery:** It enters the lower part of the isthmus in 3% of the individuals. It arises from the arch of aorta or innominate artery.

**VEINS**

The thyroid gland is drained by following veins

**(a) Superior thyroid vein:** It leaves the upper part of the gland, crosses the common carotid artery and terminates into the internal jugular vein or common facial vein.

**(b) Middle thyroid vein:** It leaves the gland at the middle of the lateral part of the lobe.,

**(c) Inferior thyroid vein:** It leaves the Isthmus at the inferior border and runs down in front of the trachea to end in innominate vein of the same side.

**(d) Fourth thyroid vein:** KOCHER drew attention to the frequent existence of this vein which passes outward between middle and inferior thyroid vein.

**NERVES RELATED TO THE GLAND<sup>1</sup>**

The external laryngeal nerve and the recurrent laryngeal nerve are in close relationship with the gland.

**(a) External laryngeal nerve:** It is a branch of superior laryngeal nerve, descends on the fascia of the inferior pharyngeal constrictor to supply the cricothyroid muscle which is tensor of vocal cords.

**(b) Recurrent laryngeal nerve:** The nerve is branch of vagus nerve. The nerve lies in the tracheo-oesophageal groove and posterior to the inferior thyroid artery. Injury to this nerve results in partial (abductor) or total paralysis of the cord resulting in hoarseness and respiratory difficulty.

**(c) Internal laryngeal nerve:** It is the branch of the superior laryngeal nerve and penetrates the larynx through thyrohyoid membrane.

**CAPSULES**

The thyroid gland is surrounded by two capsules, the true capsule and a false capsule. The true capsule is made up of condensation of connective tissues around the gland while the false capsule is formed by pre-tracheal fascia.

**SUSPENSORY LIGAMENT OF BERRY**

This is the thickening of pre-tracheo fascial investment of thyroid. It passes from inner and posterior surface of the gland to cricoid cartilage. The two ligaments left and right form a sling, anchoring the gland to the larynx.

**LYMPHATICS OF THYROID**

- Extensive, multidirectional flow
- periglandular → prelaryngeal (Delphian) → pretracheal → paratracheal (along RLN) → brachiocephalic (sup mediastinum) → deep cervical → thoracic duct

The median lymph node near the isthmus is often involved in thyroid cancer, which is called *Delphian* node.

**NERVE SUPPLY OF THE GLAND**

The bulk of the sympathetic supply is derived from the middle cervical ganglion and enters the gland on the inferior thyroid artery. Some fibers from the superior ganglions travel with the superior thyroid artery. The sympathetic fibers are vaso-constrictor. Vagus nerve also supplies the gland. Its purpose is unknown.

**AETIOLOGY OF MULTINODULAR GOITRE<sup>6</sup>**

The causes leading to deficiency of thyroid hormone synthesis are

**A) Iodine deficiency**

**B) Goitrogens**

**Chemical goitrogens**

1. The thiocyanate and isothiocyanate
2. Phenol derivatives
3. Excess iodide

**Drugs that act as goitrogen**

Lithium, Para-amino salicylic acid (PAS), Phenendione, Phenyl butazone and Salfonamides.

**C) Genetic defects: Familal goitres**

**D) Immunological Factors:**

**E) Calcium and Fluorine**

**F) Associated with malignancy**

## COMPLICATIONS OF MNG

The complications of MNG are as follows:

### 1. Secondary thyrotoxicosis<sup>7</sup>

Its incidence is difficult to estimate but figures as high as 30% are reported.<sup>6</sup> mainly due to activity of IgG immunoglobulins against TSH Receptors. However in some toxic nodular goitre one or more nodules are overactive and here the hyperthyroidism is due to autonomous thyroid tissue as in toxic adenoma and is termed as plummer's disease.

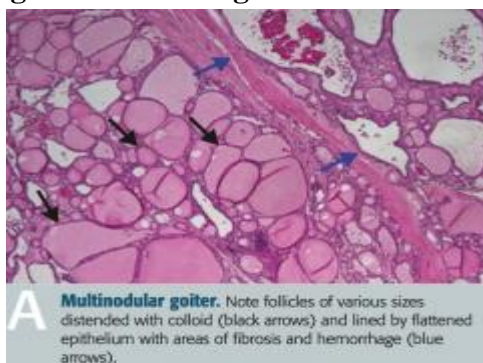### 2. Tracheal compression

It may be due to gross displacement of trachea in lateral or anteroposterior plane. It is commonly due to haemorrhage into a nodule and in retrosternal goitre.

### 3. Malignant change<sup>8,9</sup>

It is one of the most controversial subject which is still not settled. It is an uncommon complication. The incidence of carcinoma in MNG has been reported as 5-10%.<sup>2</sup>. The malignancy is usually of follicular type.

## Cytological and histological features of MNG<sup>10</sup>



Microscopically there will be normal to hyperplastic foci of thyroid tissue, large areas of colloid, hemorrhage, fibrosis and calcification, variable amounts of lymphocytic infiltration can be seen.

## TREATMENT OF MULTINODULAR GOITRE

Toxic and nontoxic MNG should be addressed separately,. Treatments include non surgical and surgical approaches

In general, surgery is necessary in extremely large MNG for cosmetic appearance, suspicion of malignancy, tracheal or esophageal symptomatology, substernal extension, vocal cord paralysis and rapid growth otherwise consideration should be given to medical or radioiodine treatment.

## Medical treatment of MNG<sup>11,12,13</sup>

The treatment of nodular goitre by TSH suppressing dose of T<sub>4</sub> is controversial. T<sub>4</sub> medication is useful in diffuse goitres. Thus hormonal suppressive treatment cannot be accepted as a reasonable long term treatment in euthyroid Multinodular goitres but is used in preparing a patient with toxic nodular goitre, to bring to euthyroid level before surgery. Long term treatment of MNG with anti-thyroid drugs is not appropriate as relapse is invariable after withdrawal of the drug in 95% of patients.<sup>13</sup>

## Role of radioiodine in MNG<sup>14,15,16</sup>

This is used to treat toxic and nontoxic MNG. This treatment modality has been shown to reduce the size of nontoxic and toxic MNG by approximately 40% to 60% in 2 years

It is useful in patients with recurrent goitres or elderly patients. In toxic nodular goitre, <sup>131</sup>I ablation may be used in patients who are not suitable for surgery but because of high failure rate with this treatment, thyroidectomy is considered treatment of choice.

In non-toxic MNG, treatment with RAI has resulted in improvement in the compressive symptoms in large goiters.

Comparing subtotal thyroidectomy with RAI for nontoxic MNG, the response to surgery was better at 1 year than with RAI.

This treatment should be considered in individuals who are unable to tolerate surgical treatment.

## Role of Surgery in MNG

Nodular goitre is an irreversible stage. Hence surgery is the preferred treatment of choice in young patients, those with large goiters for cosmetic reasons or large autonomous adenomas

(which would necessitate a very large dose of radio iodine) and whenever there is suspicion of malignancy.

The nodular goitre may be toxic or nontoxic.

The toxicity in nodular goitre may be due to two reasons.

Ist-- the internodular tissue is active but the nodules are inactive. Here the toxicity is due to IgG immunoglobulins, which bind with TSH receptors site on follicular cell membrane.

IInd---, the nodules themselves are active and the over activity of one or more nodules which are autonomous, suppress the internodular tissue. Both forms can be detected by radioiodine uptake study.

Although the surgical technique is the same for both nontoxic and toxic MNG, the preoperative evaluation and management may differ because of the course of each disease. Toxic MNG is commonly treated surgically with subtotal or total thyroidectomy.

### **Surgery for simple MNG**

Most patients of MNG are asymptomatic and do not require operation. Operation may be indicated on cosmetic grounds,. Retrosternal goitre with actual or incipient tracheal obstruction is an indication of operation, as in the presence of a dominant area of enlargement, which may be neoplastic.

### **There is a choice of surgical treatment**

- a) Total thyroidectomy with immediate and lifelong replacement of thyroxine.
- b) Partial Thyroidectomy. In Partial resection aims to remove bulk of the gland leaving upto 8 grams of relatively normal thyroid tissue in each remnant i.e., subtotal thyroidectomy.

### **Surgery for toxic MNG<sup>16</sup>**

In toxic MNG with autonomous toxic nodules, surgery cures by removing all of the overactive nodules. This allows suppressed normal thyroid tissue to function again.

Now a days there is an increasing trend towards total thyroidectomy, which simplifies subsequent management and rapidly achieves a permanent euthyroid state on thyroid replacement therapy

### **Treatment of retrosternal goitre (RSG)**

Resection of retrosternal goitre can almost always be performed from the neck and a midline sternotomy is hardly even necessary.

Sternotomy is required for large intrathoracic goitre where the thoracic inlet may be too small for delivery of the gland, for tumour with significant invasion and when uncontrolled bleeding is encountered.

In the nontoxic MNG, surgery is performed mainly to prevent pressure effect for cosmetic purpose and whenever there is suspicion of malignancy. Although prophylactic surgery to prevent the occurrence of carcinoma is not justified in Multinodular goitre, 4% to 17% of glands removed contain malignant foci. Surgery done is mainly subtotal thyroidectomy.

In toxic Multinodular goitre, surgery is the choice of treatment.

After subtotal resection it has been customary to give thyroxine to suppress TSH secretion with the aim of preventing recurrence. Whether this is necessary or effective is uncertain, although the evidence of benefit in endemic areas is better than elsewhere.

### **Minimally invasive surgery in thyroid**

Japanese are now using the more advanced trans auxiliary armpit approach for similar surgeries, and it would not be long before such advanced techniques are tried in India too. Considering that a large number of goiter cases needing surgery occur in young and middle-aged women, there will be possibly a major role for endoscopic surgery in the modern management of the disease.

### **POSTOPERATIVE COMPLICATIONS<sup>17,18</sup>**

- Haemorrhage
- Respiratory obstruction
- Postoperative thyroid crisis

- Parathyroid insufficiency
- Recurrent laryngeal nerve paralysis
- Hypothyroidism
- Recurrent thyrotoxicosis

**Other complications**

- Wound infection
- Hypertrophic or Keloid Scar & Stitch granuloma.

**OBJECTIVES**

1. To know the clinical pattern and presentation of patients with MNG.
2. To know the principles and management of MNG
3. To Review the mode of treatment adopted.

**MATERIAL AND METHODS**

**Study Design:** Prospective study.

**Place of study:** MNR hospital, SANGAREDDY.

**Period of study:** A period of two years from November 2014 to June 2016

**Sample size:** Total of 100 cases were enrolled in the study among which 86 were females and 14 were males.

**INCLUSION CRITERIA**

- Patients with clinically evident multi nodular goiter

**EXCLUSION CRITERIA**

- Thyroid Malignancies

**RESULTS**

**Table 1:** Age and Sex Incidence

Age in yrs	Male	Female	Total	%
01-10	0	0	0	0
11-20	0	4	4	4
21-30	2	28	30	30
31-40	2	28	30	30
41-50	4	18	22	22
51&above	6	8	14	14
Total	14	86	100	100

Most commonly affected age group is 21-40 yrs (60% cases).

Total number of male patients is 14(14%) and Total female patients is 86 (86%)

Ratio of Female to Male patients is 6:1

**Table 2** Duration of swelling

Duration of Swelling	Total No. Cases	%
1-6 months	42	42%
12months	20	20%
2 years	12	12%
5 years	16	16%
10 years	04	04%
>10 years	06	06%
Total	100	100%

Most common pressure symptom was difficulty in swallowing, followed by difficulty in breathing. There were 4 cases of retrosternal goiter, which were substernal type. Swelling was moving with deglutition in all 100 cases.

**Table 3** FNAC findings of Thyroid

Report of FNAC	Total No. of Cases	%
Colloid Goitre	78	78%
Hashimoto's Thyroiditis	14	14%
Follicular Neoplasm	08	8%
Malignancy	0	0
Inconclusive	0	0
Total	100	100%

FNAC Findings of study shows majority (78%) cases are of colloid goiter type and 14% are of hasimotos thyroiditis type

**Table 4** Histopathology (HPE) of Thyroidectomy Specimen

HPE REPORT	Total No.of Cases	%
Colloid Goitre	78	78%
Hashimoto's thyroiditis	6	6%
Follicular Adenoma	6	6%
Follicular Carcinoma	0	0
Papillary Carcinoma	6	6%
Medullary Carcinoma	4	4%
Total	100	100%

Histopathology of thyroidectomy specimen showing benign colloid goiter in 78% cases and 10% cases showing Malignancy features

**Table 5** Complications of Surgery

Complications	Total No. of Cases	%
Reactionary Hemorrhage	0	0
Transient Hypothyroidism	8	8%
Permanent Hypothyroidism	0	0
Temporary RLN Palsy	5	5%
Permanent RLN Palsy	0	0
Wound Infection	4	4%
Total	18	18%

Complications in Surgical treatment of MNGs are rare accounting for 18% of cases of which transient Hypothyroidism accounts for 8% cases

### CONCLUSIONS

- MNG is the commonest benign thyroid disease
- Multinodular goiter is more common in females (Female to male ratio 6:1)
- Majority are in the age group of 21-40 years (56%).
- Secondary thyrotoxicosis is seen in 34% (34 cases).
- FNAC is very useful in the diagnosis and management of MNG.
- Malignancy can still be seen in post-operative histopathological examination, even when there is no suspicion of malignancy clinically and with FNAC.
- The main indications of surgery in MNG are cosmetic problem, pressure effect symptoms, secondary thyrotoxicosis and suspicion of malignancy.
- Subtotal thyroidectomy is the surgery of choice for MNG.

### SUMMARY

Surgical treatment is the mainstay for treatment of multi nodular goitre but alternative treatment of Harmonal therapy can also be used for toxic MNGs to bring back to Euthyroid state, and Radioiodine therapy can also be used used in MNG to reduce the size of Goitre

### BIBLIOGRAPHY

1. GAG Decker, DJ du Plessis; "The Thyroid, Thymus and Parathyroid Glands" chapter 17, Lee McGregor's Synopsis of Surgical Anatomy, 12<sup>th</sup> Edition 1999, pp198-205.
2. Mary Dyson, "Endocrine System – Thyroid Gland", chapter 15, Gray's Anatomy, 13<sup>th</sup> Edition, 2000 pg 1891-1897.
3. Sinnathambi Chummy S. "Head, Neck and Spine" chapter 6, Last's Anatomy, 10<sup>th</sup> Edition 2000, pp 330- 332.
4. Ellis Herald. The Head and Neck, Parts of Clinical Anatomy; 9<sup>th</sup> edition, Blackwell Science, UK 1997; pp 284-287
5. Williams A.C et al. Thyroid cancer in 1330 cases of sporadic goitre. *Am J Surg*, 1962; 104: 672-676.
6. Wheeler , M. H. and Lazarus, J. H., Diseases of the Thyroid, Pathophysiology and Management , Chapman and Hall, London 1994
7. Sturniolo Givvanni et al. The recurrent laryngeal nerve related to thyroid surgery. *Am J Surg*, June 1999; 177: 485-488.
8. Sokal JE, The problem of malignancy in nodular goitre, *JAMA*, 1959; 170: pp 405.
9. Sokal JE, Incidence of malignancy in toxic and nontoxic nodular goitre. *JAMA*, 1954; 154: 1321-1325
10. Cottron Ramzi S. et al, The Endocrine System Thyroid Gland; chapter 25; Robin's Pathological Basis of Disease, 6<sup>th</sup> edition, 2005 pp 1121-1142
11. Hasleh Christopher et al. Endocrine Disease, Chapter 8, Davidson's Principles and Practice of Medicine, 18<sup>th</sup> edition, Harcourt Publishers Ltd, UK 1999; pp 559-575
12. Gharib H, Mazzaferri EL, Thyroxine Suppressive Therapy in Patients with Nodular Thyroid Disease. *Ann Intern Med* 1998; vol 128: pp 386-94
13. Papini E, Bacci V, Panunzi C et al, A prospective Randomized Trial of Levothyroxine Suppressive Therapy for Nodular Thyroid. *Clin Endocrinol* 1993; vol 38: 507
14. Farwell Alan P., Braverman Lewis C. Thyroid and Anti-thyroid drugs, Chapter 56, Goodman Gillman's 9<sup>th</sup> edition, Hardman Joel G, Limbird Lee E. Mc Graw Hill, New York, USA 1996, pp 1383-1410.

15. Laszlo H, The Nodular thyroid, New Engl J Med 2004; vol 351: pp 1764-1771
16. Jerry A. Day, Angela Chu and Khanh Geinhuang. Disorders of Thyroid. The larynologic Clin NA, America, WB Saunders Company Vol. 36, PP 50.
17. Fewins J, Simpson CB, Miller FR: Complications of thyroid and parathyroid surgery. Otolaryngol Clin North Am 2003; vol36 : 189
18. Wheeler Malcolm. Thyroid Surgery and recurrent laryngeal nerve Cardiff *BJS* 1999, 291-292