



## Posner Schlossman Syndrome

Authors

**Lt Col Rishi Sharma<sup>1\*</sup>, Lt Col AlokSati<sup>2</sup>, Col Sandeep Shankar<sup>3</sup>, Brig V.S Gurunadh<sup>4</sup>**

<sup>1\*</sup>M.S Ophthalmology, Graded Specialist, Military Hospital Shimla-171008, India

<sup>2</sup>Cornea and Anterior Segment surgeon, M.S Ophthalmology, Associate Professor, Department of Ophthalmology, Armed Forces Medical College, Pune-411040, India

<sup>3</sup>Vitreo-retinal Surgeon, M.S Ophthalmology, Associate Professor, Department of Ophthalmology, Armed Forces Medical College, Pune-411040, India

<sup>4</sup>Vitreo-retinal Surgeon, M.S Ophthalmology, Commandant, Military Hospital Wellington, India

Corresponding Author

**Lt Col (Dr.) Rishi Sharma, M.S Ophthalmology**

Graded Specialist, Military Hospital Shimla-171008, Himachal Pradesh, India

Mobile no -9882829560

Email: [rishi4840@yahoo.co.in](mailto:rishi4840@yahoo.co.in), [rs19april81@gmail.com](mailto:rs19april81@gmail.com)

### Abstract

32 years old male patient presented with four day history of mild redness, pain and blurring of vision of the left eye. He gave history of similar episode 4-5 months back and it subsided with treatment. Visual acuity on presentation was 6/6 RE and 5/60 → 6/12 with -1.5DSph/ -2.75 D Cyl at 110°. (Left Eye). Anterior segment was normal in the right eye. In the left eye fine Keratic Precipitates on cornea and trace Ant Chamber cells and flare were noted. Pigments were seen on anterior capsule of lens. Dilated fundus examination revealed a normal appearing disc with no cup in Right Eye and pale disc with C:D ratio 0.8 with a thin Neuro-retinal rim in the Left Eye. Colour vision was normal. Intra ocular pressure (IOP) was 14 and 35 mm of Hg by applanation in the Right and Left Eye respectively. On gonioscopy ciliary body band was visible for 360 degree without any Peripheral anterior Synechiae or inflammatory deposits. Automated perimetry revealed full visual field in the right eye and a dense scotoma with central island of field in the left eye. He was treated with oral and topical antiglaucoma medications along with topical steroids. On follow up his vision was 6/6(RE) and 6/12(LE) with IOP of 12 and 16 mm of Hg.

**Keywords:** Glaucomatocyclitic Crisis, Secondary inflammatory glaucoma, Intraocular pressure (IOP).

### Introduction

Posner-Schlossman Syndrome (PSS) also known as glaucomatocyclitic crisis, is a disease characterized by acute, unilateral, recurrent attacks of elevated intraocular pressure (IOP) accompanied by mild anterior chamber inflammation<sup>[1]</sup>. The inflammation may follow the rise in intraocular pressure by some days or is so

mild to be overlooked, so the etiology for rise of IOP may not be clear at the initial presentation. The pathophysiology is still unknown, although there are several theories proposed ranging from autoimmune to infectious. Treatment management is focused on controlling the intraocular pressure and decreasing inflammation. While an attack usually resolves without sequelae, repeated

attacks over time may lead to long-term glaucomatous damage. PSS can be a challenging diagnosis at presentation with raised intraocular pressure which is disproportionate compared to the mild symptoms and minimal signs of anterior segment inflammation. This can lead to a misdiagnosis of PACG and unnecessary laser iridotomies. The episodic and recurrent nature of PSS and the risk of progression to POAG warrants close monitoring of the patient.


### Case History

A 32 years old male patient presented with complaints of mild redness, pain and blurring of vision of the left eye for last 4 days. He gave history of similar episode 4-5 months back and it subsided with some treatment. There were no associated complaints of floaters flashes and coloured halos. Visual acuity on presentation was 6/6 unaided in the right eye and 5/60 improving to 6/12 with -1.5DSph/ -2.75 D Cyl at 110 degrees in the left eye. Right eye –anterior segment examination was within normal limits. In the left eye there was no circumcorneal congestion present. Fine Keratic Precipitates were noted in the cornea (Figure 1) and trace Ant Chamber cells and flare were noted. Pigments were seen on anterior capsule of lens (Figure 2). There was no vitritis present. Dilated fundus examination revealed a normal appearing disc with no cup in right eye and pale disc with C:D ratio 0.8 with a thin Neuro retinal rim in the left eye. Colour vision was normal. Intra ocular pressure (IOP) was 18 and 35 mm of Hg by applanation in the Right and Left Eye respectively. On gonioscopy ciliary body band was visible for 360 degree without any Peripheral anterior Synechiae or inflammatory deposits( Figure 4). Automated perimetry revealed full visual field in the right eye and a dense scotoma with central island of field in the left eye. For acute management of the patient's elevated IOP, Tab Acetazolamide 500mg TDS, E/D Timolol+ Dorzox TDS and E/D Brimonidine TDS were started. The IOP decreased to 24 mmHg after several hours. Due to the subtle

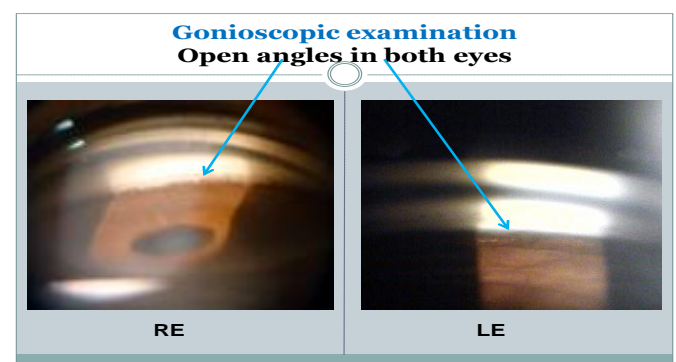
anterior segment inflammation, prednisolone acetate 1% was also started. The patient was instructed to continue timolol-dorzolamide twice daily (BID), brimonidine tartrate BID and prednisolone acetate 1% four times daily. On follow up after one week his vision was 6/6(RE) and 6/12(LE) and IOP had decreased to 16 mmHg in the left eye. His prednisolone acetate 1% was tapered and IOP lowering medications were gradually stopped.



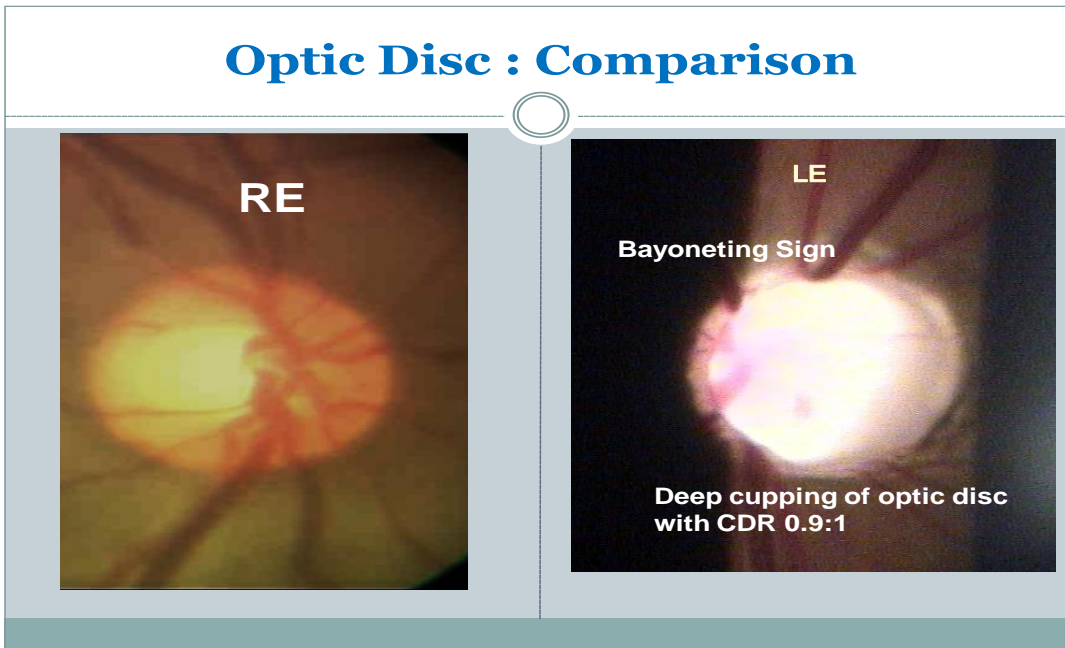
**Figure 1.** Photograph of the anterior segment of the left eye showing Keratic precipitates



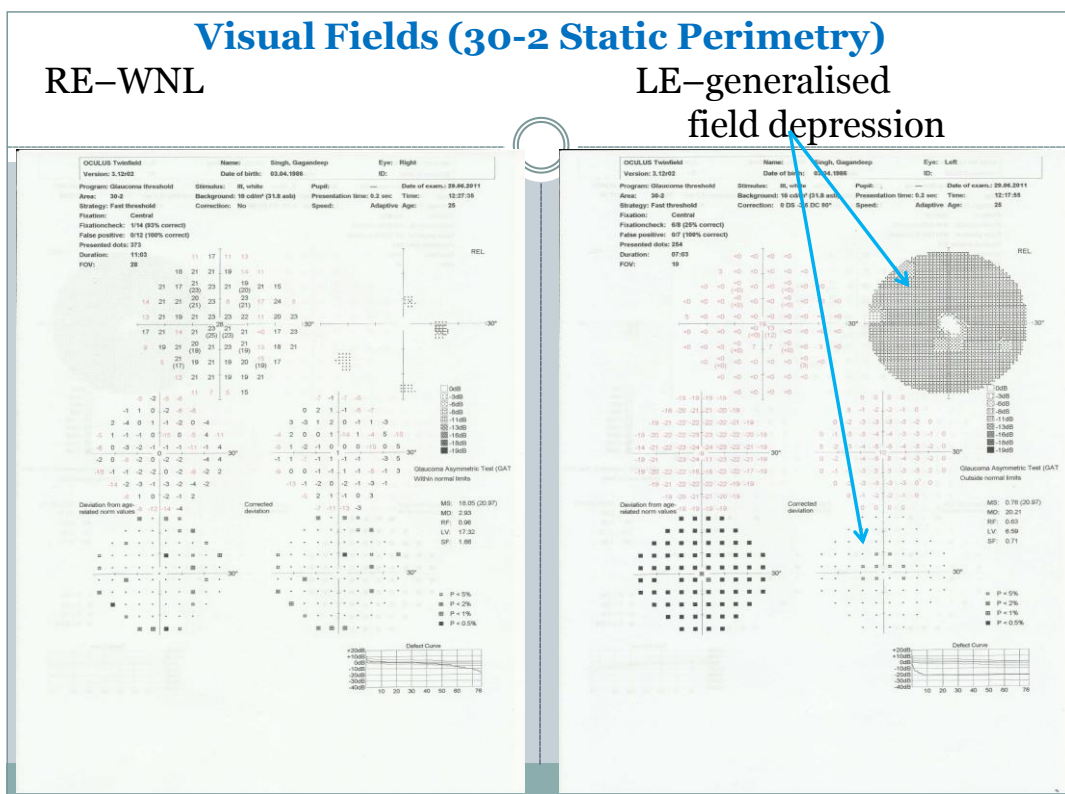
**Figure 2.** Pigments on Anterior Lens Capsule in the left eye



**Figure 3** Gonioscopy revealed open angles in both eyes (ciliary body band was visible 360 degrees without any synechiae/ inflammatory deposits)



**Figure 4.** A normal appearing disc with no cup in right eye and a pale disc with C:D ratio 0.8 and thin Neuro retinal rim in the left eye.



**Figure 5.** Full visual field in the right eye and a dense scotoma with Central Island of field in the left eye.

**Discussion**

Posner and Schlossman first reported a series of 9 cases who suffered from recurrent unilateral attacks of ocular hypertension in individuals aged 20-50 yrs with duration of attack varying from few hours to several weeks<sup>2</sup>. These patients

showed signs of a slight decrease in vision, elevated IOP with open angles, corneal edema with a few keratic precipitates, heterochromia with anisocoria, and a large pupil in the affected eye. Analysis of visual fields and optic discs was found to be normal. The exact pathophysiology of

Posner Schlossman Syndrome (PSS) is still unknown. Both immunological and infectious etiologies have been considered in the pathogenesis<sup>[3,4,5]</sup>. PSS is a rare condition with an uncertain aetiology and no recognised associated systemic conditions. A Japanese study of 22 patients with PSS showed that HLABw54 was positive in nine (41 per cent),<sup>6</sup> implicating a possible CD8 T-cell immunogenetic role. Herpes simplex virus has been detected in the anterior chamber of a small sample of three patients during ocular hypertensive attacks.<sup>7</sup> There are two reports of non-arteritic ischaemic optic neuropathy (NAION) associated with PSS attacks.<sup>8,9</sup> Both patients had small optic discs with little or no physiological cupping in the affected eye, which are known risk factors for NAION.<sup>10</sup>

In this case the patient is a 32 yrs male who presented with typical history of recurrent attacks of with asymptomatic period between the attacks. Mild anterior chamber reaction with signs of raised IOP and response to topical steroids and anti-glaucoma agents helped in clinching the diagnosis of Posner and Schlossman syndrome.

The diagnosis of Posner-Schlossman syndrome can be easily missed due to its mild inflammatory nature<sup>[11]</sup>. The diagnosis is based upon clinical features and the elimination of other possibilities which includes Acute and Chronic angle closure glaucoma, Primary open angle glaucoma, Ocular hypertension, Herpetic anterior uveitis and Fuchs Heterochromic Iridocyclitis, Primary open angle glaucoma was ruled out as signs of inflammation are usually absent and it is a bilateral disease with raised IOP, open angles, optic disc and visual field defects. Persistently elevated IOP without resolution with lack of anterior chamber inflammation pinpoints to the diagnosis of Ocular hypertension. Absence of significant PAS on gonioscopy rules out chronic angle closure glaucoma. Fuchs Heterochromic Iridocyclitis can be ruled out due to absence of heterochromia, stellate shaped keratic precipitates, fine abnormal angle vessels on gonioscopy and posterior subcapsular cataract.

Initial treatment is directed towards controlling intraocular pressure and decreasing inflammation. Typical first-line therapeutics include topical beta-blockers such as timolol, alpha-agonists such as brimonidine, and carbonic anhydrase inhibitors such as dorzolamide. Apraclonidine has also been advocated as a first-line agent.<sup>[12]</sup> Systemic anti-glaucoma agents like Hyperosmotics and Carbonic anhydrase inhibitors can be used to lower the IOP in acute attacks<sup>[13]</sup> In cases where the IOP cannot be controlled using maximal medical therapy, surgical therapy may be considered, especially when signs of glaucomatous optic nerve damage or visual field changes appear.<sup>[14]</sup>

### Conclusion

Posner-Schlossman Syndrome is a challenging problem. Early detection and diagnosis through careful clinical examination followed by appropriate ancillary testing and treatment is an effective strategy to manage it. It has long thought to be a "benign" disease; most patients are treated for attacks and recover without long-term sequelae. However, the development of glaucomatous field defects and optic neuropathy has been found to be proportional to the duration of elevated IOP and not the frequency of attacks. Therefore, patients with Posner Schlossman syndrome should be followed, at minimum on an annual basis even if their attacks occur on a less frequent basis.

**Conflicts of Interest:** None

### References

1. Posner A, Schlossman A. "Syndrome of unilateral recurrent attacks of glaucoma with cyclitic symptoms." *Arch Ophthalmol*. 1948 Apr; 39(4):517-35.
2. Posner A, Schlossman A. "Further observations on the syndrome of glaucomatocyclitic crisis." *Trans Am Acad Ophthalmol Otolaryngol*. 1953; 57:531.

3. Isogai, E., Isogai, H., Sato, N., Yuzawa, M., Kawakami, M. Antibodies to *Borrelia burgdorferi* in dogs in Hokkaido. *Microbiol. Immunol.* 1990;34:1005.
4. Takusagawa HL, Liu Y, Wiggs JL. "Infectious theories of Posner-Schlossman syndrome." *Int Ophthalmol Clin.* Fall 2011;51(4):105-15.
5. Teoh SB, Thean L, Koay E. "Cytomegalovirus in aetiology of Posner-Schlossman syndrome: evidence from quantitative polymerase chain reaction." *Eye.* Dec 2005;19(12):1338-40.
6. Hirose S, Ohno S, Matsuda H. HLA-Bw54 and glaucomatocyclitic crisis. *Arch Ophthalmol* 1985; 103: 1837–1839.
7. Yamamoto S, Pavan-Langston D, Tada R, Yamamoto R, Kinoshita S, Nishida K, Shimomura Y, Tano Y. Possible role of herpes simplex virus in the origin of Posner-Schlossman syndrome. *Am J Ophthalmol* 1995; 119: 796–798.
8. Kim R, Van Stavern G, Juzych M. Nonarteritic anterior ischemic optic neuropathy associated with acute glaucoma secondary to Posner-Schlossman syndrome. *Arch Ophthalmol* 2003;121:127–128.
9. Irak I, Katz B, Zabriskie N, Zimmerman P. Posner-Schlossman syndrome and nonarteritic anterior ischemic optic neuropathy. *J Neuroophthalmol* 2003; 23: 2003: 264–267.
10. Burde RM. Optic disk risk factors for nonarteritic anterior ischemic optic neuropathy. *Am J Ophthalmol* 1993; 116: 759–764.
11. Green RJ. Posner Schlossman syndrome. *Clinical Experimental optometry* 2007; 9053-9056.
12. Muthusamy P. "Apraclonidine in the management of glaucomatocyclitic crisis." *Eye.* 1994;8(Pt 3):367-8.
13. Kanski j. *Clinical ophthalmology. A Systematic Approach* 6<sup>th</sup> Edition London Butterworth Heinemann Elseiver. 2007
14. Hung PT, Chang JM. "Treatment of glaucomatocyclitic crises." *Am J Ophthalmol.* 1974;77:169–172.