



## To Study the Frequency and Pattern of Skin Changes in Pregnancy

Authors

**Manikya Latha S.<sup>1\*</sup>, B.Haritha<sup>2</sup>**

<sup>1</sup>Department of Dermatology, NIMRA Medical College and Hospital, Vijayawada Andhra Pradesh, India

<sup>2</sup>Department of Biochemistry, Siddhartha Medical College, Vijayawada, Andhra Pradesh, India

### ABSTRACT

**Aim & Objectives:** *To study the frequency and pattern of skin changes in pregnancy*

**Materials & Methods:** *The material for the study constituted of 100 patients selected from the outpatient antenatal clinic and antenatal ward at NIMRA medical college and Hospital, Vijayawada. All the patients had a complete dermatological examination including the examination of the skin, hair, nails and mucous membranes. All the patients were examined for physiological and pathological changes. All the systems were examined. Vaginal and cervical swabs were taken in patients, who complained of vaginal discharge and pruritus. Routine antenatal investigations were performed such as CBP, CUE, Blood sugar, Blood urea, Serum Creatinine, Blood grouping and typing, HIV & VDRL and HbsAg were done in all patients as a part of antenatal screening. Liver Function Tests was done for patients who complained of pruritus and who had icterus. Vaginal and cervical swabs were taken in all the patients complaining of vaginal discharge and pruritus of vulvae. These swabs were submitted for direct microscopy and culture for candidiasis, Gram's staining and microscopy and wet mount examination.*

**Results:** *A total number of 100 pregnant women were examined for dermatological changes. Most of the women were multipara and (68) the remaining were primies (32). 68% of the women examined were multiparous with 5% having more than 3 pregnancies. 15 multipara women in our study belonged to more than 30 years of age group. Pregnancy dermatoses were grouped into : Physiologic changes, Specific dermatoses and dermatoses affected by pregnancy. Pigmentation of the skin was the commonest physiological change seen more in multipara women (100%) than in primies (90.6%). Melasma was more frequent in multipara. Centrifacial type of melasma was the most common form of melasma seen. Striae were more common in the multigravida (79%) than in the primi (65%). Palmar erythema was seen in 8 out of the 100 examined, mostly in primis. The percentage of pregnant women with various affected dermatoses was 21% (21 out of 100). Infections and infestations constituted a major part of affected dermatoses (57%). Second episode of Varicella was seen in 2 out of the 21 dermatoses (9.5%). Both the cases of Varicella were noted in primis. The outcome of both these pregnancies was good.*

**Conclusions:** *In our study 12 out of 100 patients had specific dermatoses of pregnancy, of which pruritus gravidarum was the commonest followed by pruritic urticarial papules and plaques of pregnancy. The outcome of pregnancies in women with specific dermatoses of pregnancy and infections in pregnancy was good. There were no fetal anomalies or deaths. Vaginal discharge was observed in 2 out of 100 pregnant women. Only 1 case (50%) was positive for Candida albicans on culture.*

### INTRODUCTION

During pregnancy, many immunologic, metabolic, endocrine & vascular changes occur. These

changes, whether physiologic or pathologic, effect almost every organ of pregnant women including the skin & its appendages. These alterations are

seen, not only as normal cutaneous changes of pregnancy, but also influence certain pre-existing skin diseases<sup>[1]</sup> during pregnancy apart from being implicated as a cause of pregnancy specific dermatoses. Cutaneous changes & eruptions in pregnancy are very common & in some cases a cause of substantial anxiety to the prospective mother. Some of these are benign & reversible after delivery, whereas others can have potential side effects on the fetus in terms of morbidity & mortality.

Pregnancy is a period of significant and complex physiological changes<sup>[2]</sup>. Some of these changes are due to the de novo production of variety of protein and steroid hormones by foeto-placental unit as well as by the increased activity of maternal pituitary, thyroid and adrenal glands. Hormonal changes induced by normal pregnancy may have profound influence on skin. Foeto-placental production, stimulation or alteration of clearance of these hormones from circulation may increase the plasma availability of oestrogens, progesterone, androgens, adrenal steroids and pituitary hormones especially melanocyte stimulating hormone (MSH). These increased hormonal levels are implicated in the pathogenesis of various cutaneous changes of pregnancy. Immunologically mediated dermatoses such as herpes gestationis also occur during pregnancy.

Pregnancy may influence and modify pre-existing conditions such as porphyria cutanea tarda, melanoma, neurofibromatosis and various autoimmune dermatoses such as SLE, dermatomyositis, systemic sclerosis etc., apart from many other dermatoses. These disorders not only influence the outcome of pregnancy but also have profound effect on the health of the foetus. Infections of genital tract especially sexually transmitted diseases affect millions of people worldwide. Studies have indicated that prevalence of such infections is high during pregnancy. Bacterial and candidal vaginosis when severe may occasionally result in adverse outcome of pregnancy.<sup>[3]</sup>

Above observations highlight the importance of diagnosing and treating these infections to

decrease the morbidity and mortality of the mother and child. The present study is an attempt to provide a framework for approach to all types of dermatoses occurring in pregnant women. In this study, we have attempted to study the frequency and pattern of various dermatoses affecting the pregnant women.

## **MATERIALS AND METHODS**

The material for the study constituted of 100 patients selected from the outpatient antenatal clinic and antenatal ward at NIMRA medical college and Hospital, Vijayawada. Patients visiting antenatal O.P. and antenatal ward for a period of 2 years, between 2014-2016, were included in the study. Special case proforma was prepared which was used to record complaints, history, clinical features and results of investigations.

## **INCLUSION CRITERIA**

Antenatal cases attending antenatal OP and antenatal ward, Pregnancy confirmed by gravindex test, Primies and multigravidae., Pregnant women with abortions and fetal deaths, Pregnant women with previous history of skin diseases.

## **EXCLUSION CRITERIA**

Pregnant women with associated morbid conditions like pre-eclampsia, eclampsia, gestational diabetes, cardiac diseases, etc., Pregnant women taking any kind of medication for systemic illnesses. Patients on anti tuberculous treatment, multidrug therapy for leprosy or anti retroviral therapy.

## **CLINICAL EXAMINATION**

All the patients had a complete dermatological examination including the examination of the skin, hair, nails and mucous membranes. All the patients were examined for physiological and pathological changes. All the systems were examined. Vaginal and cervical swabs were taken in patients, who complained of vaginal discharge and pruritus.

## INVESTIGATIONS

Routine antenatal investigations were performed such as CBP, CUE, Blood sugar, Blood urea, Serum Creatinine, Blood grouping and typing, HIV&VDRL and HbsAg were done in all patients as a part of antenatal screening. Liver Function Tests was done for patients who complained of pruritus and who had icterus. Vaginal and cervical swabs were taken in all the patients complaining of vaginal discharge and pruritus of vulvae. These swabs were submitted for direct microscopy and culture for candidiasis, Gram's staining and microscopy and wet mount examination.

## GRAM STAINING

Smear was heat fixed and stained with 1% gentian violet for 1 minute. Stain was thrown away and slide washed with distilled water and Gram's iodine was poured onto the smear and allowed to act for 1 minute. Composition of Gram's iodine – iodine 1 gram, potassium iodine 2 grams in 300 ml of distilled water. Slide was washed with distilled water after throwing away the iodine and decolorized with absolute alcohol for 15 seconds. The smear was counter stained with dilute carbol fuchsin for 30 seconds. The slide is washed and blotted dry and observed under oil immersion lens after putting a drop of cedar wood oil. And examined for Gram +ve oval, budding yeast cell and Gram + ve pseudo hyphae.

## COLLECTION OF SPECIMEN FOR CANDIDIASIS

The specimen collected was high vaginal swab. After thorough local cleansing, a sterile speculum was introduced into the vagina and a sterile swab inserted into the upper part of vagina and rotated. The procedure was repeated with another vaginal swab. After withdrawing the swabs, they were submitted aseptically to the microbiology laboratory for processing, one swab was used for culture which inoculated onto the Sabourauds dextrose agar with added antibiotics (Chloramphenicol) and incubated at 37°C for 48-72 hours. Second swab was used for making smears for staining by Gram's method.

## CULTURE

Sabourauds Dextrose Agar: Steam to dissolve glucose, peptone, agar and adjust pH to 5.4. Autoclave at 115°C for 15 minutes and chloramphenicol is added. 20 ml amounts dispensed into petridishes and MacCartney's bottles and stored at 4 degree centigrade. After 48-72 hours incubation at 37°C opaque and pale coloured growth suggesting yeast colonies, were observed. Candida was confirmed microscopically by Gram's staining from the growth.

## RESULTS

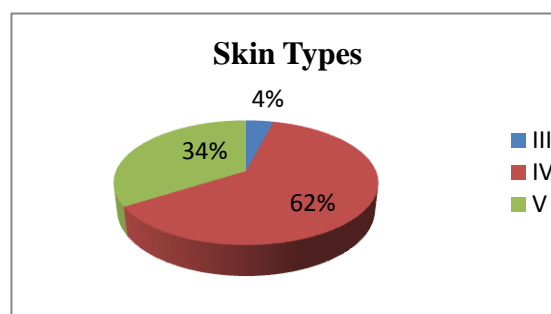
In this study, a total number of 100 patients were examined for skin changes and dermatoses during 2<sup>nd</sup> and 3<sup>rd</sup> trimester of pregnancy at NIMRA medical college and Hospital, Vijayawada. Out of these 100 patients, 32 were primigravida and 68 were multigravida women.

**TABLE – I TRIMESTERS**

Trimester of Pregnancy	Primigravida	Multigravida	Total
2 <sup>nd</sup> trimester	12	31	43
3 <sup>rd</sup> trimester	20	37	57

Most of the pregnant women examined were in their 3<sup>rd</sup> trimester of pregnancy. This observation was made in both the primis and multigravidae.

**FIG: 1 Skin Types of the Pregnant Women**



Pregnant women with skin types IV (62%) were more in the study, followed by skin type V(34%).

**TABLE – II** the age group of the pregnant women under study was tabulated

**AGE GROUPS**

	15 -20 yrs	21 - 25 yrs	26-30 yrs	>30 yrs
Primi	16	12	4	-
% of Primi	50%	37.5%	12.5%	-
Multi	6	32	15	15
% of Multi	8.8%	47%	22%	22%
Total	22	44	19	15

The following observations were made. Majority of the primies were between 15 – 20 years age group (50%). Whereas majority of Multipara belong to 21-25 years of age group (47%). 15 multipara women (22%) belong to more than 30 years of age group. On the whole, most number of pregnant women under study were between 15-25 years of age group (66%).

**TABLE III SKIN CHANGES IN PREGNANCY**

Physiological changes	Specific Dermatoses	Dermatoses affected in pregnancy
100	12	21

Our findings show that all the patients examined had physiological changes irrespective of the gravida and trimester.

**TABLE – VI OTHER PHYSIOLOGICAL CHANGES**

Physiological changes	Primi	%	Multi	%	Total
Hair changes					
Increased hair loss	-	-	2	2.9	2
Improved hair growth	1	3.1	3	7.8	4
Glandular changes					
Montgomery tubercles	-	-	4	5.8	4
Hyperhidrosis	1	3.1	-	-	1
Vascular changes					
Pedal edema	3	9.3	4	5.8	7
Palmar erythema	6	18.7	2	2.9	8
Varicose veins	-	-	1	1.4	1
Mucosal					
Chadwick’s sign	32	100	68	100	100
Goodell’s sign	32	100	68	100	100
Gum hypertrophy	2	6.2	-	-	2

Palmar erythema was more common in the primigravida (18.7%) than the multigravida (2.9%). Pedal edema was more common in the multigravida. When enquired about the hair

**TABLE – IV PIGMENTARY CHANGES**

Sites examined	Primi	%	Multi	%	Total
Breast	29	90.6	68	100	97
Linea nigra	24	75	68	100	92
Melasma	9	28.1	23	33.8	32
LSCS scar pigmentation	-	-	1	1.4	1

Pigmentary changes were the commonest changes observed in pregnancy. All the multigravida women examined had pigmentary darkening of the areola and the breast and linea nigra. The most common pigmentary change noted in the primi were pigmentation of the breast (90.6%) followed by line nigra (75%). Melasma was found to be more common in the multigravida than in the primi. One patient who had a previous LSCS had pigmentation over the scar.

**TABLE -V STRIAE DISTENSÆ**

Sites	Primi	%	Multi	%	Total
Abdomen	21	65.6	54	79.4	75
Breast	14	43.7	51	75	65
Other sites	4	12.5	29	42.6	33

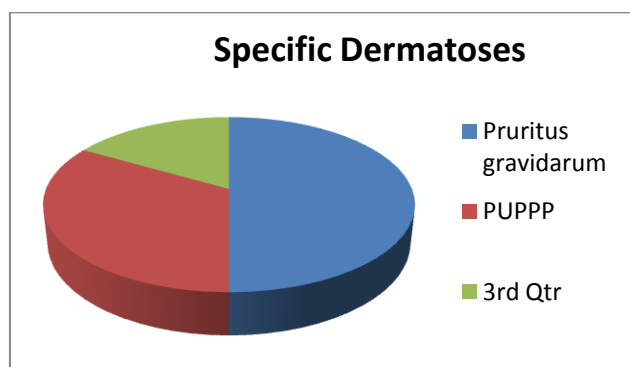
In both the primi and multigravida, striae were more common on the abdomen (75%), followed by the breast. They were also seen on the thighs, buttocks and legs.

changes, more women reported an increase in hair growth than hair loss. They also reported an improvement in the hair colour and quantity. Chadwick’s sign and Goodell’s sign were positive

in all the pregnant women examined. Gum hypertrophy was noted in 2 cases of primigravida. Varicose veins were noted in one multigravida.

**TABLE –VII SPECIFIC DERMATOSES OF PREGNANCY**

Dermatoses	Primi	%	Multi	%	Total
Pruritus gravidarum	4	12.5	2	2.9	6
PUPPP	2	6.2	2	2.9	4
Prurigo of pregnancy	-	-	2	2.9	2



Pruritus gravidarum was noted to be the most common pregnancy specific dermatoses occurring in 6 of the examined pregnant women. It is more common in the primigravida (12.5%) and in the 2<sup>nd</sup> trimester. The next common pregnancy specific dermatoses was pruritic urticarial papules and plaques of pregnancy occurring in 4 of the examined cases.

Prurigo of pregnancy was seen in 2 cases in the 3<sup>rd</sup> trimester and both the pregnant women had elevated serum alkaline phosphatases (doubled). These 2 women also gave history of similar complaints in the previous pregnancies. All women with specific dermatoses of pregnancy delivered healthy babies.

**TABLE – VIII DERMATOSES AFFECTED BY PREGNANCY**

Dermatoses	Primi	Multi	Exacerbated/Improved/ New onset/No change
Inflammatory dermatoses			
• Atopic Dermatitis	-	1	Exacerbated
• Discoid Eczema	1	-	Exacerbated
• Pompholyx	1	-	New onset
• Psoriasis	-	1	No change
• Acne	1	-	New onset
Infections			
Fungal			
• Candidal vaginitis	1	1	New onset
• Tinea corporis	-	1	No change
• Condylomaacuminata	-	1	Exacerbated
• Varicella	2	-	Second episode
• Herpes labialis	2	-	Recurrences
• Verruca Parasitic	-	1	Exacerbated
• Scabies	-	3	New onset
Other dermatoses			
• Acrochordons	-	1	Exacerbated
• Amyloidosis	1	-	No change
• Lamellar ichthyosis	-	1	Exacerbated
• Drug reaction	-	1	New onset
<b>Total</b>	<b>9</b>	<b>12</b>	

Infections and infestations of skin were the commonest dermatological afflictions observed during the present study of pregnant women and they were present in 12 out of 100 patients under the study (12%). Scabies was observed in 3 out of 100 patients under study. Second episode of

chicken pox occurred in 2 cases of primigravida. Recurrences of herpes labialis occurred in 2 primies. Florid genital warts, verruca vulgaris and tinea corporis were noted in one case each. The women with viral infections were followed up and their fetal outcome was good. Discoid eczema was

observed in 1 patient. Pompholyx developed in an old case of palmoplantar hyperhidrosis in a primi. One women with guttate and nail psoriasis was examined. There was no change in her condition. One primi developed acne lesions in the last month of pregnancy. One each case of acrochordons, amyloidosis, drug reaction and lamellar ichthyosis were examined.

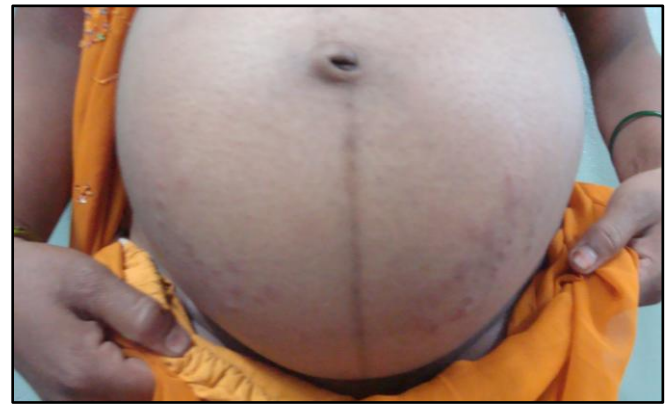**TABLE – IX MYCOLOGICAL STUDY OF CANDIDIASIS**

No. of swabs taken	Smear positive	Culture positive
2	-	1 ( <i>Candida albicans</i> isolated)

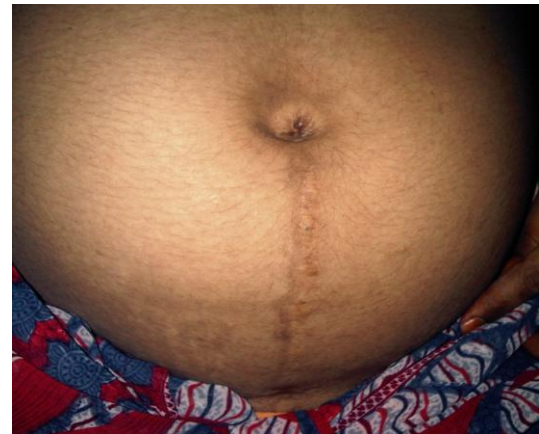Vaginal and cervical swabs were taken from 2 patients. Both the cervical swabs were negative. When the vaginal swabs were subjected to KOH mount and culture, the following results were noted.

Only one swab was positive for *Candida albicans* with culture on Sabourand’s Dextrose agar.

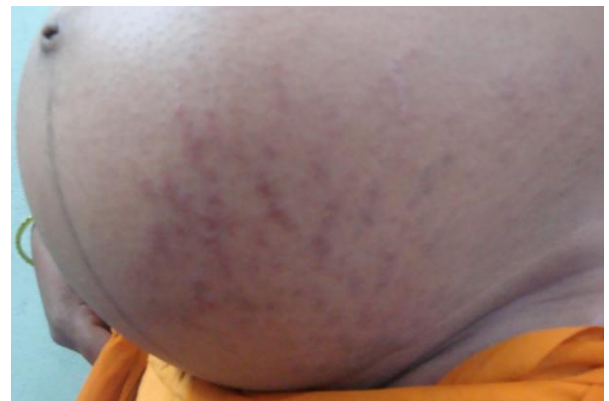**Fig 2: Melasma.**



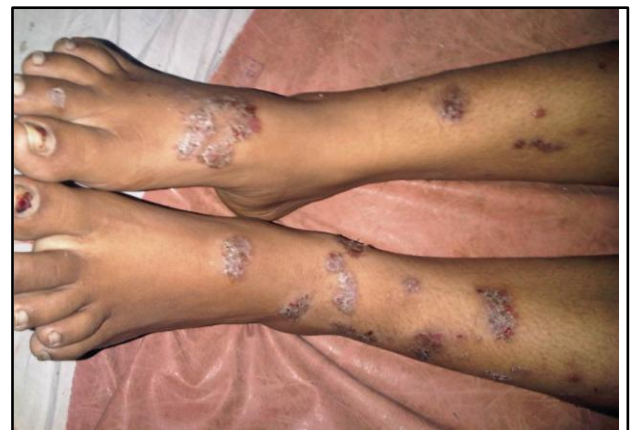**Fig 3: Linea nigra and striae gravidarum.**



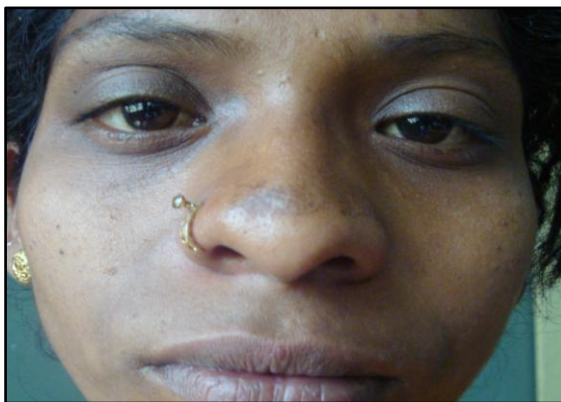**Fig 4: Pigmentation in LSCS scar.**



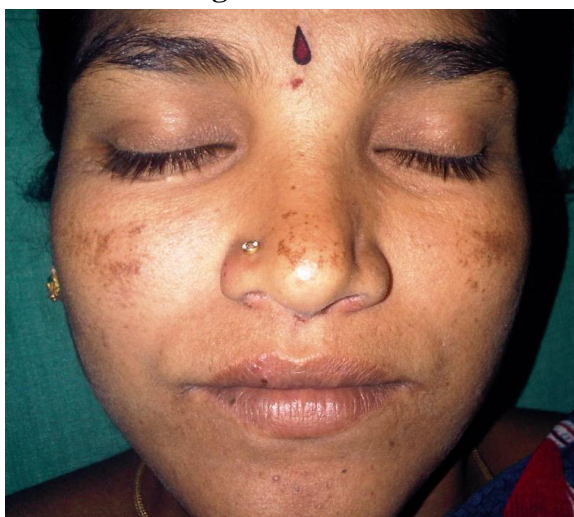**Fig 5: PUPPP lesions along the striae.**

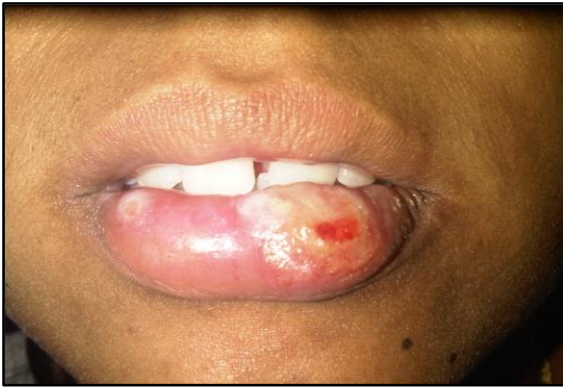

**Fig 6: Prurigo of pregnancy.**

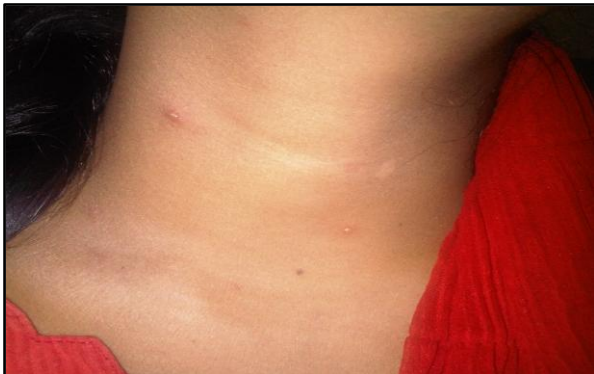

**Fig.1: Melasma.**

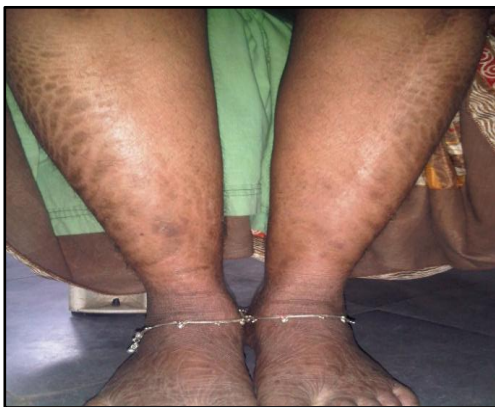



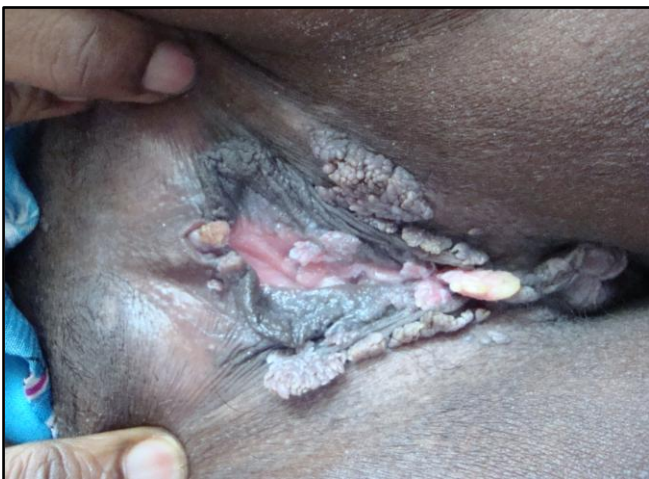**Fig 7:** Herpes labialis.



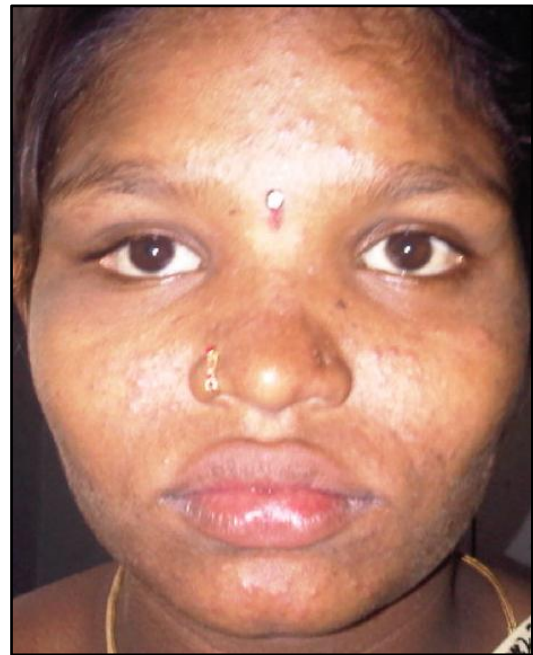**Fig 8:** Varicella



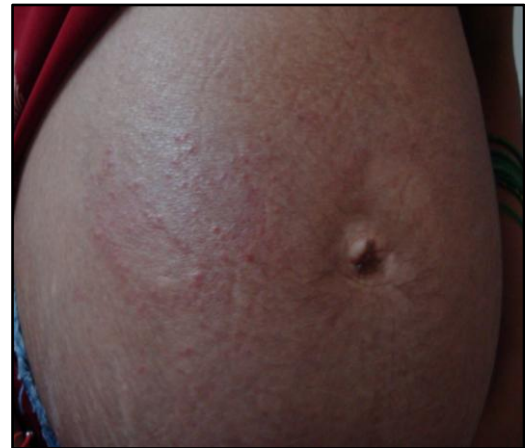**Fig 9:** Lamellar ichthyosis in a pregnant women



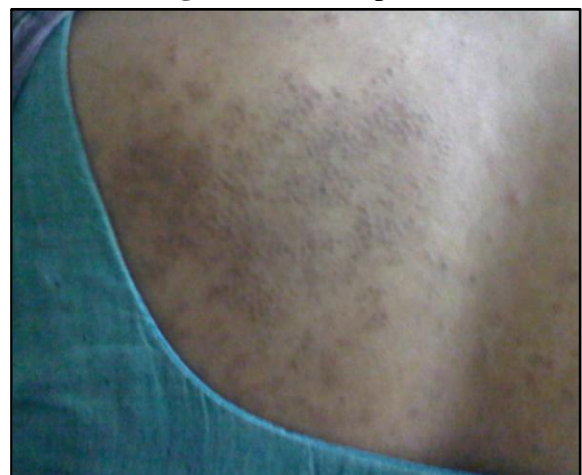**Fig 10:** Condyloma acuminata.



**Fig 11:** Acne in pregnancy.



**Fig 12:** Tinea corporis



**Fig 13:** Amyloidosis.

## DISCUSSION

In this study of 100 pregnant women, all the patients belonged either to 2<sup>nd</sup> or 3<sup>rd</sup> trimester which might be because the majority of pregnant women attending the antenatal OPD come from a rural background. They attend the antenatal clinics only in an advanced trimester. Few 1<sup>st</sup> trimester women attend the antenatal clinics and this have been general observation.

The pregnant women who were >30 years of age were 15 (all of them multiparous women). Pregnancy dermatoses were grouped into: Physiologic changes, specific dermatoses and dermatoses which are modified by pregnancy. Physiological changes in pregnancy<sup>[4]</sup> were looked for in the study group. One or more physiological changes of skin were observed in all the patients under study which is a general observation considering the skin types in the area of study<sup>[5]</sup>. Pigmentation of the skin was the commonest physiological change observed in 100% of Multipara and 90.6% primies. Similar high incidence of pigmentary change was observed in the study based at JIPMER<sup>[6]</sup>. Melasma was observed in only 30% of the patients under study. This is in contrast to the observation made by Winton and Lecins (1982) in a study based at USA where the incidence was 50%. This can be explained by the easy detectability of facial hyperpigmentation in the white people. Other Indian studies<sup>[5]</sup> showed lower incidence (8.8%) of melasma which was also observed in our study.

Striae were most commonly observed on abdomen and more frequently in multipara than primies<sup>[6]</sup>. This is a common finding in all studies. Vascular effects such as palmar erythema, varicose veins and pedal oedema were observed in a total of 16 out of 100 patients (i.e. 16%) of which, palmar erythema was the most frequent. Similar observations were made by Raj S. et. al. in their study. The specific dermatoses of pregnancy<sup>[7]</sup> was seen in 12% of patients in our study. The most common pregnancy specific dermatoses was pruritus gravidarum occurring in 6 cases. Only 2 cases showed icterus, but were negative for Hbs Ag with raised LFT values. Obstetric cholestasis

by<sup>[8]</sup> far is the commonest cause of jaundice in pregnant women. Cholestasis might be the cause of icterus in both pregnant women as indicated by the high alkaline phosphatase levels (> 800 I.U.). The incidence of prurigo of pregnancy was 2%. Winton et. al. (1982) reported the incidence of prurigo gestationis as 2%. Kumar E. S. in the study based at Karnataka observed prurigo of pregnancy to account for 9.4% of all dermatological conditions. Many workers report that the incidence of prurigo pregnancy is most frequent among non-specific dermatoses specific of pregnancy. But in our study pruritus gravidarum was them most common. The percentage of dermatoses modified during pregnancy were 21% out of 100 patients. Infections and infestations constituted a major part of deramtoes (57%). Similar observations were made by Kumari et al<sup>[5]</sup>. Over all the incidence of infections were higher among primies than multipara in our study.

Vaginal discharge was observed in 2/100 patients in our study. In a study by Kumar E. S. (1998)<sup>[9]</sup>, vaginal discharge was present in 21.7% of pregnant women with skin disorders. Only 3.8% of pregnant women under study had vaginal candidiasis in the study of Raj S. et. al. Candidial vaginitis<sup>[10]</sup> occurs more frequently during pregnancy, as altered hormonal status favours the infection Dotz et. al. (1991). This might be because of the difference in the proportion of cases studied. S.T.D's observed in our study were genital warts and herpes labialis. Condyloma accuminata is a common STD encountered in various studies of pregnant women. More over most of these patients were primigravida. Similar observation of exclusive occurrence of condyloma accuminata<sup>[5]</sup> was observed in the present study in primigravida.

Vaginal swabs for candida were taken in 2 cases. The positivity of candidiasis increased when discharge was inoculated on sabouraud agar and 1 out of 2 inoculates turning positive for candida (i.e. about 50%). This is in contrast to the observation made by Kumar E. S. (1998) where in candidiasis constituted only 21% of all vaginal



discharges. The variation could be because of the proportion of cases taken up in both the studies. Candidal infection<sup>[11]</sup> on the whole was observed in (2 out of 100 patients) 2% of patients in our study. Near similar incidence of 2.8% was observed by Raj et. al. of vaginal candidiasis in their study. In a study by Sobel et. al; *Candida albicans* was isolated in only 69% of pregnant women with vaginitis. However, in our study, in 50% of the patients *Candida albicans* was isolated.

## CONCLUSIONS

A total number of 100 pregnant women were examined for dermatological changes. Most of the women were multipara and (68) the remaining were primies (32).68% of the women examined were multiparous with 5% having more than 3 pregnancies.15 multipara women in our study belonged to more than 30 years of age group. Pregnancy dermatoses were grouped into: Physiologic changes, Specific dermatoses and dermatoses affected by pregnancy. Pigmentation of the skin was the commonest physiological change seen more in multipara women (100%) than in primies (90.6%). Melasma was more frequent in multipara. Centrofacial type of melasma was the most common form of melasma seen. Striae were more common in the multigravida (79%) than in the primi(65%). Palmar erythema was seen in 8 out of the 100 examined, mostly in primis.

The percentage of pregnant women with various affected dermatoses was 21% (21 out of 100). Infections and infestations constituted a major part of affected dermatoses (57%).

Second episode of Varicella was seen in 2 out of the 21 dermatoses (9.5%). Both the cases of Varicella were noted in primis. The outcome of both these pregnancies was good.

In our study 12 out of 100 patients had specific dermatoses of pregnancy, of which pruritus gravidarum was the commonest followed by pruritic urticarial papules and plaques of pregnancy. The outcome of pregnancies in women with specific dermatoses of pregnancy and

infections in pregnancy was good. There were no fetal anomalies or deaths. Vaginal discharge was observed in 2 out of 100 pregnant women. Only 1 case (50%) was positive for *Candida albicans* on culture.

## REFERENCES

1. Lawley TJ, Yanecy KB. Skin changes and diseases in pregnancy. In: Fitzpatrick TB, Freedberg IM, Eisen AZ, Wolff K, Austen KF, Goldsmith LA. Katz SI, editors. *Dermatology in General Medicine* 5th edition. New York: Mcgraw-Hill; 1998:1967-1968.
2. Michaud R, Jacobson D, Dahl M. Papular dermatitis of pregnancy, *Arch Dermatol* 1982; 118:1003-5.
3. Holmes RC. Skin Diseases specifically associated with pregnancy. In: Harrahup M, Wallach RC, editors. *Skin Changes and Diseases in pregnancy*. New York: Dekker: 1996:74-78.
4. Wong RC, Ellis CN. Physiologic changes in the skin during pregnancy. *J Am Acad Dermatol* 1984; 10:929-40.
5. Kumari R, Jaisankar TJ, Thappa DM. A clinical study of skin changes in pregnancy. *Ind J Dermatol Venereol and Leprol*, 2007; 73:141.
6. Poidevin LO. Striae gravidarum. Their relation to adrenal cortical hyperfunction. *Lancet* 1959; 2:436-9.
7. Kroumpouzou G, Cohen LM. Specific dermatoses of pregnancy: an evidence-based systematic review. *Am J Obstet Gynecol* 2003;188:1083-92.
8. Summerskill W. H. J. Walshe J. M. : 'Benign recurrent intrahepatic obstructive jaundice' 1959, *Lancet* 2, 686-690.
9. Kumar E. S. 'Skin in Pregnancy' : Dissertation submitted to Kevempu University Karnataka, 1998
10. Reilly FM, Darby C, Fogarty J, et. al. Screening of patients with iron overload to identify hemochromatosis and porphyria

cutanea tarda. Arch Dermatol 1997;  
133:1098-101.

11. Odd F. C. et. al. : 'Candida concentration in the vagina and their association with signs and symptoms of vaginal candida infection Eur. J. Obst. And Gyn. Reproduce Biol. 1983, 15, 37-43.