



## Scrub Typhus with a Rare Presentation in a Child- A Case Report

Authors

**Aroop Mohanty<sup>1</sup>, Pratima Gupta<sup>1</sup>, T Shantikumar Singh<sup>2</sup>, Priyanka Gupta<sup>1</sup>**

<sup>1</sup>Department of Microbiology, All India Institute of Medical Sciences, Rishikesh, Uttarakhand

<sup>2</sup>Sikkim Manipal Institute of Medical Sciences, Gangtok, Sikkim

### Abstract

*Acute kidney injury (AKI) due to infections is an important preventable cause of morbidity and mortality in the tropical region. The prevalence and outcome of AKI in children with scrub typhus is not known. We report a case of AKI in a 2 year old child who had presented to our hospital with acute nephritic syndrome. With clinical suspicion on presence of an eschar and laboratory investigations the child was diagnosed to have scrub typhus. With definite treatment the child improved and recovered completely.*

### INTRODUCTION

Scrub typhus is a life-threatening zoonosis caused by *Orientia tsutsugamushi* organisms (formerly called *Rickettsia tsutsugamushi*) that are transmitted by the larvae of trombiculid mites. <sup>1</sup>It is endemic to a geographically distinct region, the so-called tsutsugamushi triangle, which includes Japan, Taiwan, China and South Korea. It also occurs in Nepal, Pakistan, Papua New Guinea, and Australian states. In India, the disease had occurred among troops during World War II in Assam and West Bengal and in the 1965 Indo-Pak War. Now It is known to occur all over India, including Southern India and Northern India.<sup>2</sup> Scrub typhus is grossly under-diagnosed in India due to its non-specific clinical presentation, limited awareness low index of suspicion among clinicians and lack of diagnostic facilities in most places. There is a paucity of studies regarding the incidence and clinical profile of scrub typhus in children.<sup>3</sup> Scrub typhus is considered as an uncommon cause of acute kidney injury (AKI)

even in endemic areas. Renal involvement is thought to be a consequence of multi-organ dysfunction syndrome secondary to sepsis.<sup>4</sup>

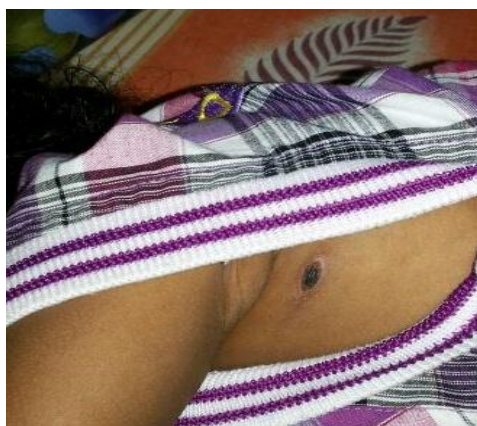### CASE REPORT

A 2- year- old male child, resident of Mangan, North Sikkim presented to the Department of Paediatrics, Central Referral Hospital, Sikkim with fever associated with chills for 6 days, decreased urine output for 4 days, progressive abdominal swelling associated with loose stools for 3 days and non-productive cough for 2 days and was hospitalized. Physical examination revealed a febrile child with pallor, periorbital puffiness, pedal edema, hepatomegaly, evidence of free fluid in abdomen, and bilateral pleural effusion. Injection Ceftriaxone was started empirically along with supportive treatment but the child did not improve. Anti-Streptolysin O test was done in order to rule out post streptococcal glomerulonephritis which was negative. A brownish-black crusted lesion with surrounding

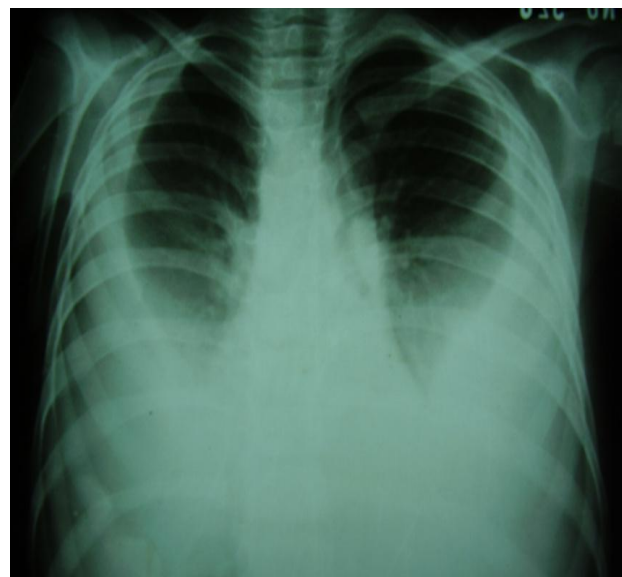
erythema-eschar was found below left axilla (Figure-1). Results of complete blood count, urine analysis and renal function tests are given in (Table-1). The urine analysis indicated proteinuria, microscopic hematuria and RBC casts. Blood urea and serum creatinine were raised. The Chest X-Ray PA view confirmed bilateral pleural effusion (Figure-2). USS of abdomen and pleural spaces revealed ascites with hepatospleno-megaly and bilateral pleural effusion. Widal test was negative. HbsAg and Anti HCV was negative. A diagnosis of Scrub typhus complicated with AKI was made based on basis of clinical findings, laboratory results and positive Weil-Felix test and IgM ELISA. Tab Doxycycline was started on 3<sup>rd</sup> day of admission by 6<sup>th</sup> day of admission, child became afebrile, with regression of oedema and was discharged home on the 10<sup>th</sup> day.

**Table 1.** Results of Laboratory Tests

Variables	Reference Range	Results
Hemoglobin (g/dl)	13-18	9.9
White cell count (per mm <sup>3</sup> )	4000-11000	6600
Differential cell count		N <sub>85</sub> , L <sub>12</sub> , M <sub>2</sub> E <sub>2</sub>
Platelet count (per mm <sup>3</sup> )	1,50,000-3,50,000	90,000
Peripheral Blood Smear		Normocytic normochromic RBCs No hemoparasites
Urea (mg/dl)	15-40	43
Creatinine (mg/dl)	0.68-1.36	1.4
Sodium (meq/L)	135-145	167
Potassium (meq/L)	3.6-5.0	7.8
Total Bilirubin (mg/dl)	0.18-0.94	3.1
Direct Bilirubin (mg/dl)		1.5
AST (IU/L)	10-45	161
ALT (IU/L)	10-50	148
ALP (IU/L)	40-125	1400



**Figure 1:** Solitary eschar below left axilla



**Figure 2:** CXR PA View showing Bilateral Pleural Effusion

## DISCUSSION

Rickettsial infections are emerging as pathogens around the world in areas which were hitherto unaffected. The rickettsial diseases were once thought to have disappeared from India, but cases are re-emerging from several parts of the country. Scrub typhus is now most commonly reported rickettsial infection from the Indian subcontinent. In India, scrub typhus cases have been regularly reported from Vellore and Tamil Nadu.<sup>5</sup> There are scanty reports of scrub typhus from Sikkim state.<sup>6</sup> Ogawa et al have reported presence of eschars in 7 to 97% of scrub typhus cases in Japan.<sup>8</sup> Multiple eschars have been reported in a single patient.<sup>9</sup> In our case a diligent search for skin rashes helped in finding an eschar and later helped in diagnosis. The majority of studies regarding rickettsial infections from various parts of the world are based on adult populations.<sup>3</sup> There is paucity of studies regarding the incidence and clinical profile of scrub typhus in children of scrub typhus. Scrub typhus is regarded as a life threatening disease in children. Rickettsial infections have been overlooked as a cause of AKI, especially in children. A recent retrospective study from central India did not report any case of AKI in children with Rickettsial infections.<sup>10</sup> Several studies have reported lower incidences of AKI ranging from 2 to 10%. According to Yen H

et al. scrub typhus presented with symptoms of acute renal failure is a rare but a serious condition.<sup>11</sup> The mechanism of AKI in scrub typhus is mainly believed to be impaired renal perfusion due to volume depletion or increased vascular permeability. Overall, renal involvement is considered to be a part of multi-organ dysfunction in patients with severe disease.<sup>4</sup>

## CONCLUSION

Scrub typhus has been under diagnosed in India due to its non-specific clinical presentation, limited awareness and low index of suspicion among clinicians and lack of diagnostic facilities. The clinical manifestations of scrub typhus in children are nonspecific and are likely to be misdiagnosed. Scrub typhus does not find a mention in most descriptions of tropical community acquired AKI. Considering the re-emergence of scrub typhus in India, patients presenting with fever and acute kidney injury should be investigated for scrub typhus. Early diagnosis of scrub typhus and the initiation of empirical therapy with doxycycline will reduce the patient morbidity and mortality.

## REFERENCES

1. Weitzel T, Dittrich S, Lopez J, et al. Endemic Scrub Typhus in South America. *N Engl J Med*.2016; 375:954-61.
2. Chogle AR. Diagnosis and treatment of Scrub Typhus-The Indian Scenario. *J Assoc Physician India*.2010; 58:11-2.
3. Bhat NK, Dhar M, Mittal G, et al. Scrub Typhus in children at a tertiary care Hospital in North India: Clinical Profile and Complications. *Iran J paediatric*.2014; 24:387-392.
4. Kumar V, Kumar V, Yadav A. Scrub typhus is an under-recognised cause of Acute febrile illness with acute kidney in India. *PLOS neglected tropical Diseases*. 2014; 8:e2605.

5. Prakash A, Acharya AS, Jain N, et al. Scrub typhus – An emerging public health problem in Delhi. *Ind J of Med Specialities*. 2014; 5: 68-72.
6. Gupta N, Mittal V, Gurung B et al. Pediatric Scrub Typhus in South Sikkim. *Indian Pediatr*. 2012;49: 322-324.
7. Gurung S, Pradhan J, Bhutia PY. Outbreak of scrub typhus in the North East Himalayan region-Sikkim: An emerging threat. *Indian Journal of Medical Microbiology*. 2013; 31: 72-74.
8. Ogawa M, Hagiwara T, Kishimoto T et al. Scrub typhus in Japan: Epidemiology and clinical features of cases reported in 1998. *Am J Trop Med Hyg*.2004; 98: 354-59.
9. Kaushik RM, Kaushik R, Bhargava A. Multiple Eschars in Scrub typhus. *Tropical Medicine and Health*.2014; 42:65-66.
10. Rathi NB, Rathi AN, Goodman MH, et al. Rickettsial diseases in central India: proposed clinical scoring system for early detection of spotted fever. *Indian Pediatr*. 2011; 48:867-72.
11. Yen TH, Chang CT, Lin JL, et al. Scrub typhus: a frequently overlooked cause of acute renal failure. *Ren Fail*.2003;25:397-410.