



64- Slice Multiple –Row Detector CT Angiography (MDCTA): Application in Peripheral Vascular Diseases

Authors

Abhinav A Mohan¹, Dr Amarnath R. Mohan², Dr Kiran Patankar³

¹Assistant Professor, Department Of Interventional Radiology Jawaharlal Nehru Medical College Sawangi-Meghe – Wardha. (MS)- India

²Consultant Radiologist, Sonoscan Imaging and Diagnostic Centre Pvt Ltd Miraj (MS)- India

³Consultant Radiologist, Apple Hospital and Research Institute Pvt Ltd Kolhapur (MS)- India

Corresponding Author

Dr Amarnath R. Mohan

Consultant Radiologist, Sonoscan Imaging and diagnostic centre Pvt Ltd Miraj (MS)- India

Abstract

Background: *With the improvements in design and techniques of advanced computed tomography techniques like multiple- row detector CT (MDCT), CT angiography of peripheral vasculature have become an easy, fast and feasible tool for imaging of peripheral vascular diseases. In addition to peripheral vascular disease CT angiography can also be used in patients with trauma or bone tumors. Peripheral vascular diseases in most instances develop gradually and there is ample time for development of collaterals, for this reason the patient may be unaware of the condition until there is critical stenosis. In some other patients the occlusion may be acute and may present with severe symptoms due to absence of collateral pathways. The signs and symptoms of peripheral vascular diseases depend upon site, distribution and severity of involvement of the vessels. The crucial role of CT angiography is to locate and characterize the involvement and to find out presence or absence of adequate collaterals. Reduced slice thickness and increased spatial resolution of modern CT machines have made it possible to non-invasively image the peripheral vessels. The advantage of quick and non-invasively imaging the peripheral vasculature cannot be overemphasized. We undertook this study as there was scarcity of centers undertaking comprehensive studies of Peripheral Arterial Disease (PAD) using advanced MDCTA in our area.*

Aims and Objectives: *(1) To discuss spectrum of imaging findings and define the role of Multiple-row Detector CT Angiography (MDCTA) in diagnosis and management Of Peripheral Arterial Occlusive Diseases. (2) To determine efficacy and accuracy of Multiple-row Detector CT Angiography (MDCTA) in cases of trauma and peripheral arterial occlusive disease [PAOD] in comparison to intra-operative surgical findings. (3) To discuss the merits, pitfalls and futuristic of MDCTA for Peripheral Vascular Applications.*

Materials and Methods: *The study was approved by institutional ethical committee. 64 patients meeting the criteria of the study were enrolled in the study. All these patients have undergone CT angiography on upper or lower limbs. All patients were scanned in the supine position with a Collimation of 0.6 mm, pitch 1 , tube voltage (kV) 120, tube current (effective mAs) 160, acquisition 2x32x0.6 mm , resolution <0.4mm, double z-sampling position (64 slices per rotation) with specific - scan range, specific coverage length and position. The R.O.I marker was placed just beyond aortic arch in descending thoracic aorta .Reconstructions performed in smooth kernel (B20f), Abdomen window, with overlapping axial image reconstruction (minimizes aliasing*

and stair step artefacts) on Multi Planar Reconstructions (MPR) that permits true 3 Dimensional renderings, and then transferring data to [Leonardo-CT, Siemens] workstation for 3D reconstruction and analysis. In all 64 patients, the spectrum of imaging findings was studied in cases of trauma with suspected arterial injuries and PAOD; while in cases where follow-up was possible, a comparison with intra operative surgical findings was done.

Results: Study comprised of 64 patients. There was a male preponderance with 40 (62.5%) males and 24 (37.5%) females with a male to female ratio of urban population (53%) was more commonly affected than the rural population (47%). Various risk factors found in studied cases were dyslipidemia (50%), systemic illnesses (43.75%) and smoking (40.63%). The most common age group was 41-60 years (36%) followed by 21-40 years (33%) and 61-80 years (20%). Lower limb (73.43%) was more commonly affected than the upper limb (26.56%). Analysis of diseases spectrum revealed that the most common form of the disease was thrombotic occlusion (31.25%) followed by traumatic occlusion (15.63%) and Takayasu's arteritis (7.81%).

Conclusion: Our study concludes that CT angiography using 64 slice-multi detector row CT is effective, quick, reliable, accurate and safe imaging modality for diagnosis and knowing severity of peripheral arterial disease.

Keywords: 64 Slice computerized tomography, Peripheral vascular diseases, Traumatic vascular injuries, Safe and Non invasive Imaging.

Introduction

The pursuit of faster scanning and higher resolution in volume scanning demanded the evolution of helical spiral CT to a take a technological quantum leap in the form of Multiple-row Detector CT Angiography (MDCTA)^[1]. Computed tomography angiography is increasingly attractive due to rapid technical developments. Shorter acquisition time, thinner slices, higher spatial resolution, and improvement of multidetector computed tomography (CT) scanners enable scanning of the whole vascular tree in a short period with a decreasing (but still substantial) amount of contrast medium^[2]. Recent studies on MDCTA report high sensitivity and specificity rates for detecting peripheral arterial disease^[3].

The common denominator of most conditions involving the arterial circulation in the extremities is the reduction or limitation of blood flow. In majority of situations, the perfusion available depends not only on the condition of the main artery but also on the extent to which collateral branches provide an alternate route for distal vessel reformation^[4]. In case of partial/ limited occlusive disease, there is no perfusion deficit at rest and symptoms only manifest when there is an increased demand, such as occurs with exercise. Occlusive lesions develop gradually, as in the case of an atherosclerotic plaque, so there is time for

parallel improvement in the function of the collaterals, and the patient may have no symptoms until there is advanced stenosis. Even progression to occlusion may produce only mild symptoms. On the other hand an acute occlusion, such as that produced by an arterial embolus, will result in much more severe symptoms because initially there is only limited contribution by collateral pathways^[5].

Peripheral vascular diseases can occur at single level or at multiple levels. The location of different stenosis will determine the distribution and severity of symptoms. Patients with arterial disease present with a wide range of signs and symptoms. Obtaining optimal results from noninvasive vascular testing requires familiarity of knowledge of normal anatomy and anatomic variants, as well as the different types of arterial pathology and their causes and effect with clinical correlation. Increased industrialization, urbanization and motorization of the society have definitely increased the incidence of acute trauma resulting in vascular^[6]. These developments have increased the need for angiography to screen patients with suspected arterial injury. The goals of diagnostic angiography are to document the presence or absence of vascular injury and secondarily to locate and characterize the injury and collateral circulation^[7].

Significant improvements in non-invasive computed tomography (CT) imaging have been observed during the past decade, and the reduced slice thickness and increased spatial resolution of 64-slice CT now afford the opportunity to non-invasively image the peripheral vessels [8]. It is hypothesized that the 64-slice generation of CT scanner may improve upon PAD (peripheral arterial disease) diagnostic accuracy and needs to be referenced with direct catheter based DSA (Digital Subtraction Angiography), which remains the gold standard [9]. However, MDCTA being Non-invasive imaging modality; it benefits patient care as vascular pathology is identified and treatment decisions are made with less risk to the patient and without unwarranted catheter angiography. Second, it affords more widespread vascular screening, allowing diagnoses to be made at an earlier stage and third non-invasive imaging can expand clinical volume while optimizing work efficiency in a busy academic or private practice [10].

Non-availability of comprehensive studies of Peripheral Arterial Disease (PAD) using advanced MDCTA techniques in population in and around Kolhapur, prompted us to undertake this study. An attempt was made to study the spectrum of imaging findings of Peripheral Arterial Disease in our area and usefulness of MDCTA in management of such patients.

Materials and Methods

The study was approved by institutional ethical committee. It was a prospective study carried out at an advanced diagnostic centre in an urban area. The duration of study was 2 years. The Cases comprised of patients referred to our institute for MDCTA who were suspected to have arterial injury following trauma, or sign and symptoms of peripheral arterial disease [PAD] of lower and upper extremity. Total 90 patients with suspicion of PAD underwent MDCTA with 64 Slice MDCT during study period. Out of these, 64 cases were included in our study group, while rest of 26 patients were diagnosed to have PAD but follow

up was lost in these cases and hence were excluded from the present study. All patients were scanned with 64 Slice multiple-row detectors CT (MDCT) (Somatom Sensation 64 Siemens Medical Solutions, Germany)

Patients were subjected to MDCTA after explaining the procedure and proper consent. Patients wherever possible were kept fasting for at least 3 hours prior to scanning. A detailed relevant medical history was taken and noted down. Patients renal function tests (serum creatinine) were obtained and if found to be within normal limits, scanning was performed; otherwise patients were rescheduled for taking appropriate measures. Similarly, hydration was maintained or pre and post contrast hydration was done with I.V normal saline (0.9%NS). All patients were scanned in supine position, with cotton clothes on with no metallic objects on the body surface (except in cases of fixators/splints/implants) with proper positioning of the Parts under examination. MDCTA was performed with a 64 slice multi detector row CT after intravenous injection of 100 cc of non-ionic, monomeric, tri-iodinated, water soluble X-ray contrast medium (Iohexol,350mg I/ml , omnipaque, GE Healthcare Ireland, Cork, Ireland) as a bolus dose (UNI phasic / BI PHASIC) at the rate of 3.5ml/sec with a pressure injector (Stellant, MEDRAD Inc,Pa,USA) through an intravenous (I.V.) catheter of 18G.

Patients were scanned in supine position with Collimation of 0.6 mm, pitch 1 , tube voltage (kV) 120, tube current (effective mAs)160, acquisition 2x32x0.6 mm , resolution <0.4mm, double z-sampling position (64 slices per rotation) with specific - scan range, specific coverage length and position. The R.O.I marker placed just beyond aortic arch in descending thoracic aorta.

Reconstructions performed in smooth kernel (B20f), Abdomen window, with overlapping axial image reconstruction (minimises aliasing and stair step artefacts) on Multi Planar Reconstructions (MPR) that permits true 3 Dimensional renderings, and then transferring data to

[Leonardo-CT,Siemens] workstation for 3D reconstruction and analysis; in Maximum Intensity Projections [MIP] and Volume Rendered Technique [VRT] images. The radiologists could manipulate the images in a near infinite number of projections with various amounts of time needed for review. Reconstructed images were stored on compact discs as well as for the purpose of the present study.

In all 64 patients, the spectrum of imaging findings was studied in cases of trauma with suspected arterial injuries and PAOD; while in cases where follow-up was possible, a comparison with intra operative surgical findings was done. Also wherever feasible, relevant clinical /intraoperative photographs, imaging and reports of the patient were taken. In few cases post interventional MDCTA was done where retrospective intervention success was confirmed while in others MDCTA findings helped in presurgical /intervention planning. Also post surgical bypass graft evaluation was done as Follow-up MDCTA, where in presurgical MDCTA findings were used as reference standard

as well as post bypass MDCTA outcome were evaluated for surgical success.

Results

In our study there were 64 patients who had peripheral arterial disease. Out of these 64 patients 40 (62.5%) were males and 24 (37.5%) were females with a M:F ratio being 1:0.6.

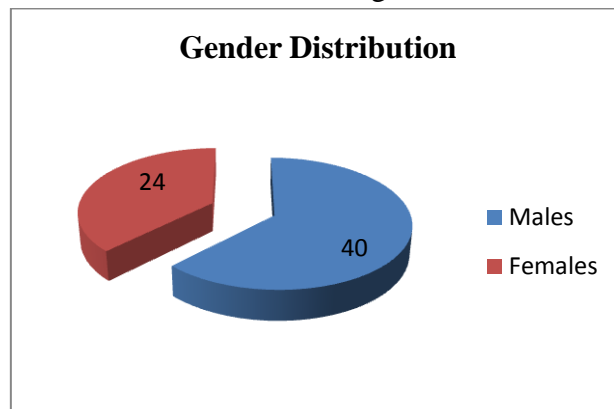


Figure 1 Gender Distribution of the studied cases
The analysis of studied cases revealed that 34 (53%) patients came from urban areas while 30 (47%) patients were hailing from rural areas. Peripheral arterial disease was found to be more common in urban population than the rural population.

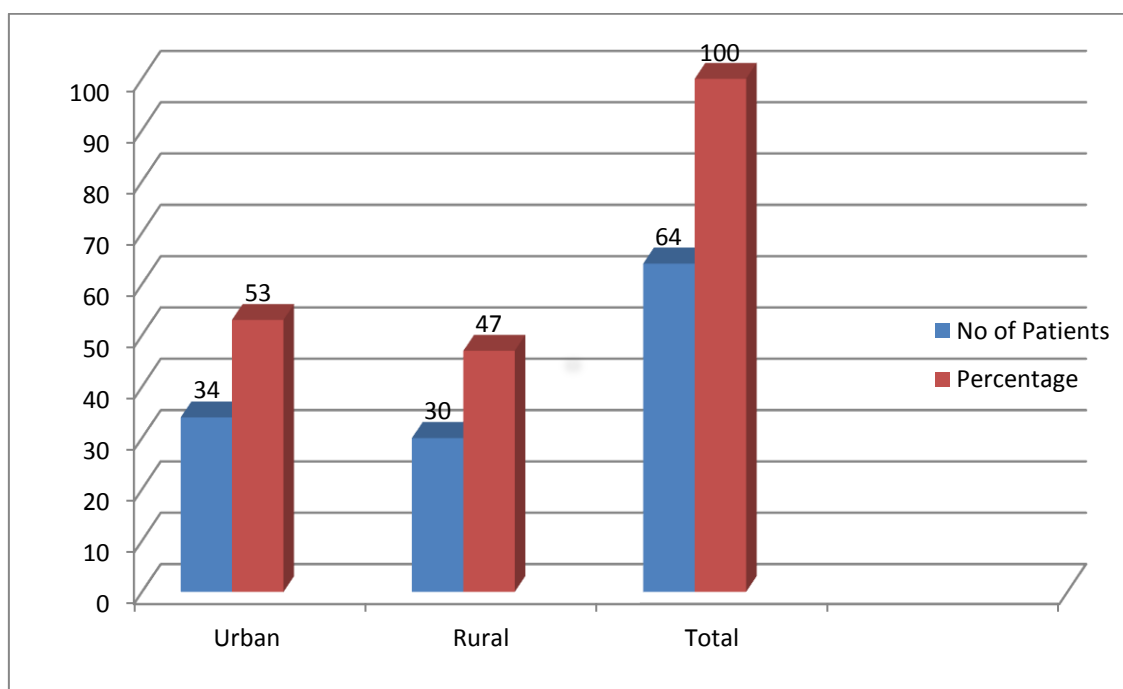


Figure 2: Rural /Urban population distribution of the studied cases

The analysis of risk factors for peripheral arterial disease showed that almost 50% of patients has

dyslipidemia making it the most common risk factor for development of peripheral arterial

disease. Other common risk factors seen in patients were systemic illnesses like diabetes and

hypertension, male gender, smoking and trauma.

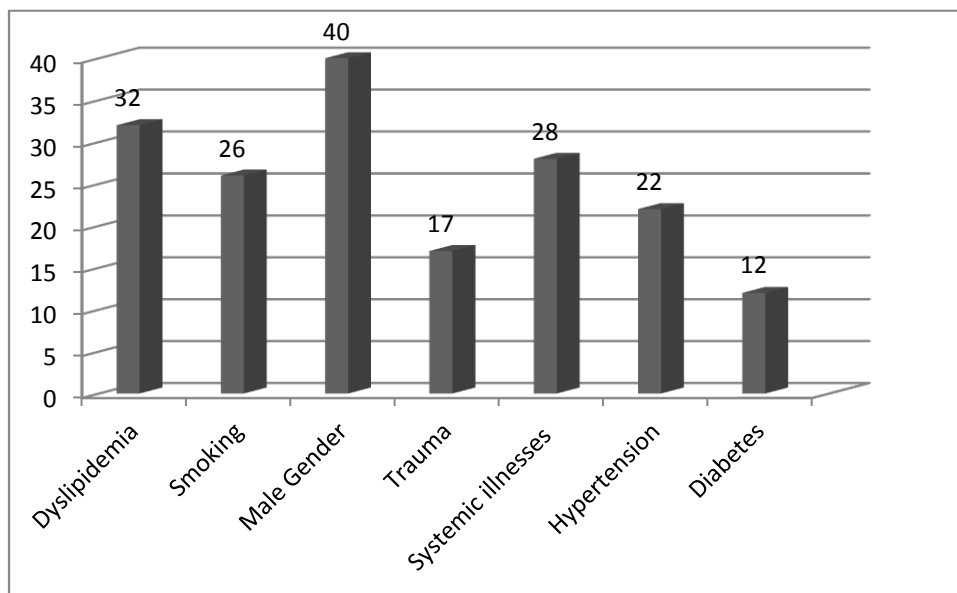


Figure 3: Risk Factors in patients with peripheral arterial disease.

The patients belonged to age group 6 years to 85 years. Most common age group to be involved in peripheral arterial disease was found to be 41-60

years (36%), followed by 21-40 years and 61-80 years.

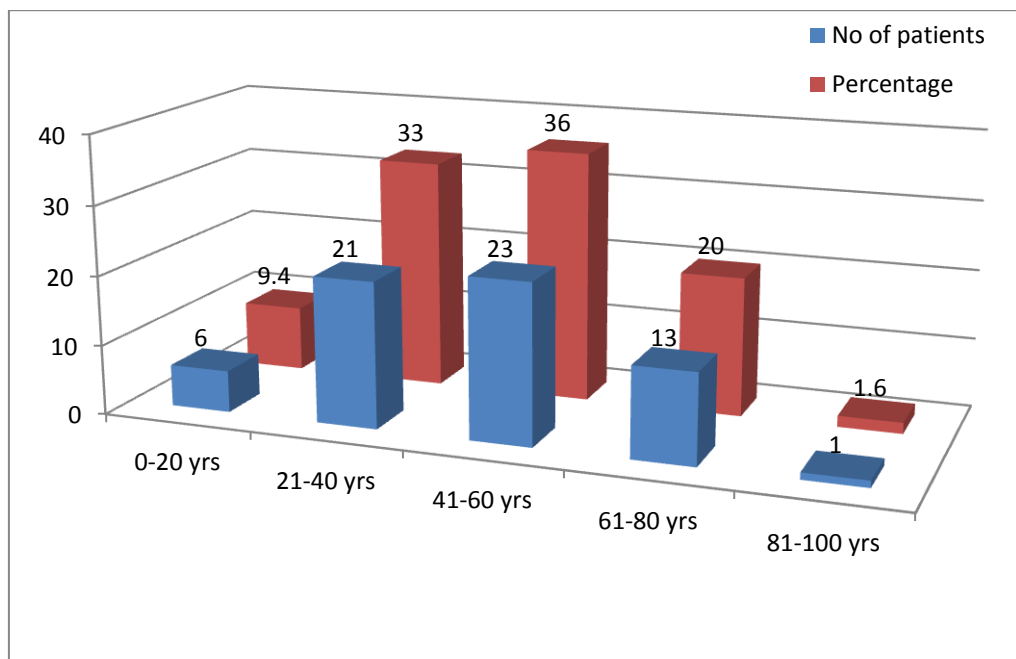


Figure 4: Age group involved in peripheral arterial diseases.

Lower limbs were predominantly affected by peripheral arterial disease. In our study 47 () patients had peripheral arterial disease affected

lower limbs and 17 () patients had upper limb peripheral arterial disease.

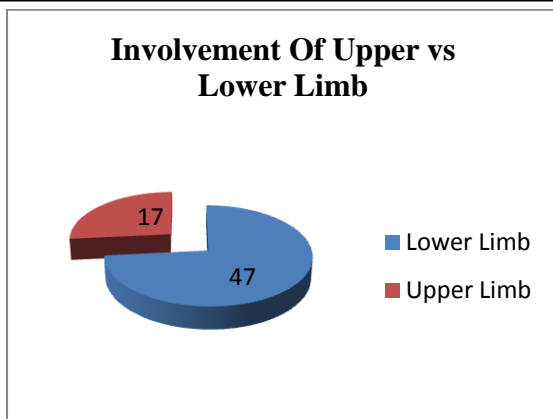


Figure 5: Involvement of upper limbs Vs lower limbs in patients.

The analysis of spectrum of the peripheral vascular diseases in our patients revealed that the most common etiology involved in PAD was thrombotic occlusion which was seen in 20 (31.25%) patients followed by traumatic occlusion (15.63%), Takayasu arteritis (7.81%) and thromboembolism (7.81%). The whole spectrum of peripheral arterial diseases encountered in our study is given below in tabulated form

Table 1 : Spectrum of peripheral arterial disease in studied cases.

PAD Spectrum	Cases	Percentage (%)
Traumatic occlusion	10	15.63
Takayasu arteritis	5	7.81
Iatrogenic Trauma	1	1.56
Atherosclerosis	4	6.25
Thrombotic occlusion	20	31.25
Pseudo aneurysm of Anterior tibial artery	1	1.56
Thrombo-Embolism	5	7.81
Thoracic outlet syndrome	2	3.13
Normal Peripheral angiography	5	7.81
Abdominal aortic aneurysm with PVD	1	1.56
Coarctation of aorta with PVD	1	1.56
Aortic dissection with PVD	1	1.56
Vascular stenosis	2	3.13
Leriches syndrome with PVD	2	3.13
Angiomatous lesion of Lower limb	1	1.56
Ectasia of Subclavian artery	1	1.56
Traumatic dissection of Brachial artery	1	1.56
Indentation over Popliteal artery due to avulsed fracture fragment	1	1.56
TOTAL	64	100

Discussion

Our study consisted of 64 patients all of whom underwent MDCT Peripheral Angiography with 64 Slice Multiple-row Detector CT (Somatom Sensation 64, Siemens Medical Solutions, and Germany) and were followed up. Average time required for each case varied from 10 to 15 minutes. All 64 patients had “good” diagnostic quality scans. The risk factors for PAD were Male sex, Dyslipidemia, systemic illness as well as Smoking. When risk factors coexist, the risk increased several-fold [11,12,13].

In the present study, out of 64 patients having PAD, 40 patients were MALE accounting for 62.5%, 32 patients were having dyslipidemia

accounting for 50%, followed by 28 cases & 26 cases were having systemic illness and history of smoking accounting for 43.75% & 40.63% respectively as PAD risk factors.

Patient’s age ranged from 6 yrs to 85 yrs in present study with maximum number of cases (23) being found in the age group of 41-60 yrs, accounting for 36% followed by 21 cases(33%) in the age group of 21-40 yrs. thus correlating with previous studies showing increase risk at age >50Y. Similar results were found in previous studies Framingham Study indicating increased risk after age of 50 with incidence of new cases about age 40years and prevalence of cases about age 50 years and above [14]. All patients underwent

CT angiography with 64 Slice multiple-row detectors CT (MDCT) (Somatom Sensation 64 Siemens Medical Solutions, Germany). Role of MDCT is well evaluated in many studies and it has been found to have acceptable detection rates in comparison to DSA^[15,16]. Though conventionally ultrasound with the aid of color Doppler is being used to detect peripheral arterial diseases but in many randomized controlled trials it is found that in comparison to ultrasound and Doppler arterial system MDCT angiography is significantly better statistically^[17]. Mishra et al concluded in their study that CT angiography with multirow MDCT scanner has clearly efficacious, fast, accurate, safe and non-invasive imaging modality of choice in peripheral arterial pathology particularly in trauma where a rapid diagnosis is critical to save the limb. They further recommended that MDCT can be useful in screening in cases of PAOD for diagnosis and grading^[18]. Moreover a multicentric randomized controlled trial by Ouwendijk R et al comparing the costs and effects of 3 noninvasive imaging modalities ie duplex sonography, CT angiography and MR angiography concluded that both CTA and MRA are clinically more useful than duplex sonography and that CTA is less costly than MRA and hence may be preferred in the initial imaging evaluation of peripheral arterial diseases^[19].

Even today the first investigation ordered in patients with peripheral vascular diseases in most of the cases is duplex ultrasound. Kayhan et al in their study of 774 cases compared the findings of imaging by duplex ultrasound and MDCT. They found that MDCTA could detect obstructed or stenotic lesions in 16.8% of arteries while duplex ultrasound could detect stenosis or obstruction in 11.1% patients. This difference was more in detection of obstruction or stenosis in infrapopliteal vessels (19.6% versus 11.3%) than in suprapopliteal region (15% versus 11%). Hence they concluded that MDCTA may be used as a screening tool in patients with PAOD since it is safe, non-invasive and more accurate than duplex ultrasound^[20].

Conclusion

Our study of CT angiography with a 64 slice-multi detector row CT has clearly demonstrated its efficacy as a promising new, fast, accurate, safe and non-invasive imaging modality of choice in cases of trauma with suspected arterial injuries and as a useful imaging modality in cases of peripheral vascular diseases for diagnosis, grading and potential usefulness in type of treatment planning as well as also in the follow-up of patients after treatment and intervention.

Conflict Of interest: None

References

1. Hu H. Multi-slice helical CT: scan and reconstruction. *Med Phys.* 1999 Jan;26 (1):5-18.
2. Yu L, Liu X, Leng S, et al. Radiation dose reduction in computed tomography: techniques and future perspective. *Imaging in medicine.* 2009;1(1):65-84
3. Pollak AW, Norton P, Kramer CM. Multimodality Imaging of Lower Extremity Peripheral Arterial Disease: Current Role and Future Directions. *Circulation Cardiovascular imaging.* 2012;5(6):797-807.
4. Olin JW, Sealove BA. Peripheral Artery Disease: Current Insight Into the Disease and Its Diagnosis and Management. *Mayo Clinic Proceedings.* 2010;85(7):678-692.
5. Fowkes FG, Housley E, Cawood EH, Macintyre CC, Ruckley CV, Prescott RJ. Edinburgh Artery Study: prevalence of asymptomatic and symptomatic peripheral arterial disease in the general population. *Int J Epidemiol.* 1991; 20(2):384-392
6. Criqui MH, Aboyans V. Epidemiology of peripheral artery disease. *Circ Res.* 2015 Apr 24;116(9):1509-26.
7. Walls MC, Thavendiranathan P, Rajagopalan S. Advances in CT

- angiography for peripheral arterial disease. *Cardiol Clin*. 2011 Aug;29(3):331-40.
8. Klingebiel R, Kentenich M, Bauknecht H-C, et al. Comparative evaluation of 64-slice CT angiography and digital subtraction angiography in assessing the cervicocranial vasculature. *Vascular Health and Risk Management*. 2008;4(4):901-907.
 9. Guthaner DF, Wexler L, Enzmann DR, Riederer SJ, Keyes GS, Collins WF, Brody WR. Evaluation of peripheral vascular disease using digital subtraction angiography. *Radiology*. 1983 May;147(2):393-8.
 10. Kock MCJM, Dijkshoorn ML, Pattynama PMT, Myriam Hunink MG. Multi-detector row computed tomography angiography of peripheral arterial disease. *European Radiology*. 2007;17(12):3208-3222
 11. Shammass NW. Epidemiology, classification, and modifiable risk factors of peripheral arterial disease. *Vascular Health and Risk Management*. 2007;3(2):229-234.
 12. riqui MH, Aboyans V. Epidemiology of peripheral artery disease. *Circ Res*. 2015 Apr 24;116(9):1509-26.
 13. Muir RL. Peripheral arterial disease: Pathophysiology, risk factors, diagnosis, treatment, and prevention. *J Vasc Nurs*. 2009 Jun;27(2):26-30
 14. Update on some epidemiologic features of intermittent claudication: the Framingham Study. Kannel WB, McGee DLJ *Am Geriatr Soc*. 1985 Jan; 33(1):13-8.
 15. Lijmer JG, Hunink MG, van den Dungen JJ, Loonstra J, Smit AJ. ROC analysis of noninvasive tests for peripheral arterial disease. *Ultrasound Med Biol*. 1996;22:391-398
 16. Bailey MA, Griffin KJ, Scott DJA. Clinical Assessment of Patients with Peripheral Arterial Disease. *Seminars in Interventional Radiology*. 2014;31(4):292-299.
 17. Kock MCJM, Dijkshoorn ML, Pattynama PMT, Hunink MGM. Multi-detector row computed tomography angiography of peripheral arterial disease. *European Radiology*. 2007;17:3208-3222.
 18. Mishra A, Bhaktarahalli JN, Ehtuish EF. Imaging of peripheral arteries by row multidetector computed tomography angiography: a feasible tool? *Eur JRadiol*. 2007 Mar;61(3):528-33. Epub 2006 Nov 22.
 19. Ouwendijk R Vries M, Stijnen T, Pattynama PM, Sambeek MR et al. Multicenteric randomized controlled trial of the costs and effects of non-invasive diagnostic imaging in patients with peripheral arterial disease. The DIPAD trial *AJR Am J Roentgenol* may 2008;190(5):1349-1357.
 20. Kayhan A, Palabiyik F, Serinsoz S et al. Multidetector Angiography versus arterial doppler USG in diagnosis of mild lower extremity peripheral diseases: Is a multidetector CT a valuable screening tool? *Eur J Radiol* 2012, Mar 81(3):542-6.