



Accuracy of Perfusion MRI in Differentiating Benign From Atypical and Malignant Meningiomas

Authors

Dr Rani Ann Joseph¹, Dr Manoj T Pillai², Dr Anusha Lingaiah Pujar³

¹Senior Resident, Department of Radiodiagnosis, Govt Medical College, Thrissur

²Associate Professor, Department of Radiodiagnosis, Government Medical College, Kollam

³Senior Resident, Department of Radiodiagnosis, District Hospital, Ballari

Corresponding Author

Dr. Rani Ann Joseph

28/13, Arch Road, Kuttanellur P.O, Thrissur, Kerala, India Pin- 680014

Email: annranij@gmail.com, Ph - 9895780985

Abstract

Aim: To study the diagnostic accuracy of Perfusion Magnetic Resonance Imaging in differentiating benign from atypical and malignant meningiomas and comparing with histopathology as the gold standard.

Methodology: 100 patients with intracranial meningiomas referred to the Department of Radiodiagnosis, for imaging were included in the study after applying inclusion and exclusion criteria. MR imaging of the head with Dynamic Susceptibility Contrast Perfusion Weighted Imaging was done. Maximal relative cerebral blood volume in the tumor – $rCBV(t)$ and in the peritumoral tissue – $rCBV(p)$ was calculated. Cut-off was obtained after drawing ROC $rCBV(t)$ and $rCBV(p)$.

Results and Interpretations: Perfusion weighted imaging in the peritumoral tissue can reliably differentiate between benign and atypical meningiomas. Using $rCBV(p)$ as the diagnostic test, present study shows a sensitivity of 90.48% and specificity of 98.73% ($p < 0.0001$).

Keywords- MRI, $rCBV(p)$, $rMTE(p)$, differentiation of typical and atypical meningiomas, perfusion.

INTRODUCTION

Meningiomas are the most common primary nonglial intracranial tumor. Meningiomas are commonly diagnosed in middle aged and elderly adults. They are mostly seen in females with a female-to-male ratio of about 2:1.¹ Most meningiomas are asymptomatic and are usually advised only routine follow up or treated by excision. However, certain histological subtypes of meningiomas have high rates of recurrence and adjacent brain invasion. Histologically, meningi-

omas are classified into benign, atypical and malignant varieties and these subtypes have different rates of recurrence and invasiveness.² Perfusion magnetic resonance imaging with dynamic susceptibility contrast is a new technique used to assess the vascularity of neoplasms. Blood vessels are more numerous in neoplasms when compared to normal brain parenchyma due to neovascularity and these tumor vessels have a larger volume. In general, higher grade tumors tend to have higher blood volume.^{3,4} Perfusion

MRI is being used to study the blood volume in CNS neoplasms by calculating the maximal relative cerebral blood volumes (rCBV). Present study was undertaken to assess the accuracy of measurement of perfusion parameter rCBV in both the tumor and the peritumoral tissue in differentiating benign from atypical and malignant meningiomas preoperatively and comparing with histopathology as gold standard.

AIMS AND OBJECTIVES

To study the diagnostic accuracy of perfusion weighted MRI in differentiating benign, from atypical and malignant meningiomas.

Objectives

- To study the sensitivity, specificity and other statistical parameters in the diagnosis of benign versus atypical and malignant meningiomas by Perfusion MRI and comparing with histopathology as gold standard.
- To derive logical cut off of maximal relative cerebral blood volume (rCBV) by ROC analysis for differentiating benign from atypical and malignant meningiomas.

METHODOLOGY

This cross sectional study was carried out in the Department of Radiodiagnosis, Government Medical College, Thiruvananthapuram for eighteen months from May 2014 to October 2015. 100 patients referred to the Department of Radiodiagnosis for MRI brain for the evaluation of suspected meningiomas diagnosed by CT brain and being planned for an incisional or excisional biopsy were included in the study.

Patients with pacemakers, cochlear implants, ferromagnetic foreign bodies or metallic implants, patients not willing to participate in the study and those patients with recurrent or residual meningioma following surgery were excluded from the study.

Name, age and relevant details of the patient was recorded on a proforma. Patients were informed that data collected would be used in a study and

that issues related to confidentiality and anonymity would be taken due care of.

After obtaining informed consent, MR examinations were performed on a 1.5T SIEMENS MAGNETOM system. Axial T1-weighted spin-echo, axial fluid attenuated inversion recovery (FLAIR) sequences, sagittal, axial and coronal T2WI images were acquired.

Table -1 Parameters used in MR imaging of brain

Parameters	T1WI	T2WI	DWI	FLAIR
TR (ms)	409	4000	3000	9000
TE (ms)	8.4	94	89	89
No. of excitations	1	3	4	1
FOV (cmxcm)	23x23	23x23	23x23	23x23
Slice thickness (mm)	5	5	5	5
Interslice gap (%)	30	30	30	30

0.1mmol/kg of meglumine gadoterate was injected manually, followed by a 10 ml saline flush. T2* weighted dynamic susceptibility contrast enhanced perfusion imaging was performed 5 s after the beginning of the injection using a gradient-echo echo-planar sequence with the following parameters: TR/TE 1410/30 ms, number of excitations 1, flip angle 90°, bandwidth 1502Hz/Px, number of sections 19, section thickness 5 mm with 30% spacing, 8–10 slices per acquisition, field of view 23 cm, and acquisition time 1.18 minutes. A series of 50 dynamic acquisitions were obtained for each section during the bolus injection of meglumine gadoterate. Then, postcontrast sagittal, coronal and axial spin-echo T1-weighted sequences were performed using the same section positions and parameters as the corresponding precontrast sequences.

The images were analyzed using Siemens Syngo Software (MMWP VE36A) and cerebral blood volume (CBV) maps were generated. A single region of interest including at least 20 pixels, was placed on the highest color levels of the solid part of the parenchyma and peritumoredema of a tumor, and the maximal values were recorded. Peritumoral tissue in this study was defined as areas of high signal in the adjacent brain

parenchyma on FLAIR images and within 1 cm of the outer enhancing tumor margin on post contrast T1-weighted images. For quantitative analysis, normal white matter within the contralateral hemisphere was used as the internal reference standard, and rCBV values were calculated by dividing the maximal CBV of the tumor by that of the contralateral normal white matter.

Study Variables:

- rCBV(t) – Maximal relative cerebral blood volume in the tumor
- rCBV(p) – Maximal relative cerebral blood volume in the peritumoral tissue

Tumors considered as the solid enhancing portion of the meningiomas, carefully avoiding the cystic areas.

Peritumoral tissue is considered as areas of high signal on FLAIR in the adjacent brain parenchyma and within 1cm of the outer enhancing tumor margin on post-contrast T1 weighted images.

After undergoing incisional or excisional biopsy in the Department of Neurosurgery, the histopathology report of the specimens were collected from the Department of Pathology.

Statistical analysis was performed with commercially available softwares (IBM SPSS statistics 22; Med Calc 15.10). The rCBV values were then correlated with the results of histopathological examination.

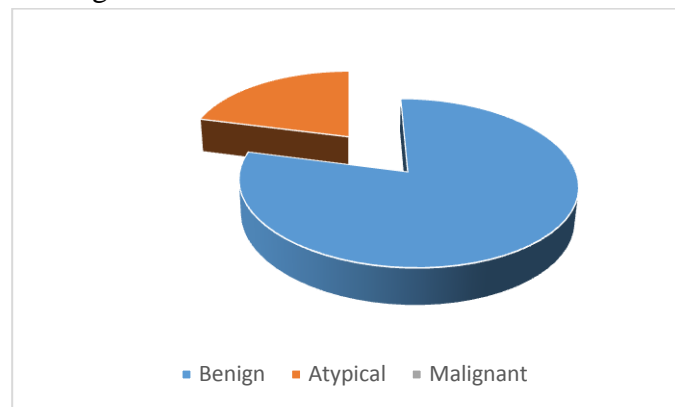
The means of the maximum rCBV values of benign and high grade meningiomas were expressed as means±standard error of the mean. The differences between the means of benign and high grade meningiomas were compared using an independent-samples *t*-test. With histopathology as gold standard, the receiver operating characteristic curves (ROC) and suitable cut off values were generated.

OBSERVATION AND RESULTS

Over a period of 18 months, total of 100 patients were included in the study. In these patients, post operative histopathological report was obtained. 21(21%) of the 100 meningiomas studied were atypical meningiomas, and 79(79%) were benign

meningiomas. None of the meningiomas studied were malignant meningiomas.

Figure 1 – Histopathological distribution of meningiomas



Evaluation of rCBV of peritumoral tissue

The maximal relative cerebral blood volume of the peritumoral tissue rCBV(p) were measured. The rCBV(p) of meningiomas ranged from 0.05 to 5.26.

Figure 2- Distribution of rCBV in peritumoral tissue

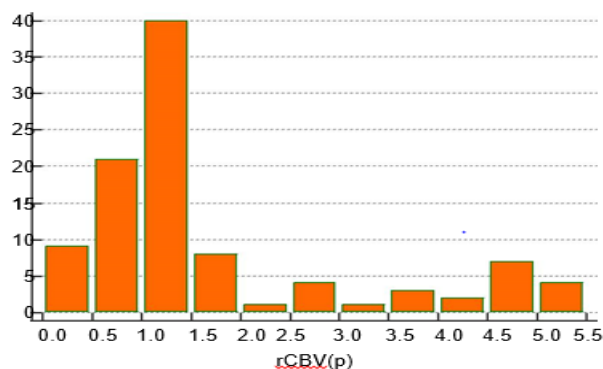


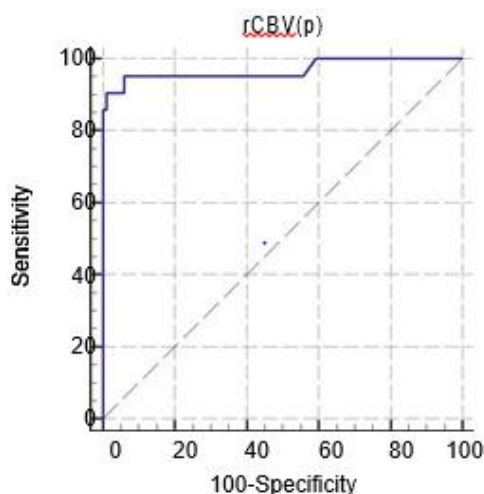
Table 2- statistical analysis of mean of rCBV in peritumoral tissue

Outcome	Number	rCBV(p)		T	P
		Mean	SD		
Benign	79	1.05	0.47	18	<0.0001
Atypical	21	4.04	1.17		

The mean and SD of rCBV in peritumoral tissue in benign meningiomas was 1.05 ± 0.47 , and in atypical meningiomas the mean rCBV of peritumoral tissue 4.04 ± 1.17 was significantly higher ($p < 0.0001$).

Receiver Operator Curve Analysis for rCBV in peritumoral tissue

Figure 3 – ROC Curve for predicting cut off for rCBV(p)



From the graph, a cut off value of 2.52 was derived. This cut off has a sensitivity of 90.48% and specificity of 98.73

Table 3 – 2x2 table with 2.52 as cut off for rCBV(p)

rCBV(p)	Atypical	Benign
>2.52	19	1
<2.52	2	78
Total	21	79

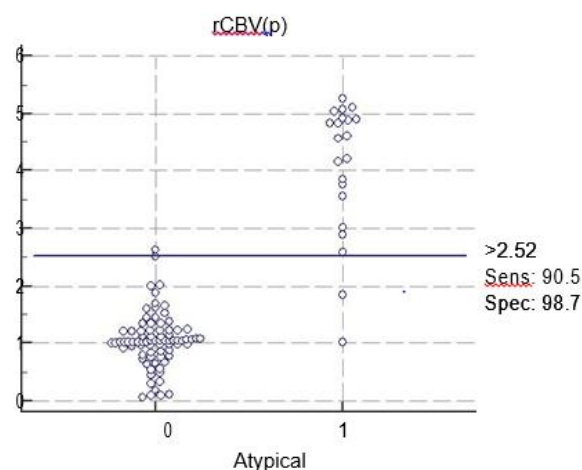
Table 4 Parameters obtained in ROC analysis of rCBV(p)

Area under the ROC curve (AUC)	0.969
Standard Error	0.0276
Z statistic	16.9777
95% Confidence interval	0.913 to 0.993
Significance level P (Area=0.5)	<0.0001
Youden Index J	0.8921
Associated Criterion	>2.52

Table 5 – Statistical indices with 2.52 as cut off for rCBV(p)

Statistical index		95% CI
Sensitivity	90.48%	69.6-98.8
Specificity	98.73%	93.1-100
Positive predictive value	91.8%	63.9-99.7
Negative predictive value	98.5%	93.2-99.9
Positive likelihood ratio	71.48	10.1-503.6
Negative likelihood ratio	0.096	0.03-0.4

Figure 4 – Scatter diagram showing distribution of rCBV(p)



Evaluation of rCBV in the tumor- rCBV(t)

The maximal relative cerebral blood volume within the tumor was measured. The rCBV(t) ranged from 2.1 to 12.

Figure 5 Distribution of rCBV within the tumor.

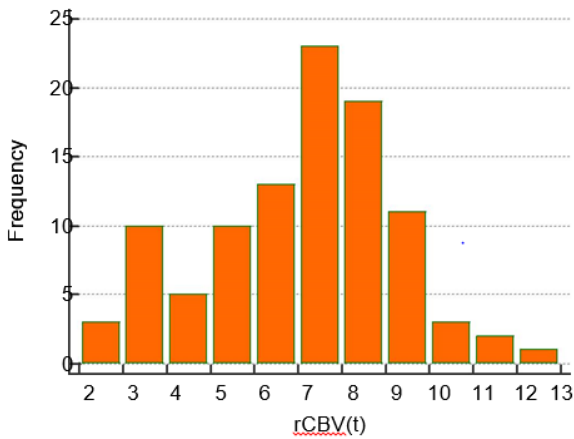


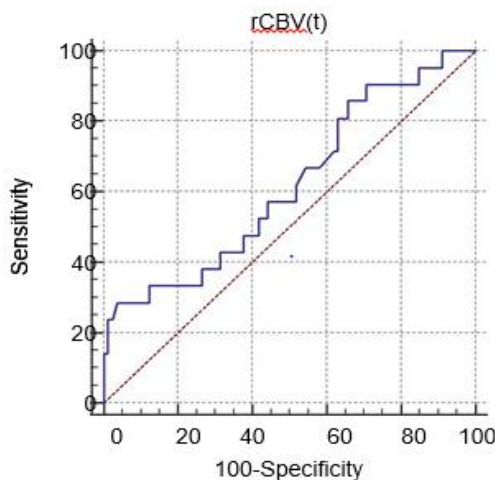
Table 6 - Statistical analysis of rCBV within the tumor rCBV(t)

Outcome	N	rCBV(t)		t	P
		Mean	sd		
Benign	79	7.36	1.97	2.151	.034
Atypical	21	6.26	2.44		

The mean and SD of intratumoral rCBV in grade-1 meningioma was 7.36 ± 1.97 , and in high grade meningiomas the mean intratumoral rCBV 6.26 ± 2.44 was significantly lower ($p < 0.034$).

Receiver Operator Curve Analysis for Intratumoral rCBV of meningiomas

Figure 6 – ROC Curve for predicting Cut off for rCBV(t)



From the graph, a cut off value of 3.78 was derived. This cut off has a sensitivity of 28.57% and specificity of 96.20%. Positive predictive value with this cut off is 54.2% and negative predictive value is 89.5%. However, the p value is 0.106, hence, the finding is not statistically significant.

Table 7 – Parameters obtained in ROC analysis of rCBV(t)

Area under the ROC curve (AUC)	0.617
Standard Error	0.0722
Z statistic	1.615
95% Confidence interval	0.514 to 0.712
Significance level P (Area=0.5)	<0.1065
Youden Index J	0.2477
Associated Criterion	≤ 3.78

Table 8 2x2 table with 3.78 as cut off for rCBV(t)

rCBV(T)	High Grade	Grade-1
≤ 3.78	6	3
> 3.78	15	76
Total	21	79

DISCUSSION

Differentiation of benign meningiomas from atypical and malignant meningiomas is helpful in planning accurate treatment. Since, intracranial meningiomas are usually inaccessible to clinical examination, imaging plays an important role in pre-operative evaluation of meningiomas.

In this study, perfusion weighted imaging were correctly used to differentiate benign from atypical meningiomas. The mean rCBV in peritumoral tissue in grade-1 meningiomas was 1.05 ± 0.47 and in high grade meningiomas was

4.04 \pm 1.17 (p value <0.0001). the optimal cut off of rCBV in the peritumoral tissue for differentiating benign from atypical meningiomas is 2.5 with a sensitivity of 90.48% and specificity of 98.73% (p value<0.001).

The intratumoral rCBV cut off for differentiating benign from atypical meningiomas was obtained was 3.78 with a sensitivity of 28.5% and specificity of 96.2%. But the p value was <0.1065, hence, the finding is not statistically significant.

S. Chedia et al in their study “Differentiation between benign and malignant meningiomas using diffusion and perfusion MR imaging” published in 2011 found that The differences in rCBV between benign and malignant meningiomas were not significant (P>0.05) in the parenchyma, but were significant (p< 0. 05) in the peritumoral edema.⁵

LIMITATIONS OF THE STUDY

- 1) The study sample might not be true representative of the real world due to “sampling errors” and spectrum bias.
- 2) Inoperable cases of meningiomas had to be excluded from the study.
- 3) None of the meningiomas studied were malignant meningiomas. Hence, the findings may be different in malignant meningiomas.
- 4) Contrast was injected manually in the present study. Hence, rate of flow of contrast and saline flush couldn't be accurately controlled.

Figure 7– rCBV map of HPR- Benign meningioma of the falx.

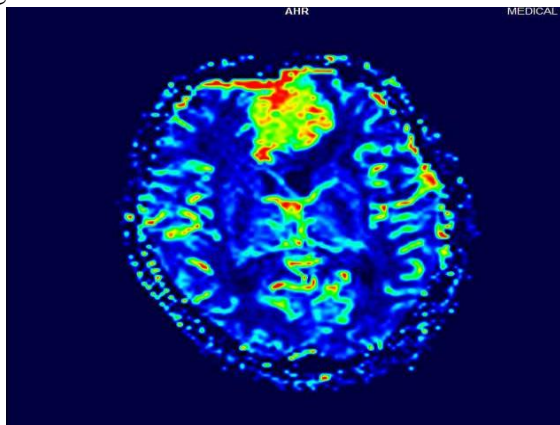
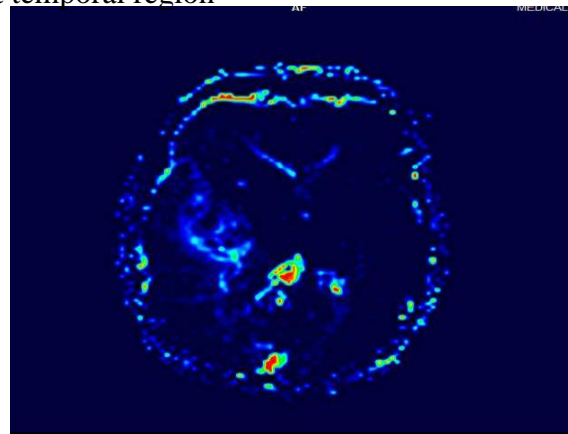


Figure 8 – rCBV map of grade-2 meningioma of right temporal region



CONCLUSION

Perfusion weighted MRI with measurement of rCBV values in the peritumoral tissue can be reliably used to differentiate benign from atypical meningiomas

Thus, perfusion MRI is a helpful adjunct to conventional MRI for preoperative characterisation of meningiomas and for further treatment planning.

REFERENCES

1. Mahesh V Jayaraman, Jerrold L Boxerman. Adult brain tumors. In: Scott W Atlas. Magnetic Resonance Imaging of the brain and spine. 4th edition. Philadelphia: Lippincott Williams &Wilkins ; 2009.
2. Markus J Riemschneider, Arie Perry, Guido Reifenberger. Histological classification and molecular genetics of meningiomas. Lancet Neurol 2006; 5: 1045–54. Available from - www.sciencedirect.com/science/article/pii/S1474442206706251
3. Walker C, Baborie A, Crooks D, et al. Biology, genetics and imaging of glial cell tumours. Br J Radiol.2011;84 Spec No 2:S90-106.
4. Jain RK, di Tomaso E, Duda DG, et al. Angiogenesis in brain tumours. Nat Rev Neurosci. 2007; 8:610-622.

5. S. Chedia, M. Gagua, N. Kbilashvili; Kutaisi/GE. Differentiation between benign and malignant meningiomas using diffusion and perfusion MR imaging. 10.1594/ecr2011/B-212. Available from www.myESR.com