



Original Article

Pattern of Peripheral Lymphadenopathies in Fine Needle Aspiration Cytology at Tertiary Centre: Two Years Experience

Authors

**Dr Ashok Panchonia¹, Dr Harshul Patidar², Prof. Dr C.V. Kulkarni³,
Dr Sweta Tripathi⁴**

Department of Pathology, M.G.M. Medical College & M.Y. Hospital, Indore (M.P.), India

Corresponding Author:

Dr Harshul Patidar

Email: harshul.patidar@gmail.com

Abstract

Background: Peripheral lymphadenopathy is commonly due to infectious or benign disease, but it could be a feature of underlying malignancy. Fine needle aspiration cytology (FNAC) is a simple, rapid and cost effective method that can be used as reliable diagnostic modality.

Objective: The present study was done to evaluate etiological pattern of peripheral lymphadenopathies and distribution with the respect to the age, sex & site.

Material and Methods: The present study was conducted in the Department of Pathology, M.G.M. Medical College Indore, from October 2013 to September 2015. Total 795 cases were studied. Aspirations were done by using 20 ml syringe and 22/24 gauge needles. Smears were stained with Papanicolaou stain.

Results: Out of 795 cases, 396 were males and 399 were females with age range from 1 year to 80 years. Maximum number of cases 221 (27.8%) were in the age group of 21 to 30 years. Most common lesion was tuberculous lymphadenitis (36.9%) followed by reactive hyperplasia (26.4%), acute suppurative lymphadenitis (15.1%), metastatic carcinoma (14.8%), chronic granulomatous lesion (5.9%) and lymphoma (0.9%).

Conclusion: FNAC is very useful diagnostic modality for peripheral lymphadenopathies. It can distinguish inflammatory from malignant lesion so that unnecessary surgery can be avoided.

Keywords: Peripheral lymphadenopathy, Fine needle aspiration cytology, tuberculous lymphadenitis.

INTRODUCTION

Lymphadenopathy is one of the common clinical presentations of patients attending the outdoor department. The etiology varies from an inflammatory to a malignant condition. [1] Seventy-five percent of all peripheral lymphadenopathies are localized, with more than 50% being seen in the head and neck area. Cervical

lymph nodes are involved more often than the other lymphatic regions. [2] Tuberculosis is the commonest cause of lymphadenopathy in developing countries, like in our country India, in young age group populations. In old age group, metastatic lymphadenopathy is commonest cause. [3]

Gold standard test for diagnosis of the lesion is surgical biopsy. But it is costly, time consuming, and requiring more precautions. Fine-needle aspiration cytology (FNAC) does not have any of these limitations, and is also comparatively less invasive. [4] De May has compiled the advantages of FNAC with the acronym SAFE means Simple, Accurate, Fast & Economical. [5] FNAC of lymphadenopathies has become essential part of initial diagnosis and management of patient. [6]

MATERIAL AND METHODS

The study consists of 795 patients with palpable peripheral lymphadenopathies coming to the Department of Pathology at M.Y. Hospital, Indore. The period of study was two years, from October 2013 to September 2015. A brief clinical history with findings of physical examination was noted. Fine needle aspiration was done by using 20 ml syringe and 22/24 gauge needles. Smears were wet fixed with 95% ethanol and stained with Papanicolaou stain.

RESULTS

The present study included 795 cases of patients with peripheral lymphadenopathies from various departments as an OPD as well as IPD patients. Age of the patient's range from 1 year to 80 years in which 49.8% were males and 51.2% were females.

Figure 1 shows site wise distribution of lymph node involvement, among which maximum

numbers of cases of cervical region 740 (93.1%), followed by axillary region 31 (3.9%) and inguinal region 24 (3.0%).

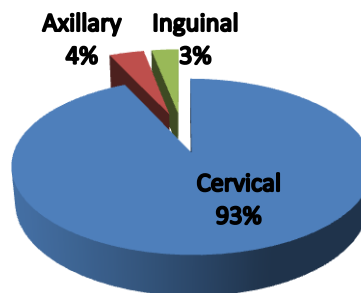


Figure 1: Site wise distribution of cases

Table 1 shows age and gender wise distribution. Maximum number of cases 221 (27.8%) were in the age group of 21 to 30 years. Out of 795 cases, tuberculous lymphadenitis was the predominant cause of lymphadenopathy, constituting 293 cases (36.9%) followed by reactive hyperplasia in 210 cases (26.4%).

Tuberculous lymphadenitis was most common in second and third decades (61.1%) while reactive hyperplasia in first three decades (85.2%).

Metastatic carcinoma was most common cause of lymphadenopathy after the age of 40 years (49.5%). Among metastatic carcinoma, squamous cell carcinoma was predominant 112 cases (95%) followed by adenocarcinoma 6 cases (5%).

Table 1: Distribution of cases according to Age and Gender

Age Group (yrs)	Tuberculous lymphadenitis		Reactive hyperplasia of lymph node		Acute suppurative lymphadenitis		Chronic granulomatous lesion		Metastatic squamous cell carcinoma		Metastatic Adeno-carcinoma		Hodgkin's lymphoma		Non Hodgkin's lymphoma		Total
	M	F	M	F	M	F	M	F	M	F	M	F	M	F	M	F	
0-10	17	09	24	14	04	02	01	01	00	00	00	00	00	00	00	00	72
11-20	28	57	31	42	08	17	04	06	00	01	00	00	00	00	01	00	195
21-30	31	63	29	39	10	25	07	13	01	02	00	00	00	00	01	00	221
31-40	21	26	07	08	16	04	02	02	08	02	00	00	00	00	01	00	97
41-50	8	14	04	02	09	04	03	02	28	06	03	01	01	00	01	00	86
51-60	05	04	04	03	07	03	04	00	26	08	01	00	00	00	01	00	66
>60	02	08	01	02	10	01	01	01	23	07	01	00	00	00	01	00	58
	112	181	100	110	64	56	22	25	86	26	05	01	01	00	06	00	795

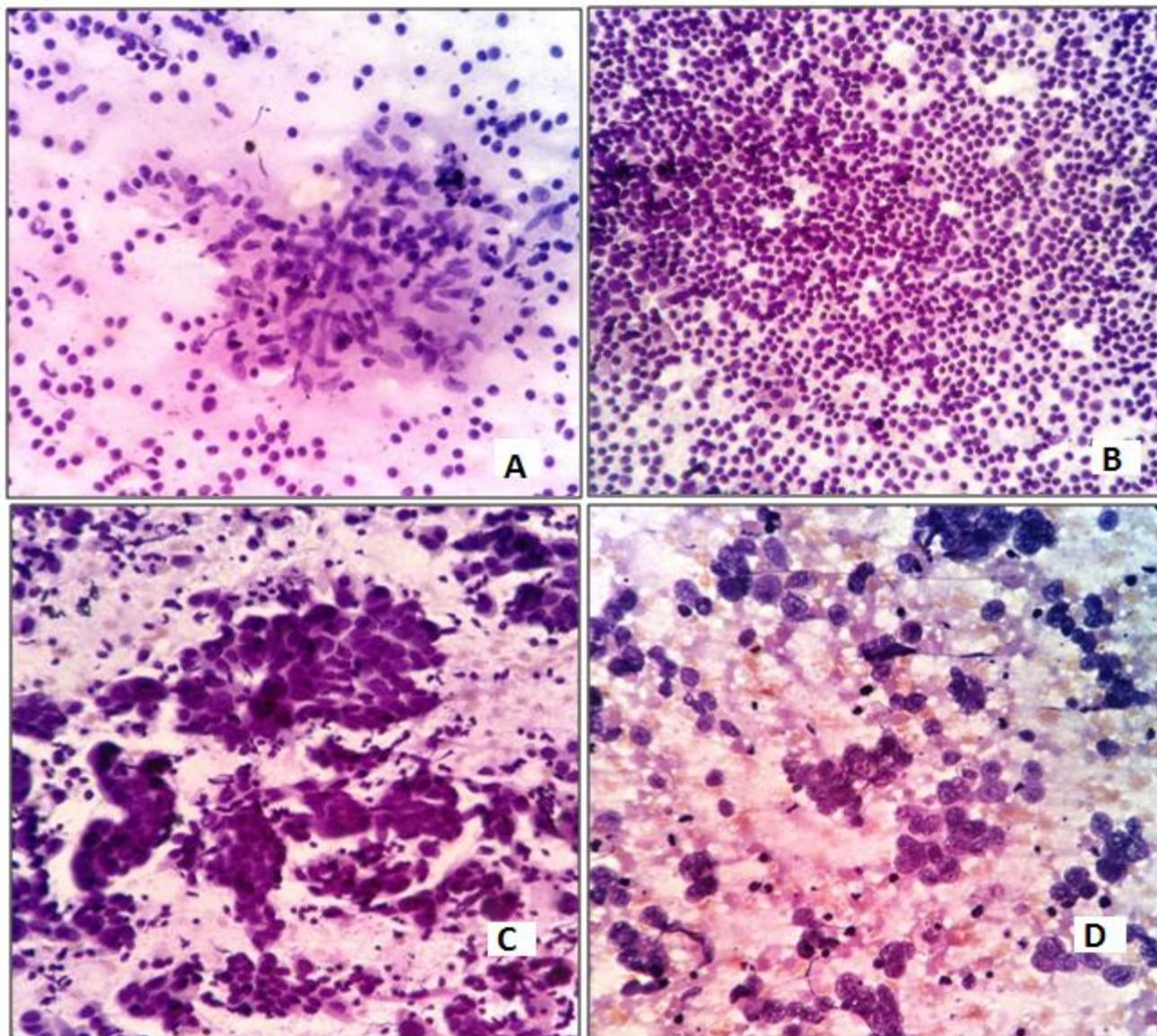


Figure 2 shows Pap stained lymphadenopathy FNA smear: A: Tuberculous Lymphadenitis; B: Reactive Hyperplasia; C: Metastatic Squamous Cell Carcinoma; D: Metastatic Adenocarcinoma.

DISCUSSION

FNAC of lymphadenopathy is of extremely significance because spectrum of underlying pathological process varies from infectious or benign disease to malignancy and on the basis of cytological diagnosis essential treatment protocol can be started at the earliest.^[7]

This study shows the experience of two years with 795 cases of peripheral lymphadenopathies. In our study pattern varied from inflammatory lesions like tuberculous lymphadenitis, reactive hyperplasia, acute suppurative lymphadenitis and chronic granulomatous lesion to malignant lesions like metastatic carcinoma and lymphoma.

In our study age group ranged from 1 year to 80 years with maximum cases in the age group of 21-30 years, results were comparable with Shah PC et al^[8], Shlipa G et al^[9] and Patel MM et al^[10].

Most common group of lymph nodes involved were of cervical region (93%) followed by axillary and inguinal region lymph nodes, findings were comparable with Shah PC et al^[8], Shlipa G et al^[9], Shrivastav et al^[11], Khajuria et al^[12] and Mohanty R et al^[14].

In our study most common diagnosed lesion was Tuberculous Lymphadenitis (36.9%), findings were comparable with Shah PC et al^[8], Shlipa G

et al ^[9], Wahid FI et al ^[13] and Kumar N et al ^[4]. In developing countries tuberculous lymphadenitis is one of the commonest causes of lymphadenopathy especially in the young adults and middle-aged patients. ^[11] However, Gayathri MN et al ^[7] and Shrivastav et al ^[11] found reactive hyperplasia as most common lesion. The difference in the results may be due to different study population and major numbers of patients in our hospital are of low socio-economic status.

Metastatic carcinoma constituted most common cause of lymphadenopathy after 40 years of age, 104 cases out of 210 cases (49.5%). Similar findings were also observed by Shrivastav et al ^[11]. Among metastatic carcinoma, most common was squamous cell carcinoma 112 cases (95%). The results were comparable with Shah PC et al ^[8], Shrivastav et al ^[11], Babu GS et al ^[15] and Alam K et al ^[16]. Higher incidence of metastatic squamous cell carcinoma is attributed to malignancies of upper aero-digestive tract, possibly because of bad habit of tobacco chewing.

CONCLUSION

FNAC is a simple, rapid and cost effective diagnostic tool for differentiating inflammatory from malignant lesions. Most common cause of lymphadenopathy in our setting was tuberculous lymphadenitis followed by reactive hyperplasia. Thus unnecessary surgery can be avoided with help of FNAC in inflammatory lesions.

ACKNOWLEDGEMENTS

I would like to thank for the guidance and support of my HOD Prof. Dr. C.V. Kulkarni Sir, faculty members and our technical staff. Financial support and sponsorship are Nil. There are no conflicts of interest.

Funding: None

Competing interest: None declared.

REFERENCES

1. Pandit AA, Candes FP, Khubchandani SR. Fine needle aspiration cytology of lymph nodes. *J Postgrad Med* 1987;33:134-6.
2. Mohseni Sh, Shojaiefard A, Khorgami Z, Alinejad Sh, Ghorbani A, Ghafouri A. Peripheral Lymphadenopathy: Approach and Diagnostic Tools. *Iran J Med Sci Supplement* March 2014; Vol 39 No 2.
3. Gupta AK, Nayar M, Chandra M. Critical appraisal of fine needle aspiration cytology in tuberculosis. *Acta cytol*.1992;36:391-94
4. Kumar N , Gupta BB, Sharma B, Kaushal M, Rewari BB, Sundriyal D. Role of fine needle aspiration cytology in human immunodeficiency virus-associated lymphadenopathy: a cross-sectional study from northern India. *Hong Kong Med J*. 2015;21(1):39-44.
5. Wu M, Burstein DE. Fine needle aspiration. *Cancer Invest* 2004;22:620-8.
6. Keith VE, Harsharan SK, Jerald GZ. Fine needle aspiration biopsy of lymph nodes in the modern era: reactive lymphadenopathies. *Pathol Case Rev* 2007;12(1):27-35.
7. Gayathri MN et al. Pattern of lymphadenopathy in fine needle aspiration cytology: a retrospective study. *Int J Res Med Sci*. 2015 Jun;3(6):1416-1419.
8. Shah PC et al. Evaluation of peripheral lymphadenopathy by fine needle aspiration cytology: a one year study at tertiary centre *Int J Res Med Sci*. 2016 Jan;4(1):120-125.
9. Shilpa G, Nataraju G. Pattern of Lymph Node Diseases in a Tertiary Level Referral Center: a cytological study of 943 cases. *International Journal of Biological and Medical Research*. 2013;4(3):3448-52.
10. Patel MM, Italiya SL, Patel RD, Dudhat RB, Kaptan KR, Baldwa VM. Role of Fine Needle Aspiration Cytology to Analyze Various Causes of Lymphadenopathy. *Natl J Community Med*. 2013;4(3):489-92.
11. Shrivastav et al. Evaluation of peripheral lymphadenopathy by fine needle aspiration cytology: A three year study at tertiary center. *Journal of Dr. NTR University of Health Sciences* 2014;3(2) 86-91.

12. Khajuria R, Goswami KC, Singh K, Dubey VK. Pattern of lymphadenopathy on fine needle aspiration cytology in Jammu. JK Sci 2006;8:157-9.
13. Wahid FI, Rehman H, Khan Q, Shahabi IK. Diagnostic value of fine needle aspiration cytology in diagnosis of non-thyroidal neck mass. JPMI. 2010;24(4):289-94.
14. Mohanty R, Wilkinson A. Utility of Fine Needle Aspiration Cytology of Lymph nodes. IOSR Journal of Dental and Medical Sciences. 2013;8(5):13-8.
15. Hiremath SS, Murgud S. Cytohistopathological evaluation of the cervical lymph nodes by fine needle aspiration cytology. Journal of Cranio-Maxillary Diseases. 2014;3(2):101-5.
16. Alam K, Khan AH, Siddiqui FA, Jain A, Haider N. Fine Needle Aspiration Cytology (FNAC), a handy tool for metastatic lymphadenopathy. The Internet Journal of Pathology 2010;10. Available from:
http://www.ispub.com/journal/the_internet_journal_of_pathology.