



## A New Concept for Disimpaction of Vertically Impacted Mandibular Third Molars

Authors

**Dr Shajah Hussain Sheikh, Dr Shaista Rehman**

GDC Jammu

### Abstract

*Vertically impacted mandibular third molars. Are they really difficult than mesio and horizontally impacted teeth while dis impaction.*

**Keywords:** *vector of force, purchase point, mechanical advantage, path of withdrawal, mandibular fracture, Cross bar elevator.*

### Introduction

Third molar surgery corresponds to a significant portion of the surgical procedures carried out by oral and maxillofacial surgeons around the world and is an important activity at dental surgery training centers<sup>1,2</sup>.

The difficulty indices so far given in the literature for mandibular third molar impactions are very much confusing and have flaws and drawbacks. George Winter in 1926 after his exhausting work gave the concept of war lines. His focus was much on red line. Red line a “conundrum” a concept beyond its expiry date<sup>3</sup>.

Then Pedersons difficulty index has also so many drawbacks. Is padersons index really a true index<sup>4</sup>. Really not. Various indexes have been proposed and are used by clinicians to classify the difficulty of extraction of lower third molar. The Pederson index can be utilized for difficulty evaluation before extraction. However, it is not widely used because it often incorrectly identifies a case as difficult<sup>5</sup>.

As per paderson and other authors difficulty scoring for mesioangular is one, horizontal is two, vertical is three, and distoangular is four. As per my experience under same circumstances vertical should be easiest among all. A postoperative index modified Parant scale is considered to be a better alternative to the Pederson scale in terms of accuracy and ease of application<sup>6</sup>. But it also shares similar problems that it does not account for clinical and radiological parameters (root number and morphology)<sup>7</sup>

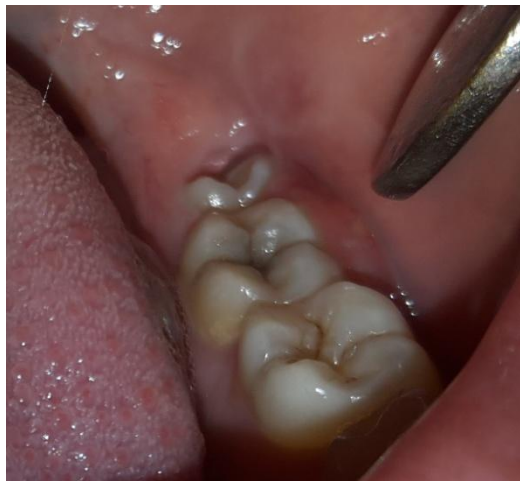### Material and Methods

A prospective cohort study was carried out involving patients submitted to at least 1 surgical intervention for the removal of a vertically impacted lower third molar between January 2016 to September 2017. Fifty patients who voluntarily sought treatment for the removal of impacted lower third molars were preselected. All patients were examined by a single practitioner. All fifty fulfilled the eligibility criteria (indication

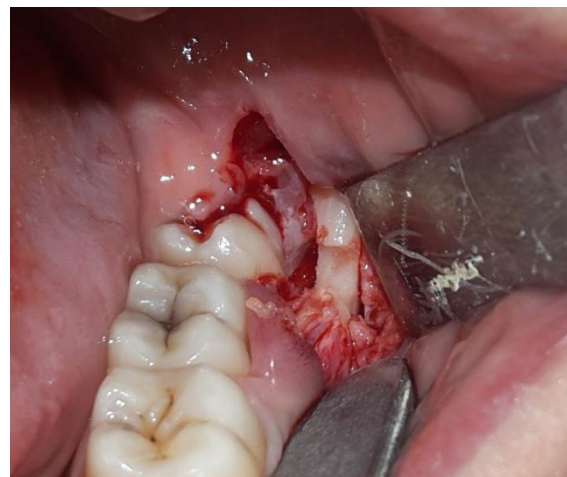for the surgery under local anesthesia and categories I and II of the American Society of Anesthesiology, i.e ASA I and II), and some patients were excluded based on the exclusion criteria (, systemic and/or behavior disorder that rendered local anesthesia unviable, pregnant or lactating women, recent irradiation, cognitive impairment that rendered the comprehension of the study objectives impossible, and non acceptance of the methodology). All patients signed terms of informed consent.

Fifty patients with vertically impacted mandibular third molars were operated so far in the department of oral and maxillofacial surgery government dental college Jammu with this technique. Thirty patients were female and twenty

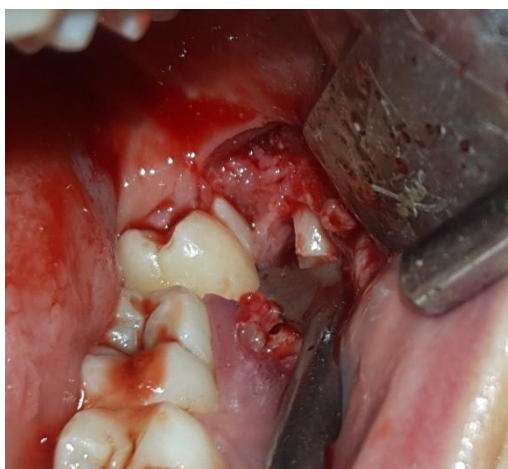were male patients. Triangular incision was given. Then buccal guttering up to cemento enamel junction was done both buccally as well as distally with sparing of disto lingual plate. Then purchase point was made using straight round bur on the buccal aspect of third molars. The purchase point was made such that it is at equal level or very slightly below the fulcrum. In case of position b or position c the buccal bone was reduced deep up to the purchase as shown in figure 1, so that their position is at the equal level. Then cross bar was engaged into the purchase point such that while rotating the vector of force is along the path of withdrawal. By this way there is compressive force at the fulcrum rather than tensile so there is least chance of fracture of mandible.



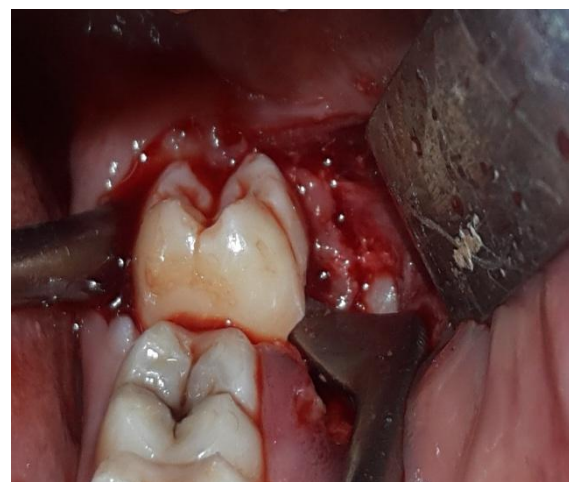Vertically impacted third molar



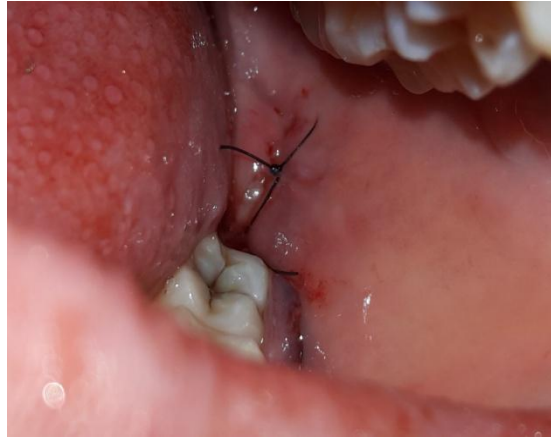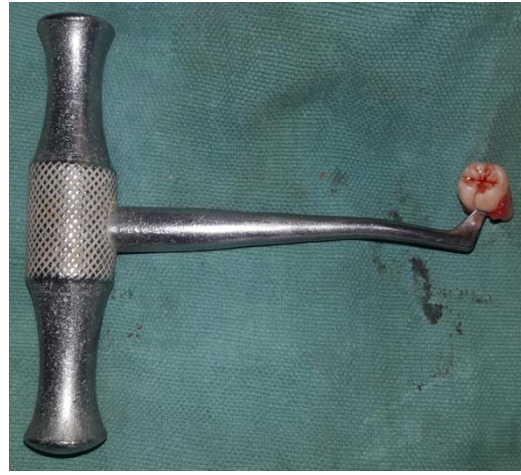
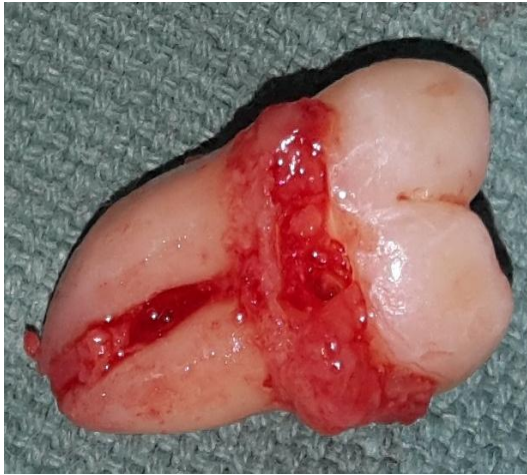buccal gutter with deepened fulcrum



Cross bar engaged



tooth elevated in toto



Closure

### Discussion

Direction of vector of force is the most important factor while extracting any tooth particularly third molars; the reason being inaccessible location of third molars. Though mandible is strong to resist fracture but in case of impacted third molars after guttering, it becomes weak. And the vector of force if not in the direction of path of withdrawal may lead to fracture. Feared of fracture mandible due to excessive force generation, many surgeons have abandoned the practice of using cross bar elevator. It is not the cross bar which is to be blamed. Cross bar elevator works on the basis of wheel and axle principle and most of the authors explain it in terms of mechanical advantage. Mechanical advantage does not mean in terms of force only it gives the ideal vector of force that is along the path of withdrawal. Undoubtedly there is excess force generation by cross bar but it is not the only variable. Vector of force matters more than magnitude in case of mandibular fracture. It is the tensile force than compressive which is

more dangerous, as experimented by Schamphy et al.

By putting the cross bar or any elevator in the buccal gutter; mandible potentially splits sagittally that is buccal plate splays buccally and lingual plate lingually by tensile force. We can change this tensile force into compressive force by changing the location of purchase point and fulcrum. If fulcrum is at the level or below the purchase point there is least chance of fracture of mandible. By using cross bar elevator we can use more force to extract it without sectioning or without excessive bone cutting. By this practice there is less post-operative morbidity in terms of nerve injury, post-operative edema and trismus. Before sectioning the first choice should be to elevate the tooth in toto by doing buccal and distal guttering up to cementonamel junction and then make purchase point on the buccal aspect of the tooth either at or just little below the fulcrum. Then carefully elevate it using cross bar elevator.

By using cross bar surgeon should be familiar with the vector of force that means the force should be such that its vector should be more towards occlusal and little lingual which is possible if purchase and lever location is placed as stated above else force will split more of buccolingually which will cause sagittal split as happens commonly in case of mandibular fracture. Vertically impacted third molars have been considered most difficult tooth after distoangular. The order being distoangular followed by vertical followed by horizontal and the last being mesioangular. If the above principle is followed then vertical will be most easy among all. Here again it is due to incompatibility between vector of force and path of withdrawal. As mentioned above use cross bar in vertical impacted purchase and lever should be either at the same level or purchase little below the fulcrum. If the third molar is single rooted just after guttering make purchase point just at or little below the fulcrum point and elevate it as described above or if multirooted tooth is showing resistance, section it and get the tooth separately using the same method as described above.

## References

1. Alessandri-Bonetti G, Bendandi M, Laino L, et al: Orthodontic extraction: Riskless extraction of impacted lower third molars close to the mandibular canal. *J Oral Maxillofac Surg* 65:2580, 2007
2. Gbotolorun OM, Arotiba GT, Ladeinde AL: Assessment of factors associated with surgical difficulty in impacted mandibular third molar extraction. *J Oral Maxillofac Surg* 65:1977, 2007
3. Sanjeev Kumar • Mahendra P. Reddy. Lokesh Chandra • Alok Bhatnagar
4. Amit Bali • Deepika Bali • Ashutosh Sharma • Gaurav Verma.
5. H. Yuasa, T. Kawai, and M. Sugiura, "Classification of surgical difficulty in extracting impacted third molars," *British*

*Journal of Oral and Maxillofacial Surgery*, vol. 40, no. 1, pp. 26–31, 2002. View at Publisher · View at Google Scholar · View at Scopus

6. M. Diniz-Freitas, L. Lago-Méndez, F. Gude-Sampedro, J. M. Somoza-Martin, J. M. Gándara-Rey, and A. García-García,
7. Pederson scale fails to predict how difficult it will be to extract lower third molars," *British Journal of Oral and Maxillofacial Surgery*, vol. 45, no. 1, pp. 23–26, 2007. View at Google Scholar