



Focal Cerebral Calcification – Is It Dangerous

Authors

U.C.Sathiya Banu^{*1}, R.Umarani², K.Baburaj³

^{*1}Post Graduate, Department of Medicine, RMMCH, Chidambaram-608002, Tamilnadu

²Professor of Medicine, Department of Medicine, RMMCH, Chidambaram-608002, Tamilnadu

³Reader of Medicine, Department of Medicine, RMMCH, Chidambaram-608002, Tamilnadu

Abstract

Focal cerebral calcification is a common finding in persons with seizures and it suggests a role in the pathophysiology of seizures. This study reviews the etiology, clinical presentation of epileptic patients with radiological correlation and the prevalence of focal cerebral calcification.

Keywords: *Epilepsy, Computerised Tomography, electroencephalogram, Tonic-clonic seizures, Focal cerebral calcification (FCC), Non focal cerebral calcification (Non-FCC).*

Introduction

Epilepsy is a common clinical presentation accounting for 0.6% of hospital admissions¹. In majority of cases, when first seen, the causative factors are not evident by history and clinical examination alone. Hence diagnostic tools like electro encephalogram (EEG) and Computerised Tomography are employed². EEG is used for functional or electrical mapping of brain and not used for diagnosis and confirmation of epilepsy because in as many as 50% epileptics single interictal recording may be normal. Normal EEG does not exclude the presence of epilepsy, hence neuroimaging is always indicated in adults with new-onset seizures to identify structural causes of epilepsy. However, Magnetic Resonance Imaging is most sensitive and specific for evaluation of the brain parenchyma and is the investigation of choice.

Objectives

To review the incidence, etiology, clinical presentation and imaging profile of seizure patients with focal cerebral calcification presenting to Rajah Muthiah Medical College.

Methodology

This study was conducted during the period from September 2015 to October 2017. During this period all patients presenting with seizures admitted in Rajah Muthiah Medical College and Hospital, Chidambaram were studied.

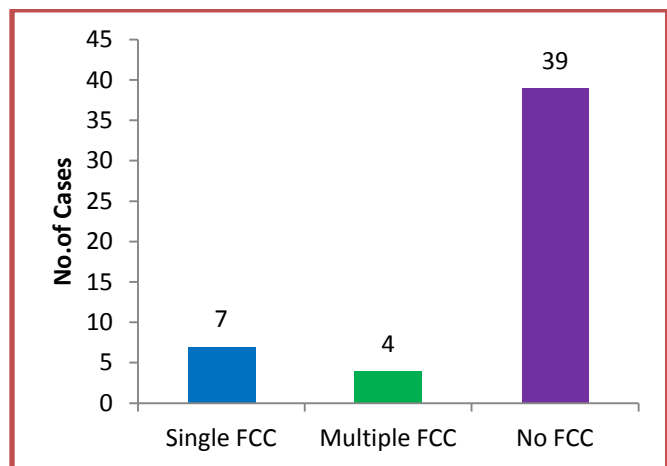
All patients irrespective of age group presenting with seizures and with focal cerebral calcification (<10mm) in their CT scanning will be included in the study. Pregnant women, patients with renal failure, contraindications to MRI, allergy to contrast, very sick patients and without EEG and CT were excluded in the study.

Results

In this study, the incidence of seizures was maximum in 20-39 years of age. There was a slight male predominance with 62% of the total cases. Focal cerebral calcification was found in 22% cases. The lesions were both single and multiple. A similar study by Murthy et al., from South India reported FCC around 23.4% with all types of epilepsies.³

Incidence of Focal Cerebral Calcification

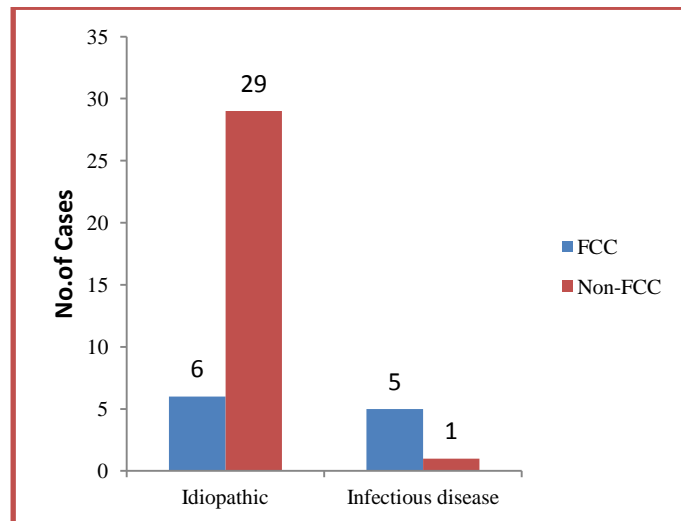
Lesion	No. of. Cases	Percentage
Single FCC	7	14%
Multiple FCC	4	8%
No FCC	39	78%



Etiology

CT shows focal cerebral calcification in 22% (11 cases) and of that 14% (7 cases) had single lesions and 8% (4 cases) showed multiple focal cerebral calcifications. Among the focal cerebral calcification, 3 cases were found to be neurocysticercosis and 2 cases were found to be tuberculoma. In a study conducted by L.N. Sharma et al., of newly diagnosed epilepsy consisting 115 patients of which imaging showed 80 patients in the cysticercal group and 35 in the calcified lesion group⁴.

Etiology	FCC	Percentage	Non-FCC	Percentage
Idiopathic	6	55%	29	74%
Infectious disease	5	45%	1	2%

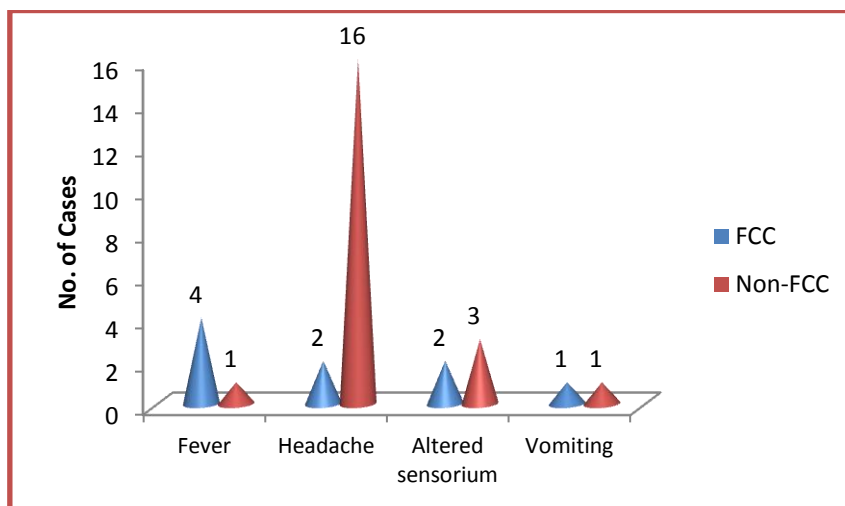


Both neurocysticercosis and tuberculoma present as a single ring enhancing lesion hence the distinction between the two is very difficult. Few authors have attempted to study the differentiation between the two. One among them, Rajshekhar and chandy⁵ suggested that cysticerci are usually round in shape, 20mm or smaller in size, with ring enhancement or a visible scolex; cerebral oedema was severe enough to produce a midline shift. On the other hand tuberculomas are usually irregular in shape, solid and greater than 20 mm in size. Del Brutto et al.,⁶ suggested that presence of an eccentric dot, is diagnostic of cysticercosis as this dot represents the scolex of cysticercosis.

Clinical Presentation

The most common presentation of these patients was fever, which was seen in 4 cases. Headache and altered sensorium was the next common presenting symptom with each 2 cases. Among non-FCC patients, the most common presentation was headache. In a study by Bruns and Hauser, on epilepsy, altered sensorium was the most common symptom followed by headache.

Symptoms	FCC	Percentage	Non-FCC	Percentage
Fever	4	36%	1	3%
Headache	2	18%	16	41%
Altered sensorium	2	18%	3	8%
Vomiting	1	9%	1	3%

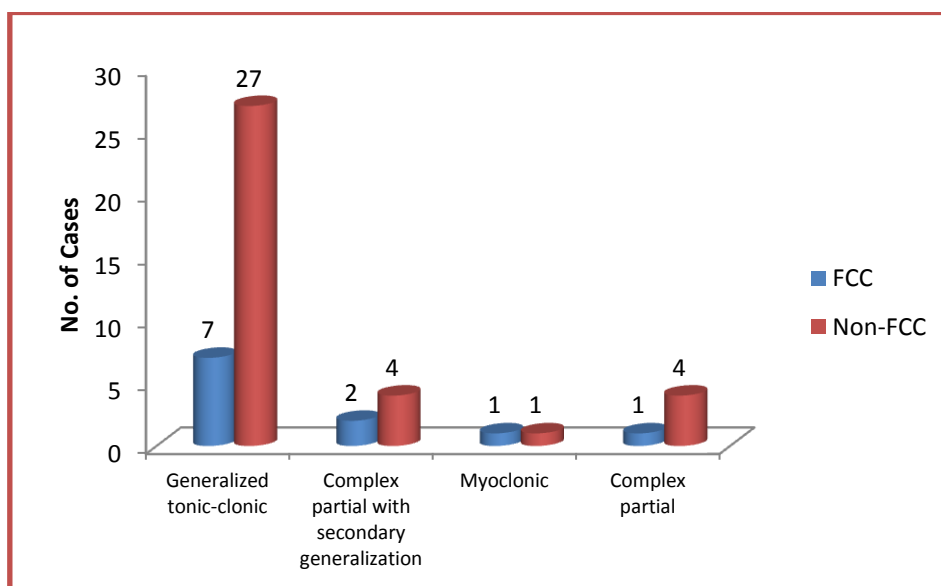


Seizure Types

Generalized tonic-clonic seizures was most common in both FCC and non-FCC patients. Among the 11 cases of FCC, 7 cases (64%) presented with generalized tonic-clonic seizures.

This was also concluded in the study by Neundorfer B in which 68% presented with generalized type. Zhu PG studied new onset seizures which revealed generalized seizures in 64%⁷.

Seizure type	FCC	Percentage	Non-FCC	Percentage
Generalized tonic-clonic	7	64%	27	74%
Complex partial with secondary generalization	2	18%	4	10%
Myoclonic	1	9%	1	3%
Complex partial	1	9%	4	3%

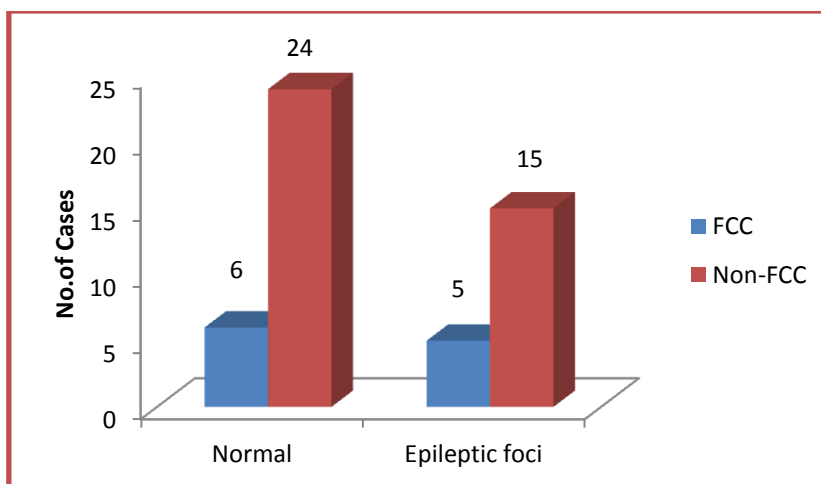


Correlation of EEG in FCC and Non-FCC

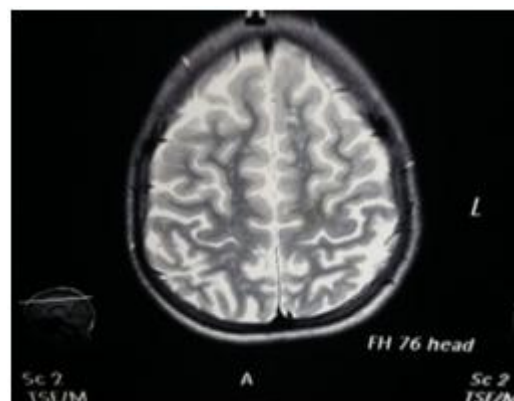Among patients with FCC 54% had normal EEG and 45% had features suggestive of seizure activity in EEG. This was similar to non-FCC which also showed 62% cases with normal EEG.

In a study by Swaroopa Deme et al., EEG was found to be normal in 55% of patients and abnormal 45% patients which correlated with our study.

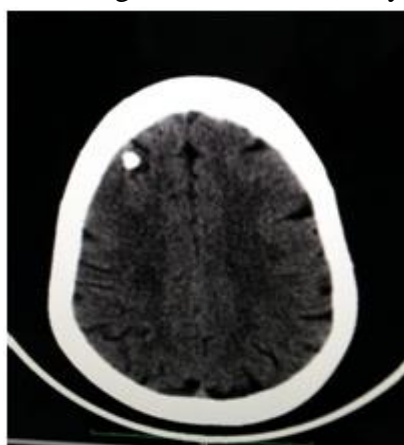
EEG	FCC	Percentage	Non-FCC	Percentage
Normal	6	54%	24	62%
Epileptic foci	5	45%	15	38%



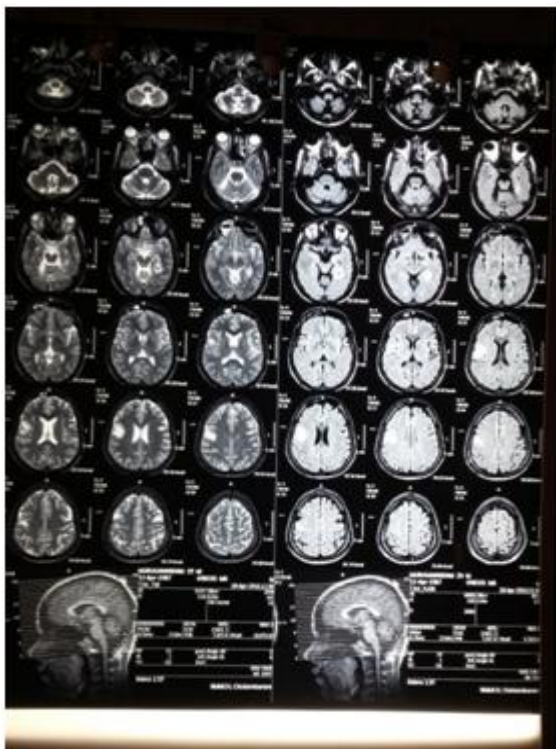
There are three pieces of evidence that suggest calcified lesions play a role in epileptogenesis: 1) high prevalence of typical cerebral calcification in patients with seizures or epilepsy in the absence of other etiologies, 2) a positive correlation between endemic populations with increased proportions of calcification and seizures activity, and 3) an increased risk of continued seizure activity due to single cysticercal granuloma that calcify.



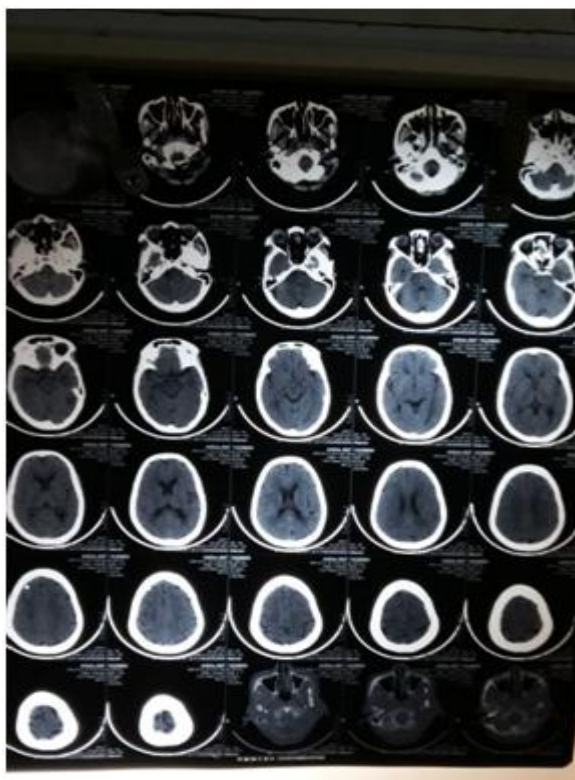
MRI brain showing multifocal hyperintense signals in subcortical white matter in both frontal lobes.



CT image of brain showing calcified granuloma in the left frontal region



MRI brain showing multiple hypointense lesions with blooming foci in bilateral parietal and left temporal areas are neurocysticercosis stage 3 with perilesional edema and lesions in the right occipital and left frontal regions are stage 4 neurocysticercosis.



CT brain showing calcified foci in the left frontal region suggestive of tuberculoma.

The duration of hospitalization, morbidity during hospitalization, recurrence of seizures and the control of seizures using single AED was similar in patients with FCC and non-FCC.

Discussion

Focal cerebral calcification³ are a common findings in persons with seizures. Focal cerebral calcification are single or multiple, small <10mm calcified lesions revealed in radiological imaging. Prevalence range from 9% to 18% in randomized studies of endemic populations with seizures. In our study we have concluded the incidence of FCC to be 22%. Typical calcification were found in 36% and 35% of persons with seizures in two different villages compared to 15% and 9% in matched controls without a history of seizures.

The most common etiology of FCC is cysticercosis, healed tuberculoma, fungal granuloma or small calcified AV malformation⁴. About 16% to 45% of cysticercosis granuloma end up as calcification. In our study we have seen 3 patients with cysticercosis and 2 patients with tuberculoma. In an endemic village of Peru, 9 (31%) of 29 patients with epilepsy demonstrated lesions compatible with cysticercosis and 6 (20.7%) showed only calcifications. The most common type of seizures presented in our study was GTCS and the next common was CPS with secondary generalization. Retrospective study of Perez et al., in 250 patients with symptomatic seizures revealed 59% with generalized seizures. The non convulsive symptoms encountered in our study were fever, headache and altered consciousness. The purpose of the neurological examination is to identify focal or diffuse cerebral dysfunction. This information is particularly helpful in localization of FCC. The presence of various features offers clues to the focus of a seizure. Electroclinical activity correlates with brain calcifications in 26% to 55% of the cases. In our study EEG was found to be abnormal in 45% of patients and normal in 55% patients. Similarly a study by Swaroopa Deme et al., concluded 55% patients with normal EEG. Thus a normal EEG

does not rule out epilepsy and treatment. Single enhancing lesions in CT shows spontaneous disappearance in the majority of patients and some show a considerable reduction in size. Many authors concluded that patients harbouring single enhancing lesions, even in non-endemic regions need careful observation, as these lesions may disappear spontaneously and patients can be prevented from unnecessary neurosurgery intervention. The edema surrounding the lesion is the first to resolve followed by the disappearance of lesion without any residue or it may leave a tiny speck of calcification at the lesion site.

In our study the incidence of FCC was 22% with infection as the commonest cause. Other than GTCS, the next common seizure type was CPS. Correlating the EEG there was no significant difference between FCC and non-FCC. The clinical presentation was suggestive of meningeal irritation which could be due to small sample size.

Conclusion

Although calcified lesions are considered as poor prognostic indicators of seizure control, not all calcified lesions are associated with a poor outcome. Even in patients with FCC-related epilepsy some have a benign course while others have multiple seizures which has to be controlled by more than one anti-epileptic drugs (AEDS). Treatment with anti-helminthic drugs and anti-tubercular drugs has made seizures with focal cerebral calcification a good treatable condition.

References

1. Swaroop Deme et al. A study of correlation of CT scan brain and EEG in epilepsy.
2. G. Ladurner, W.D. Sager. Summary: the value of CT and EEG in the diagnosis of epilepsy. Fortschs. Neurol psychiat., 1979; 47: 264-268.
3. Murthy JM, Reddy vs, clinical characteristics, seizure spread patterns and prognosis of seizures associated with a single small cerebral calcified CT lesions. Seizure 1998; 7: 153-7.
4. Pal DK, Carpio A, Sander JW. Neurocysticercosis and epilepsy in developing countries. J Neural neurosurg psychiatrist 2000; 68: 137-43.
5. Chandy MJ, Rajshekhar V, Prakash S et al. Cysticercosis causing single small CT lesions in Indian patients with seizures. Lancet 1: 390-391, 1989.
6. Del Brutto OH. Prognostic factors for seizure recurrence after withdrawal of antiepileptic drugs in patients with neurocysticercosis. Neurology 1994; 44: 1706-9.
7. Zhu PG Neurology Department, Tong Ji Hospital, Tong Ji Medical University, Wuhan. PMID; 2282883.