



## Case Report

# Rare Manifestation of Systemic Lupus Erythematosus

Authors

**Dr Kuldeep Kumar Kaul, Dr Kumar Jee Kaul, Dr Diptiman Kaul**

Govt Medical College, Jammu

Corresponding Author

**Dr Kumar Jee Kaul**

Govt Medical College, Jammu

### **History and Examination**

A 37 years old patient with no co-morbidities presented with two episodes of generalised tonic clonic seizures lasting for 5 minutes followed by post ICTAL unconsciousness for 30 minutes.

Physical examination revealed tongue bite and alopecia over scalp region. Other systems were unremarkable. vital parameters were within normal range.

### **Investigation and stay in hospital**

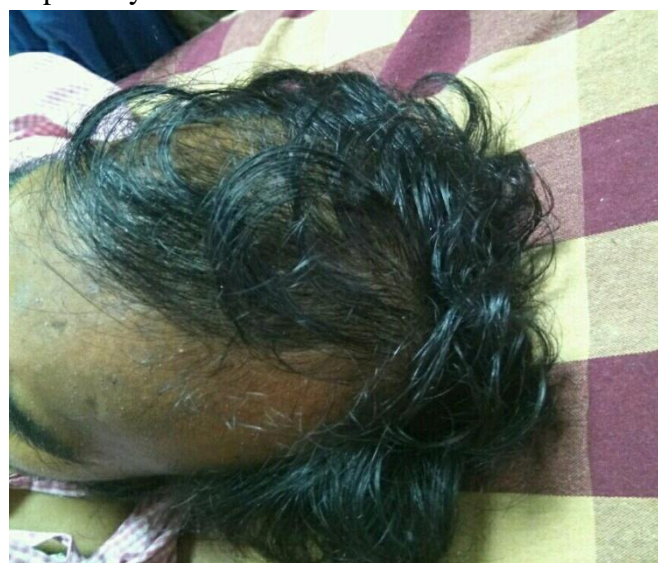Blood reports revealed anemia with leucopenia and thrombocytopenia. peripheral smear (PS) showed dimorphic anemia, thrombocytopenia with leucopenia. LFT, chest xray, ultrasound abdomen were normal, serum electrolytes were also normal. Provisional diagnosis of seizure disorder with pancytopenia was made and patient was started on iv eptoin and iv levetiracetam. mri brain was done and was unremarkable.

In view of pancytopenia, bone marrow aspiration and biopsy was done which revealed hypocellular normoblastic bone marrow.

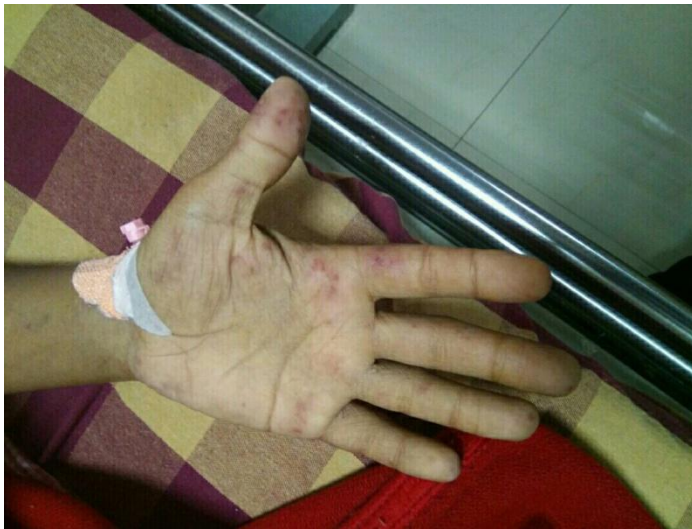However three days later, patient developed oral ulcers, sub cutaneous nodules over knee joint, hand and rashes across the cheekbones and over

the bridge of nose. In view of this presentation, ANA profile was done and was positive for anti-smith antibodies, anti-RO antibodies and SCL-70 antibodies.

A final diagnosis of systemic lupus erythematosus-scleroderma overlap syndrome was made and patient was started on pulse therapy of steroids. however, patient developed breathlessness and fall in oxygen saturation and was shifted to ICU but succumbed due to respiratory failure.



**Alopecia over Scalp Region**

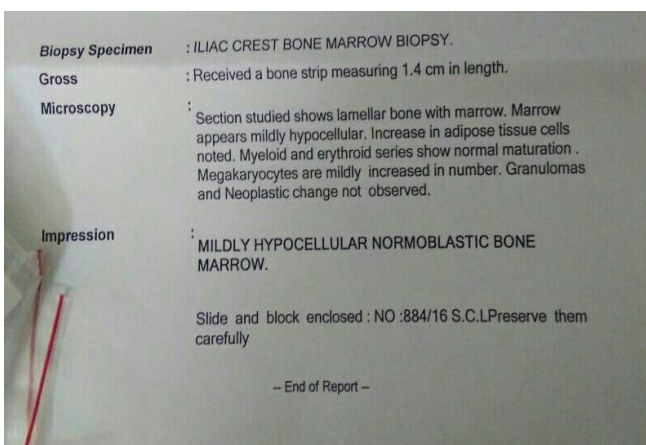


**Subcutaneous Nodules on Hand**

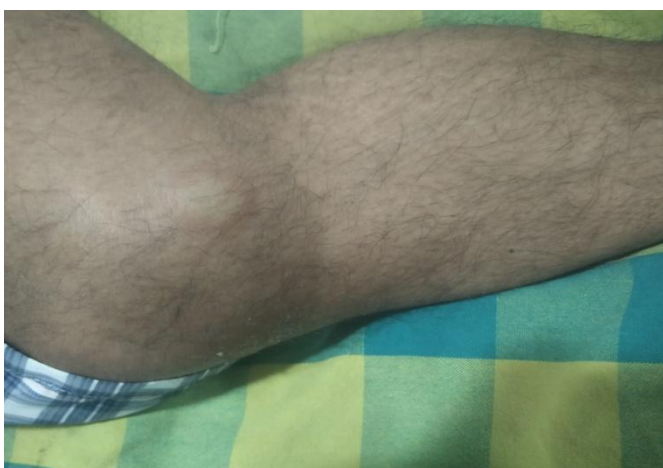ANA Profile (IMMUNO BLOT)		
DsDNA	Negative	Negative
NECULEOSOMES	Negative	
HISTONES	Negative	
SmD1	Positive	
PCNA	Negative	
PO	Negative	
SS-A/Ro 60 kDa	Positive	
SS-B	Negative	
CENP B	Negative	
Scl-70	Positive	
U1-snRMP	Negative	
AMA-M2	Negative	
JO-1	Negative	
Pm-Scl	Negative	
Control Band	Valid	

\*\*\*End of Report\*\*\*

**ANA Profile Report**



**Bone Marrow Aspiration and Biopsy Report**



**Subcutaneous Nodule over Knee Region**

**Conclusion**

Systemic lupus erythematosus (SLE) is an autoimmune disease in which organs and cells undergo damage initially mediated by tissue binding autoantibodies and immune complexes. SLE usually presents as oral ulcers, malar rash, alopecia, synovitis, hemolytic anemia, subcutaneous nodules formation with lupus nephritis. SLE presenting as generalised tonic clonic seizures is a rare manifestation with incidence rate of less than 2%.

So as a part of management of generalised tonic clonic seizures, rare causes such as SLE should be kept in mind as they can lead to devastating complications and even death of the patient.