



Case Report

Anterior Esthetic Crown Lengthening Surgical Procedure

Authors

Dr Tamer Elsayed Essa¹, Dr Abdullah Alsani², Dr Mohammad Aljalal³

¹Lecturer, Department of Oral Medicine, Oral Diagnosis and Periodontology, Faculty of Dentistry

²General Dental Practitioner, ³Registrar in Periodontics

ABSTRACT

The aim of this case report was to describe the surgical sequence of crown lengthening. Many different causes can be responsible for short clinical crown. In our case, the gingival overgrowth is the case that producing shortness of upper anterior crowns. According to the American Academy of Periodontology in 2003 (Practice Profile Survey), crown lengthening is the most habitual surgical periodontal treatment.

Keywords: Dental, Crown-lengthening, Anterior, Aesthetics.

INTRODUCTION

The periodontal plastic surgeries have been valued and sought by people who claim they want to correct (Gummy Smile), which happens when one has expose more gum than teeth during smiling. The appearance of gingival tissue surrounding teeth plays an important role in esthetics of the anterior maxillary teeth. Abnormalities in symmetry and contour can significantly affect the harmonious appearance of the natural or prosthetic dentition. As well nowadays, patient has a greater desire for more esthetic appearance, which may influence treatment modalities. A perfect anterior appearance necessitates healthy and normal periodontium. Several researches described various components of periodontium, giving mean dimensions of 1.07 mm for the connective tissue, 0.97 mm for the epithelial attachment and 0.69 for the sulcus depth. These measurements are known today as the biologic width ⁽¹⁾. The combination of these two

measurements constitutes the biologic width, that is, 2.04 mm in average. On the other hand, an additional 1 mm might be coronally added to the 2 mm dentogingival junction, as an optimal distance between the bone rest and the margin of a restoration, to permit healing and proper restoration of tooth ⁽²⁾.

The common causes of short clinical crown includes caries, tooth malformation, excessive tooth, reduction disharmony, fracture, attrition, erosion, exostosis and genetic variation ⁽³⁾.

Therefore, this deficiency in clinical crown length should be increase when margins of caries or margins of the tooth fractures are subgingivally placed, crown is too short for retention of restoration, there is an excess of gingiva, and anatomical tooth crown is partially erupted ⁽⁴⁾ The abnormal growing of the size of the gingiva is a characteristic of gingival diseases. Currently, this clinical situation is called gingival overgrowth, such

condition may compromise the aesthetic smile, inducing the person affected by this condition to looking for surgical procedures in order to acquire a more harmonic and attractive smile, increasing one's assurance and self-satisfaction^(5,6). In cases which the surgical intervention is the indicated procedure, the choice of the correct technique must be used to obtain the most accurate result. Many techniques have been proposed for the periodontal surgical treatment, the gingivectomy was created in 1979 with a tissue excision of a pathological periodontal pocket⁽⁷⁾. Widman 1981 published the technique at the time called "The Original Widman Flap, in which he described such technique for elimination of the periodontal pocket with or without bone recontouring for the purpose of establishing a new alveolar bone physiology^(7,8). Neuman 1920 later suggested changes to the original technique introducing intrasulcular incision and access to better root debridement⁽⁹⁾. In another article Neuman demonstrated the removal of gingival collar after the mucoperiosteal flap following bone leveling with round bur. Later the technique retail for "papilla preservation" was proposed with objective preserve the interdental tissues making it possible to have greater coverage of the flap in the proximal bone defects treatments, this technique was improved for the use in regenerative procedures and often used in anterior teeth^(10,11).

Currently studies have described the periodontal surgery technique with removal of gingival collar and osteotomy with the purpose to increase the aesthetic crown and to balance short dental crowns and gummy smiles, increasing the size of dental crown. A randomized study compared the use of technique with flap and flapless during the period of twenty months, finding that there were no significant differences between the two techniques demonstrating the predictability of treatment. The distance between the bone crest and the cement-enamel junction (CEJ), with range from 1.5 mm to 2 mm, is crucial to indicate bone remodeling, where there is not such distance the osteotomy procedure is done in order to create enough space

accommodation of connective tissue attachment, junctional epithelium and gingival sulcus. Nowadays, the surgical procedures for the treatment of gummy smile with aesthetic goals have been named in various ways, such as periodontal plastic surgery, aesthetic crown lengthening.

CASE PRESENTATION

A 26-years-old woman referred to dental department. She complained about her "dissatisfaction with her inharmonious smile" because of the small size of her teeth and overexposure of the gingiva while she smiles. After the medical history analysis by *Cornell modified test* and clinical oral and extra oral examination, preliminary radiographic and periodontal. It was found healthy periodontal tissue support with no gum bleeding. Her face was symmetric and had a straight profile. Her smile line extended to the first premolars, and smiling displayed approximately 5 mm of gingival tissue. Ideally the central incisors and canines are approximately equal in length and are usually 20% longer than the lateral incisors. The central incisors should be 25% wider than the lateral incisors and 10% wider than canine. Furthermore, the length-to-width ratio of individual teeth should be 1.2:1 for canines and lateral incisors and 1.1:1 for the central incisors.

Periodontal examination revealed good oral hygiene with minimal plaque and calculus deposition. The gingiva was pink and firm, and the papillae were intact.

Clinical examination revealed shadow probing depth, no mobility and adequate amount of keratinized attached gingiva. Review of the full mouth series revealed no significant findings. The crystal bone level was within normal limits, and the crown to root ratio was favorable (Figure 1).

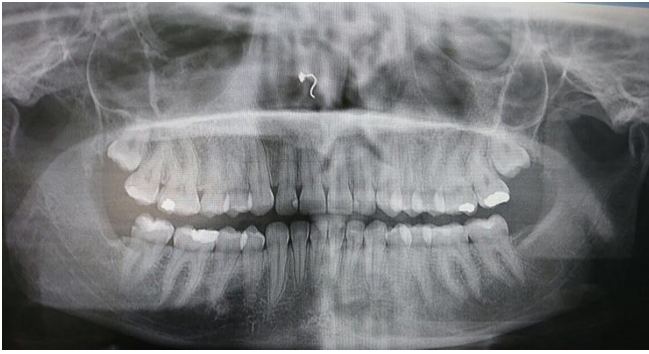


Figure-1: Orthopantomogram

Occlusal analysis revealed, among other findings, an Angle's class I relationship. No sign of fremitus where observed. The patient with adequate anterior guidance upon protrusive and adequate group function upon lateral excursions. After consultation with restorative dentist, esthetic crown lengthening was recommended to allow a healthy, optimal relationship between the teeth and periodontium.

Based on anatomy of the gum line, the crown lengthening surgical procedure has been a line our treatment for aesthetic excess cases the gingival tissue where there no periodontal disease, the patient was photographed (Figure 2), molded and then the study models were made, through which diagnostic wax-up was created and it was possible to designed the clinical crown enhancement surgical procedures with all its functional and aesthetic characteristics for the patient.

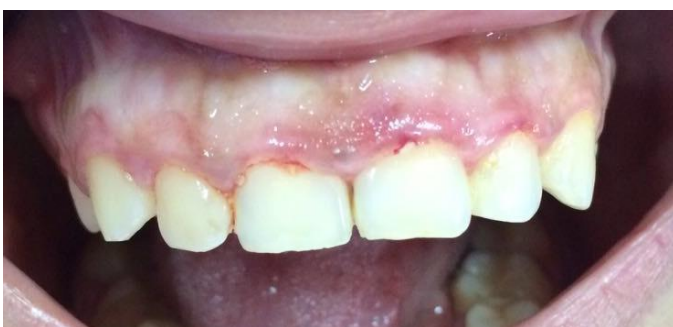

Figure-2: Preoperative intraoral view

The guide was inserted in the mouth and the new gingival margin was registered with scalpel (Figure 3), Thus a full-thickness mucoperiosteal flap was elevated and the gingival collar extracted with Gracey curette (Figure 4). For osteotomy, measurement of the distance between the guide

edge and the cervical bone was recorded. This distance should be about 3 mm for biologic width maintenance. The creation of precise biologic width requires an additional osseous contouring which was performed using manual instrument then (Figure 5), the flap was sutured (Figure 6).

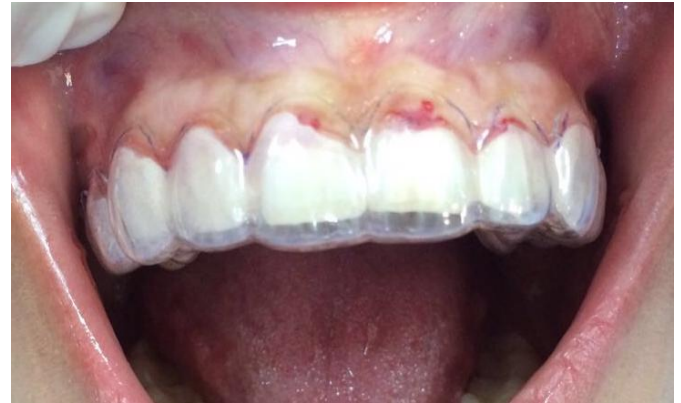

Figure-3: New gum margin registration

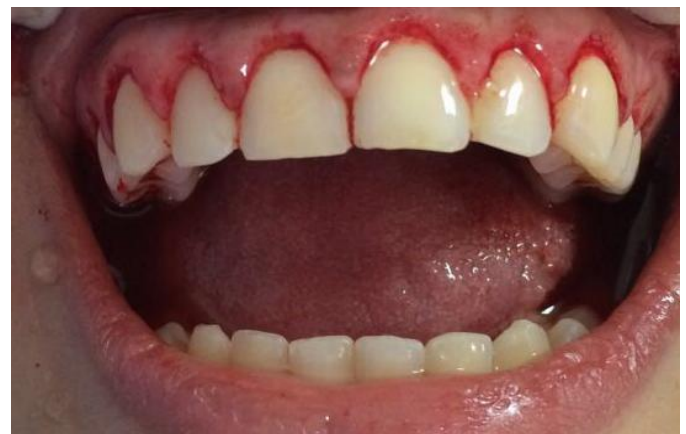

Figure-4: Gingival collar extracted

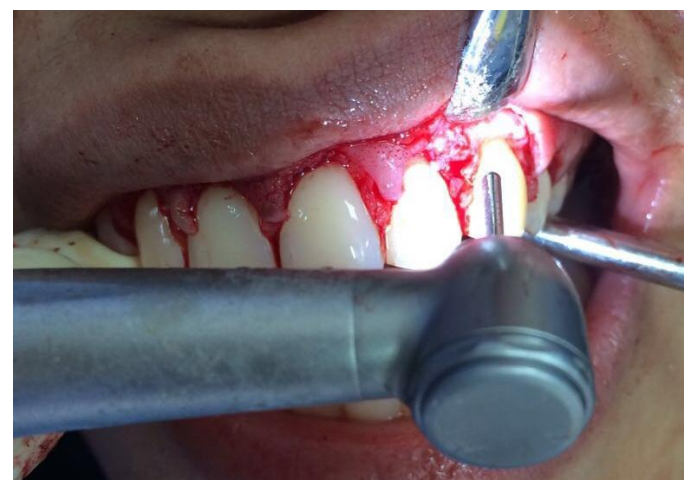

Figure-5: Osseous contouring

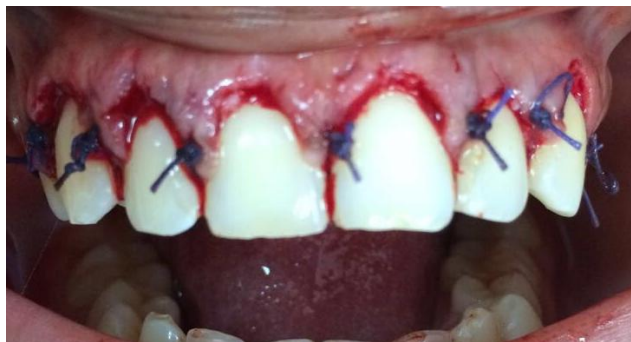

Figure-6: Future of the surgical region

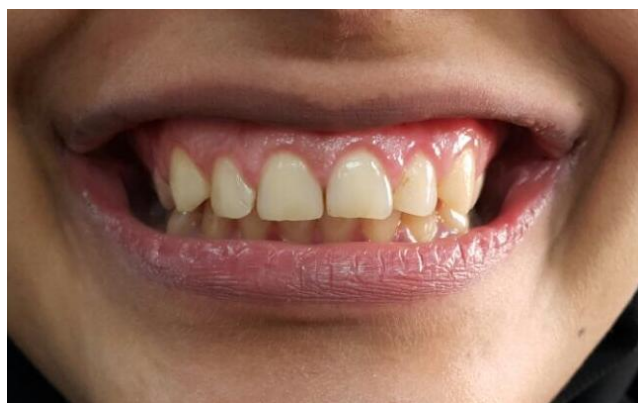

Figure-7: 6-months follow up

DISCUSSION

Surgical crown lengthening is performed for improvement of aesthetic, this surgical procedure can establish an accurate bone width and correct gingival overgrowth⁽¹²⁾. To obtain optimal treatment plane, it is necessary to consider the position of the lips, gingival architecture, amount of keratinized tissue and gingival biotype. The surgical esthetic crown lengthening requires gingivectomy procedures to expose the needed additional tooth structure; therefore, a minimum of 2 to 5 mm of keratinized tissue is necessary to ensure the gingival health^(13,14). Moreover, the management of the papilla is another important challenge of the surgery. The interproximal bone should be carefully excised in order to maintain the anatomic structures. So that, the interproximal tissues are allowed to coronally proliferate the papilla should replace the distance from the alveolar bone crest to the base of the contact area (about 5 mm or less)^(15,16).

Any smaller residual interproximal space can be eliminated by apically positioning flap the contact area of the definitive restoration^(17,18). To have a harmonious and successfully long-term restoration,

the distance between the crestal bone and prosthetic margins, which allows recreating the biological width, should be at least 3 mm⁽¹⁹⁾. This can be surgically achieved by crown lengthening, as presented in this case report, or orthodontically by forced tooth eruption or by a combination of both procedures⁽²⁰⁾.

REFERENCES

1. GarguiloAW .Dimention and relationship of the dentogingival junction in humans. J Periodontal 1961;32:261-7
2. Ingber JS, Rose LF, Coslet JG. The "biologic width " a concept in periodontics and restorative dentistry Alpha Omegan 1977: 70(3):62-5
3. M. Davarapanah, C.E. Jansen, "Restorative and periodontal consideration of short clinical crowns " Intrnational Journal of Periodontics and Restorative Dentistry, 1998 Vol. 18, no. 5, pp. 425-433.
4. N, Tomar, T. Bansal, "the perio-esthetic-restorative approach for anterior rehabilitation, "Journal of Indian Society of Periodontology, 2013: Vol. 17, no. 4, pp. 535-538.
5. Carranza Jr FA, Newman MG, Takei HK, Klokkevold PR. Carrenza's clinical periodontology, St. Louis: Saunders/ Elsevier;2007.
6. Malkinson S, Waldrop CT, Gunsolley CJ, Lanning KS, Sabatini R. The effect of esthetic crown lengthening on perceptions of patient's attractiveness, friendliness, trust worthiness, intelligence, and self-confidence.J Periodontal 2013; 84(8):1126-33.
7. Grant DA, Stern IB, Everett FG. Peridontics in the transition of Orban and Gottlieb. St. Louis: C.V Mosby co; 1979.
8. Widman L. The operative treatment of pyorrhea alveolaries. A new surgical method. Brit Dent J 1920;1:293.
9. Neiman D. Alveolar-puorrhoe und ihrebehandlung. Berlin: Herman Musser; 1931.
10. Takei H, Han T, Carranza FA Jr, Kenney EB, Lekovic V. Flap technique for

- periodontalbone implant-papilla preservation technique. J periodontal 1985;56:204-10.
11. Cortellini P, PiniPerto G, Tonetti MS. Periodontal regeneration of human intrabony defects with titanium reinforced membranes. A controlled clinical trial. J periodontal 1995;66:797-803.
 12. P. Fletcher “Biologic rationale of esthetic crown lengthening using innovative proportion gauges” The International Journal of Periodontics & Restorative Dentistry, 2011 31(5):523-532.
 13. N. P. Lang and H. Loe, “The relationship between the width of keratinized gingiva and gingival health,” Journal of Periodontology,1972, 43(10): 623–627.
 14. J.G. Maynard Jr. and R.D. Wilson, “physiologic dimension of periodontium significant to the restorative dentist, “ Journal of Periodontology, 1979,50(4):170-174.
 15. J. C. Kois, “Altering gingival levels: the restorative connection part I: biologic variables,” Journal of Esthetic and Restorative Dentistry,1994,6(1):3–7.
 16. D. P. Tarnow, A. W. Magner, and P. Fletcher, “The effect of the distance from the contact point to the crest of bone on the presence or absence of the interproximal dental papilla,” Journal of Periodontology,1992,63(12):995–996.
 17. H.-S. Cho, H.-S. Jang, D.-K. Kim et al., “The effects of interproximal distance between roots on the existence of interdental papillae according to the distance from the contact point to the alveolar crest,” Journal of Periodontology,2006,77(10):1651–1657.
 18. P. Martegani, M. Silvestri, F. Mascarello et al., “Morphometric study of the interproximal unit in the esthetic region to correlate anatomic variables affecting the aspect of soft tissue embrasure space,” Journal of Periodontology,2007,78(12): 2260–2265.
 19. U. Bragger, D. Lauchenauer, and N. P. Lang, “Surgical lengthening of the clinical crown,” Journal of Clinical Periodontology,1992,19(1):58–63.
 20. J. C. Kois, “New paradigms for anterior tooth preparation. Rationale and technique.,” Oral Health, 1998,88(4):19–22.