



Comparative Study of TAPP Repair Vs Open Tension Free Inguinal Hernioplasty

Authors

Dr Vinaya K. Ambore¹, Dr Mayank B. Mishra²

¹M.S. General Surgery, Associate Professor and Unit Head, Dept. of Surgery, Grant Govt. Medical College & Sir J J Group of Hospitals, Mumbai, Maharashtra

Email: vinaya.ambore@gmail.com

²M.S. General Surgery, Senior Resident, Dept. of Surgery, Grant Govt. Medical College & Sir J J Group of Hospitals, Mumbai, Maharashtra

Email: drmayankb@gmail.com

ABSTRACT

Aims and Objective: Present study was conducted with objective to compare laparoscopic TAPP (Transabdominal preperitoneal) repair with open tension free repair with respect to operative time, complications, postoperative recovery.

Materials and Methods: A comparative study was conducted in tertiary health care center from May 2012 to November 2014 and cases fulfilling inclusion criteria were included in study. 38 cases were operated in laparoscopic TAPP repair while 68 cases with open tension free repair and assessed for complications and postoperative recovery.

Result: In the study operative time was higher for Laparoscopic TAPP repair (50 min Vs 30 min, p value <0.05), while post op complication were lower for TAPP repair (15.8 % Vs 16.2 %, p value <0.48) but difference was insignificant, chronic pain at 6 month is less for TAPP repair (0.18 Vs 1.48, p value <0.5) and time to return to normal activity was also lower for laparoscopic group (9.3 days Vs 13.8 days, p value <0.5).

Conclusion: Laparoscopic TAPP repair offers a significant advantage over open tension free hernioplasty. It was associated with less post operative pain, faster recovery and higher operative time due to learning curve with insignificant difference in early post operative complication. Thus, Laparoscopic TAPP repair should be considered for primary hernioplasty in view of lesser post operative pain and faster recovery.

Keywords: Inguinal Hernia, TAPP repair, Open hernioplasty.

Introduction

The word Hernia is derived from a Latin term meaning a rupture. Inguinal Hernia is one of the most common surgical condition in the world. Its diagnosis is made mostly by clinical examination and if required ultrasound scan can be done. The overall lifetime risk of developing inguinal hernia is 15% in men and less than 5% in women¹. After initial peak in infants groin hernia become more

prevalent with advancing age. Within the last few years the use of minimal access surgery has expanded to encompass most procedures in general surgery. The use of laparoscopic techniques in the repair of groin hernia however remains controversial.

Long-term recurrence rate remains the most important outcome parameter after repair of inguinal hernia. Therefore, at present, the use of

prosthetic material has replaced traditional tissue repairs such as the Shouldice technique. Tension-free mesh repair is now the standard of care for inguinal hernia repair in adults². Laparoscopic hernia repair is similar to the open pre peritoneal approaches and is performed trans-abdominally or totally extra peritoneal. Unlike laparoscopic cholecystectomy, this procedure has been slow to gain acceptance. This reluctance is mainly because of reports of rare serious complications during and after surgery which include visceral, vascular and nerve injury and small bowel obstruction. A further drawback has been the long learning curve associated with these techniques and a high rate of failure to repair the hernia in this transitional learning period for the surgeon³.

The laparoscopic technique has replaced the open approach in many surgical procedures. This development has largely taken place without desirable preceding studies proving the safety and benefit to the patient. Inguinal hernias are common and although the results of surgical repair are often satisfactory, postoperative recovery may be slow and the hernia may recur³. Laparoscopic techniques for the repair of inguinal hernias have recently been introduced and in several small trials, these techniques have been shown to be superior to open repair in terms of postoperative pain and recovery⁴. The primary aim of the studies was to compare the treatment groups undergoing open and laparoscopic repair of hernia with respect to time to return to normal physical activity, complications, early recurrence rate.

Materials and Methods

Patient having bulge / swelling in inguinal region whether unilateral, bilateral, primary or recurrent resulting in discomfort and/or dragging pain with positive cough impulse admitted in surgical wards of a tertiary care hospital were included in the study. The patients were provided with a detailed printed information sheet to explain about nature of disease and detail information of both operative procedure after taking consent, 106 cases were

selected according to inclusion criteria { i.) Patient between 12 to 65 years age group with direct / indirect inguinal hernia, (ii) Unilateral, bilateral and recurrent hernia} and exclusion criteria { i) Female patients, (ii) Patients with strangulated, irreducible and giant inguinal hernia} who attended surgical OPD from August 2012 to November 2014. Each case was thoroughly investigated and cases were taken for surgery. Written informed consent was obtained from patients preoperatively.

All operated patients were assessed for intra-operative difficulties, intra-operative complications, duration of surgery, post-operative pain, mobilization, post op complication and duration of hospital stay. Patients were followed after discharge on 7th postoperative day and after 6 months. They were assessed for duration to return to normal activity, chronic postoperative pain at 6 month, delayed complications like numbness, neuralgia and recurrence.

Results

A total of 106 patients were included in the study in which 38 (35.8%) were operated by laparoscopic TAPP repair while 68 (64.2%) patients operated by open tension free inguinal hernia repair. The median age was 43.1 years in laparoscopic group while 44.8 years in open repair group. In which 64 (60.4%) cases were of right side 39 (36.8%) left side and 3 (2.8%) were bilateral and 5 (4.7%) cases of recurrent inguinal hernia. Mean operative time in TAPP repair was 50 minute and 30 minute in open repair. There were 2 instances of laparoscopic conversion to open procedure both were due to hemorrhage affecting visual field. There were no instances of any major vascular and visceral injury in both groups.

Early postoperative complications occurred in 15.8% cases in TAPP repair which mostly includes seroma and urinary retention (5.3% each) while in open repair 16.2% cases got complicated in the form of cord edema and urinary retention (4.4% each). Patients were

evaluated for postoperative recovery by visual analogue scale (VAS) score and Time to return to Normal activity. Postoperative pain was evaluated on Post Operative Day 1 (POD1), POD2 and POD7 which was higher in open inguinal hernia repair (5.7, 4.0 and 2.0 respectively) as compared to TAPP repair (3.9, 1.5 and 0.5 respectively) and analgesic requirement was also higher in open repair group (13.9 Tab Vs 8.9 Tab). Laparoscopic

TAPP repair group also well performed w.r.t. Time to return to normal activity (9.3 days Vs 13.8 days). Late postoperative complications chronic pain was evaluated at 6 month with lower VAS score for TAPP repair (0.18 Vs 1.48), Numbness and neuralgia were also lower in TAPP repair (2.7% Vs 15.2%). TAPP repair was cosmetically superior with smaller scar size (3.6 cm Vs 7.5 cm).

Table 1. Demographic characteristics of the Inguinal hernia

Characteristics	TAPP Repair	Open Hernioplasty
Median Age (In years)	43.1	44.8
Lateralization		
Right side	26 (68.4%)	38 (55.9%)
Left side	11 (28.9%)	28 (41.2%)
Bilateral	1 (2.6%)	2 (2.9%)
Primary / Recurrent		
Primary	36 (94.7%)	65 (95.6%)
Recurrent	2 (5.3%)	3 (4.4%)

Table 2. Comparison of Laparoscopic TAPP repair and Open Hernioplasty

Characteristics	TAPP Repair	Open Hernioplasty	Level of significance (p value)
Operative Time (min)	50	30	<0.0000001
Early Postoperative Complications	15.8%	16.2%	<0.48
Postoperative pain score (VAS)			
POD1	3.9	5.7	<0.0000001
POD2	1.5	4.0	<0.0000001
POD7	0.5	2.0	<0.0000001
Time To Return To Normal Activity (days)	9.3	13.8	<0.0000001
Chronic Pain (VAS)	0.18	1.48	<0.0000001
Numbness & Neuralgia	2.7%	15.2%	<0.03
Scar Size (cm)	3.6	7.5	<0.0000001

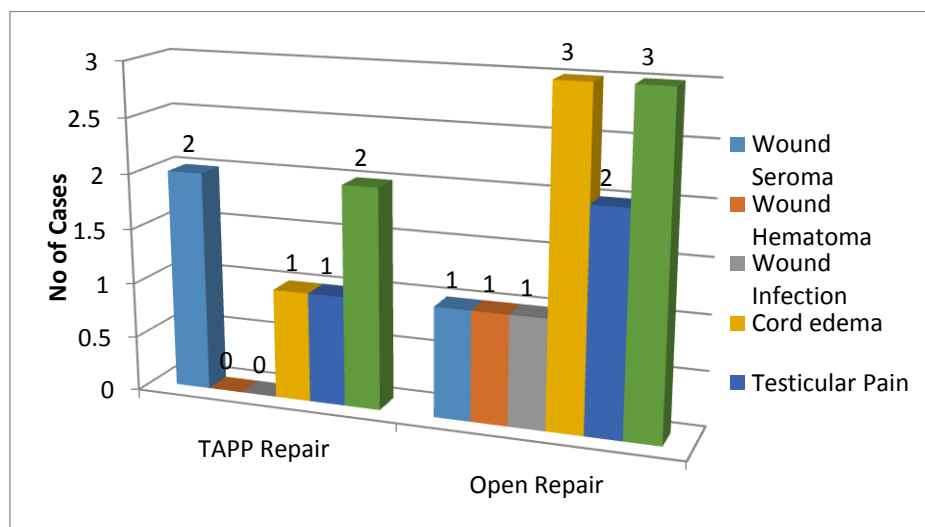


Fig 1: Early Postoperative Complications

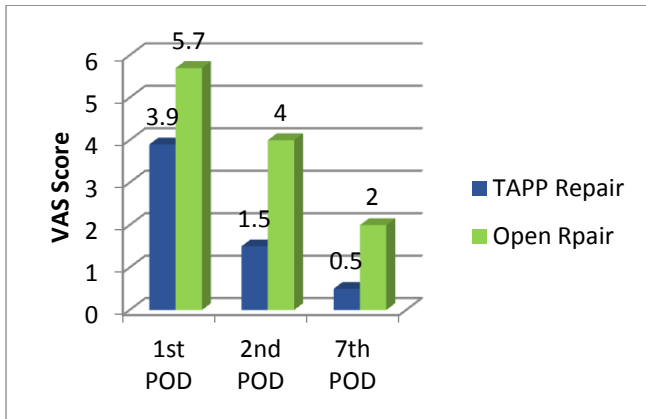


Fig 2: Postoperative Pain Score

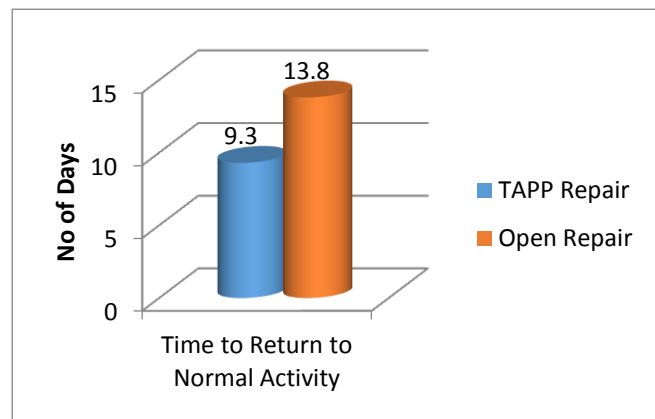


Fig 3: Time to Return to Normal Activity

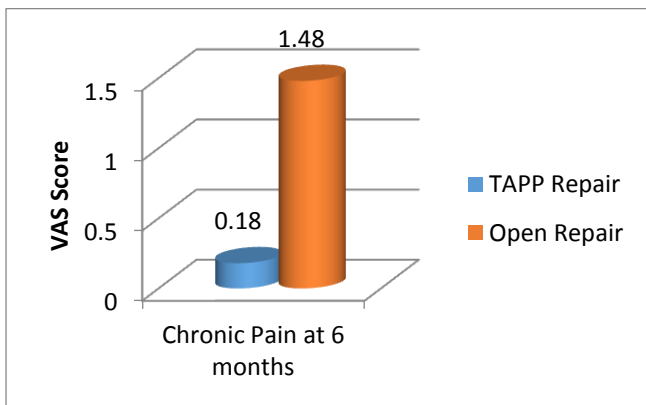


Fig 4: Chronic Pain at 6 months

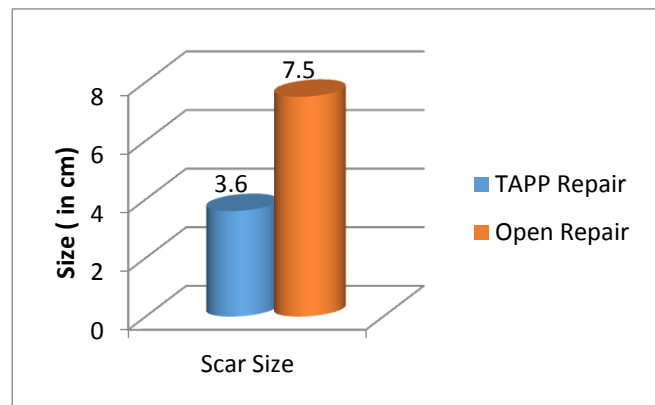


Fig 5: Scar Size

Discussion

Hernias have been a subject of interest since the dawn of surgical history. The history of hernia repair is the history of surgery⁵. The ideal repair should allow the patient rapid return to work, leisure and recreation at a reasonable cost to the patient and the wider community⁶. The laparoscopic technique has replaced the open approach in many surgical procedures and now laparoscopic procedures for inguinal hernia are gradually replacing open procedures, those who favor using the laparoscope for hernia repair state chiefly the belief that laparoscopic hernia repair is more desirable for the patient. The postoperative recovery period, postoperative pain and rapid return to normal occupational activity are considerably less than comparable postoperative characteristics following the "classic" external approaches to hernia repair⁷.

The Laparoscopic TAPP repair was initially associated with higher operative time and post operative complications but with increasing

expertise and advancing technologies these are now comparable to open hernioplasty, In MRC trial⁸ and Wellwood et al⁹ have comparable operative time. Visceral injuries e.g. Bladder injury were more common with laparoscopic repair. The urinary bladder may be inadvertently injured during dissection of a direct inguinal hernia sac, but rarely during repair of an indirect defect. Testicular swelling and atrophy is seen after inguinal hernia repair. Edema of the scrotum or testis may be secondary to edema or hematoma of the inguinal canal that tracks inferomedially to the scrotum in a dependent fashion. Alternatively, a tender testicle or an atrophic testicle may be secondary to injury to the blood supply to the genitals during dissection and isolation of the cord¹.

MRC trial⁸ and Doueck et al¹⁰ noted lower postoperative complication with TAPP repair. In the MRC Laparoscopic Groin Hernia Trial Group and in other studies follow-up of patients up to 7 days after surgery indicates that laparoscopic

hernia repair causes less pain than open repair, assessed by use of analgesics and pain scores^{8,11}. A large number of randomized control trials and meta analyses have shown that patients who undergo laparoscopic hernia repair experiences less pain in the early postoperative period, have lower analgesic and narcotic requirements, better cosmesis and early return to normal activities. Time to return to normal activity was lower in laparoscopic TAPP repair as suggested by MRC trial⁸ and Pironi D et al¹². The typical postoperative pain occurs immediately after surgery, is easily managed with analgesics and subsides as the wound heals. Chronic neuralgia is an often incapacitating pain with hyperesthesia, paresthesia and dysesthesia. The pain is usually reproduced by tapping over the area of point tenderness or extending the thigh¹³. The incidence of chronic pain after hernioplasty varies widely. It lies between 0 and 75% after open mesh repair and 0 and 29% after laparoscopic repair¹⁴. The frequency of pain that affects daily activities is reported to be in the range of 5-6%. Several authors report mesh repair results in less chronic pain than non-mesh, and laparoscopic repair results in less pain than open mesh repair¹⁵. Laparoscopic hernia repair was associated with earlier return to usual activities and less persistent groin pain 1 year after the operation⁸. Postoperative groin pain or neuralgia is common to varying degrees following groin herniorrhaphy. Often, the neuralgia will follow the known distribution of the regional nerves, including the ilioinguinal, iliohypogastric, genital branch of the genitofemoral nerve and the lateral femorocutaneous nerves. During open hernia repair, the ilioinguinal, iliohypogastric and the genitofemoral nerves are most commonly injured, while the lateral femorocutaneous nerve is more commonly injured during laparoscopic herniorrhaphy. Nerve injury is usually due to entrapment of a portion of the nerve in the mesh or suture line placed in one of the soft tissue layers¹.

In a study by Magnus Halle´n, Andersson Bergenfelz and Johan Westerdahl, permanent impaired inguinal sensibility was more common in the open group. This phenomenon is explained most probably by the fact that the laparoscopic approach decreases the likelihood of nerve injury to the ilioinguinal and ilio hypogastric nerves¹⁶.

Certain hernia types are better served by the laparoscopic approach. These include bilateral hernias because both sides can be repaired from the same access ports thereby pushing the risk / benefit ratio in favor of laparoscopy; recurrent hernias assuming the preperitoneal space has not been previously dissected and hernias in women because of higher incidence of femoral recurrence with the usual anterior prosthetic repairs¹.

The hospital cost for laparoscopic hernia repair is significantly higher than that for conventional hernia repair. However, when both direct and indirect costs are assessed in follow-up, the cost difference does not appear to be significant.

Conclusion

Laparoscopic TAPP hernioplasty offers a significant advantage over open tension free hernioplasty. It is associated with less post operative pain and analgesia requirement. The frequency of post operative chronic pain is also less with laparoscopic TAPP hernioplasty as compared to open. Numbness is more commonly associated with open tension free hernioplasty. Laparoscopic TAPP hernioplasty is associated with early recovery and reduced hospital stay, lower analgesic dose requirement, early resumption of normal activity and better quality of life in consideration with bodily pain. However, operative time is prolonged in laparoscopic TAPP Hernioplasty as compared to open. It has no statistical advantage in relation to wound infection, wound seroma and hematoma, scrotal hematoma, and testicular pain. The choice of the procedure should be based on surgeon or patient preference. In spite of the fact that most hernia repairs are performed as open procedures, there is room for an expansion of laparoscopic hernia

repair. Bilateral and recurrent hernias are well accepted specific indications for laparoscopic repair. Young age could also be an argument for laparoscopic repair due to the higher risk of chronic pain in open repair. There is certainly reason in continuing to use the laparoscopic technique for hernia repair. It is clear that the technique already offers advantages in some indications and the technique should be offered on a wider basis.

References

1. Javid PJ et al, Maingots Abdominal Operations 12th ed, Hernia, P- 123-54.
2. Jacobs D. O. Mesh repair of inguinal hernias – Redux. N Engl J Med. 2004; 350:1895-1897.
3. Liem MSL, Van der Graaf Y, Van Steensel CJ, et al. Comparison of conventional anterior surgery and laparoscopic surgery for inguinal hernia repair. NEnglJMed1997; 336:1541-47.
4. M. P. Simons, T. Aufenacker et al. European Hernia Society guidelines on the treatment of inguinal hernia in adult patients. Hernia. 2009; 13:4,343-403.
5. JF Patino. A history of the treatment of hernia. In Hernia 4th edition, Nyhus LM, Condon RE, editors, Philadelphia, Lippincott. 1995; 3–15.
6. W. R. Fleming, T. B. Elliott, R. McL. Jones, K. J. Hardy, Randomized clinical trial comparing totally extraperitoneal inguinal hernia repair with the Shouldice technique, University of Melbourne Department of Surgery, Austin and Repatriation Medical Centre, Austin Campus, Melbourne, Victoria 3084, Australia. 2001;88:1183-1188.
7. Arregui ME, Davis CJ, Yucel O, Nagan RF. Laparoscopic mesh repair of inguinal hernias using a preperitoneal approach: A preliminary report. Surg Laparosc Endosc. 1992; 2:53-8.
8. Laparoscopic versus open repair of groin hernia: a randomised comparison. The MRC Laparoscopic Groin Hernia Trial Group. Lancet 1999 Jul 17;354(9174):185-90.
9. Wellwood J , Randomised controlled trial of laparoscopic versus open mesh repair for inguinal hernia: outcome and cost. BMJ. 1998 Jul 11;317(7151):10310.
10. Prospective randomised controlled trial of laparoscopic versus open inguinal hernia mesh repair: five year follow up, BMJ 2003;326:1012.
11. Wellwood J, Sculpher MJ et al. (1998) Randomised controlled trial of laparoscopic versus open mesh repair for inguinal hernia: outcome and cost. Br Med J 317: 103–110.
12. Pironi D, Open mesh technique versus laparoscopic transabdominal preperitoneal (TAPP) approach in inguinal hernia repair. Our experience, G Chir. 2008 Nov-Dec;29(11-12):497-504.
13. Bower, Steven, Moore, Barry B., Neuralgia after inguinal hernia repair, American Surgeon, 00031348. 1996; 62(8).
14. Page B, Paterson C, Young D, O'Dwyer PJ. Pain from primary inguinal hernia and the effect of repair on pain. Br J Surg 2002; 89(10): 1315-1318.
15. Schmedt CG, Sauerland S, Bittner R. Comparison of endoscopic procedures vs Lichtenstein and other open mesh techniques for inguinal hernia repair: a metaanalysis of randomized controlled trials. Surg Endosc 2005; 19(2): 188-199.
16. Andersson B, Hallen M et al. Laparoscopic extraperitoneal inguinal hernia repair versus open mesh repair: a prospective randomized controlled trial. Surgery 2003; 133(5): 464-472.