JMSCR Vol||04||Issue||09||Page 12569-12574||September 2016

www.jmscr.igmpublication.org
Impact Factor 5.244
Index Copernicus Value: 83.27
ISSN (e)-2347-176x ISSN (p) 2455-0450
crossref DOI: http://dx.doi.org/10.18535/jmscr/v4i9.44

IGM Publication
Journal Of Medical Science And Clinical Research
An Official Publication Of IGM Publication

Amyloidogenic Cast Nephropathy, Diagnosis, Treatment and Prognosis

(Case Report)

Authors

Lakshminarayana GR[1], Seethalekshmy NV[2], Raghunath KV[3], Indu S[4], Sheetal LG[5]

[1,3,4]Dept of Nephrology, EMS Memorial Cooperative Hospital and Research Centre, Perinthalmanna, Malappuram, Kerala, India

[2]Dept of Pathology, Amrita Institute of Medical Sciences and Research Centre, Kochi, Kerala, India

[5]Dept of Physiology, MES Medical College, Perinthalmanna, Malappuram, Kerala, India

Corresponding Author

Dr Lakshminarayana GR

Consultant Nephrologist,Department of Nephrology, EMS Memorial Cooperative Hospital and Research Centre, Perinthalmanna, Malappuram, Kerala, India-679322

Email: *drlng23@gmail.com, Phone: (+91)9495161833*

Abstract

We present a case of an elderly male with type 2 diabetes mellitus presenting with features of severe renal failure, which was detected to have unique type amyloidogenic cast nephropathy with lambda chain restriction and multiple myeloma. The presence of amyloidogenic casts is a rare occurrence which needs congo-red stain for its diagnosis. The amyloidogenic cast nephropathy portends poor renal outcomes as opposed to classical cast nephropathy.

Introduction

The multiple myeloma (MM) affects kidneys by diverse pathologic lesions with cast nephropathy being most frequent pattern of renal involvement.[1] Rarely these casts may show evidence of amyloidogenesis and assume a unique morphology, which needs to be appreciated for arriving at accurate diagnosis. [2-8]

Case Report

A male aged 61-year, known diabetic for 4 years, which was well controlled on oral hypoglycaemic agents, presented at another hospital with tongue swelling for 4 weeks and reduced food intake in the last 2 weeks. He underwent tongue biopsy, which showed hyperplasia with moderate dysplastic change in second week of December 2015. His serum (S) creatinine was 4.5 (normal 0.7-1.4) mg/dl during the initial evaluation.

He was admitted to EMS Memorial Co-operative Hospital and Research Centre for further evaluation on 22nd December 2015.His evaluation showed severe renal failure (S. Creatinine: 19.1 mg/dl & Blood urea: 250 mg/dl), urine showed mild proteinuria (Urine albumin: 1+), pyuria (plenty pus cells/hpf), 2-4 RBCs /hpf& granular casts. He also had anemia (Hemoglobin:8.7g/dl, normocytic normochromic) with high ESR (100mm/1hr; normal 0.0-20), hyperuricemia (9.5 mg/dl, normal 3.4-7.0), hyperphosphatemia (10.5mg/dl, normal 2.7-4.5), mild hyponatremia (126mmol/l, normal 136-145). He had mild

hypoalbuminemia (3.2g/dl, normal 3.9-4.9) with normal globulin (2.4 g/dl, normal 2.0-4.5); other liver parameters were normal. The serology for HIV, HCV, HbSAg (ELISA) were negative. Skeletal survey (X-Ray chest, skull and pelvis) did not show any lytic lesions. His ultrasound abdomen revealed normal sized kidneys with increased echogenicity with preserved corticome-dullary differentiation. The ECG and 2D-ECHO were normal.

He was started on antibiotics with suspicion of acute on chronic renal failure due to acute pyelonephritis with underlying diabetic nephropathy. The hemodialysis was initiated on next day (23/12/15) through right temporary dual lumen internal jugular catheter (IJC). Urine culture grew Enterobacter (20,000-25,000 cfu/ml), and was treated with sensitive antibiotic (Piperazillin+Tazobactum) for 7 days. He was continued on alternate day hemodialysis. Anemia was corrected with 2 units of blood transfusion. As the renal failure did not respond to culture sensitive antibiotics after 7 days, he underwent renal biopsy on 28/12/2015 after an informed consent.

The renal biopsy had 13 glomeruli of which one was obsolescent. Viable glomeruli were near normal in size and cellularity (Figure 1a, arrow) and 3 of them had periglomerular fibrosis. Peripheral capillary loops appeared delicate. There was no endocapillary proliferation or crescents. There was no Kimmelstiel-Wilson lesionorfibrin cap or capsular drop. Tubules revealed epithelial vacuolation, simplification and lumina showed pale eosinophilic fractured casts (Figure 1b, arrow). The cast were Schiff poor with radial lamellations on PAS stain (Figure 1c, arrow) and peripheral silver positive radial spicules on Silver stain (Figure 1d, arrow). Casts were congo red positive and showed apple green birefringence under polarized light (Figure 2a, arrow). The congo red stain was negative in glomeruli, interstitium and vessels. Some of the tubules revealed giant cell reaction and neutrophilic collection around the casts. Tubular atrophy and loss was seen in 30% of cortex with surrounding mild interstitial fibrosis. Interstitium also revealed moderate mononuclear infiltrate composed mainly of lymphocytes and a few plasma cells. Interlobular artery and arterioles appeared within normal limits. No large calibre artery were included in the biopsy. Tissue for immunofluores-cence (IF) study showed 3 glomeruli which reveal pseudolinear IgG. The stains for IgA,IgM,C3,C1q and both kappa and lambda light chains were negative in glomeruli, interstitium and tubular cells. Intratubular casts revealed strong lambda light chain positivity (Figure 2b, arrows) and stain for kappa light chain was negative (Fig 2c, arrow). He was diagnosed to have amyloidogenic cast nephropathy with lambda light chain restriction, mild chronic tubulointerstitial nephritis and nephrosclerosis with early diabetic nephropathy. The detailed myeloma evaluation was advised.

His serum electrophoresis (SEP) showed M Band and free light chain (FLC) assay showed predominant lambda elevation [lambda 3570 (normal 5.7-26.3) mg/L, kappa 56 (normal 3.3-19.4} mg/L], with kappa: lambda ratio of 0.02 (normal 0.26-1.65). Bone marrow showed hypercellular marrow with normoblastic maturation showing erythroid hyperplasia with moderate plasmacy-tosis (20%) (Hematoxylin and Eosin stain, Figure 2d, arrows). All the above features were conclusive of multiple myeloma.

He was seen by Oncologist and was started on Inj. Dexamethasone (40 mg OD x 4 days) and Inj. Bortezomib (2 mg/weekly doses). His urine output started improving from initial 500 ml to 3.5 L/day. He was discharged on 13/1/16 with an advice to continue chemotherapy and follow up in OPD for evaluating reversibility of renal functions. His renal parameters improved from S. Creatinine: 19.0 to 7.1 mg/dl over 3 weeks and hemodialysis was withheld. The weekly doses of Inj. Bortezomib (2 mg/weekly doses) and Inj. Dexamethasone 40 mg was given for 10 weeks along with H2 blockers, Febuxostat and Frusemide.

His chemotherapy (Inj. Dexamethasone and Inj. Bortezomib) was completed in march 2016, and SEP and FLC assay levels were reassessed. The SEPshowed only a faint M band, free lambda light levels had reduced from 3570 to 435 mg/L. He was continued on Linalidomide 25 mg daily along with other supportive measures. His renal parameters were stable (s. creatinine 7.5 to 8 mg/dl) and was clinically euvolemic and with urine output of 2.0-2.5 litres/day and he was regular follow-up.

He was readmitted in May 2016, with severe anemia (Hemoglobin: 7.2 g/dl, normocytic normochromic) which was corrected with packed RBC transfusion and was started onInj. Erythropoietin 4000 U S/C twice weekly.

He was readmitted on13/06/2016, with dyspnoea, edema, oliguria. On evaluation was found to have worsening renal parameters (S. Creatinine: 8.0 to 10.5 mg/dl) along with severe anemia (Hemoglobin: 7.4 g/dl). The right sided IJC (temporary) was inserted on 13.6.2016, anemia was corrected with 2 units PRBC. Need for re-biopsy of kidney was explained to the patient and relatives. He underwent left percutaneous renal biopsy on 15.6.2016.

The renal biopsy showed near normal glomeruli and amyloidogenic cast nephropathy with 50 % tubular atrophy and loss. His FLC assay showed increasing lambda (435 to 969mg/L) and kappa (26 to 56 mg/L) light chains.

He was reviewed by Oncologist was restarted on Inj. Bortezomib (2 mg/weekly doses), Dexamethasone (20 mg once weekly) & Thalidomide 100 mg (daily for 2 out of 4 weeks) from 23/6/2016. He is symptomatically better after a few sessions of hemodialysis and discharged on 24/6/16.

He was last seen on 05/09/2016, has received 6 weekly doses of (Bortezomib/Dexamethasone /Thalidomide). He was non-oliguric and S. Creatinine: has shown a marginal improvement (10.5--->9.1 mg/dl) and is off dialysis for last 6 weeks. His latest hemoglobin is 11.3g/dl on Erythropoietin and oral iron supplements.

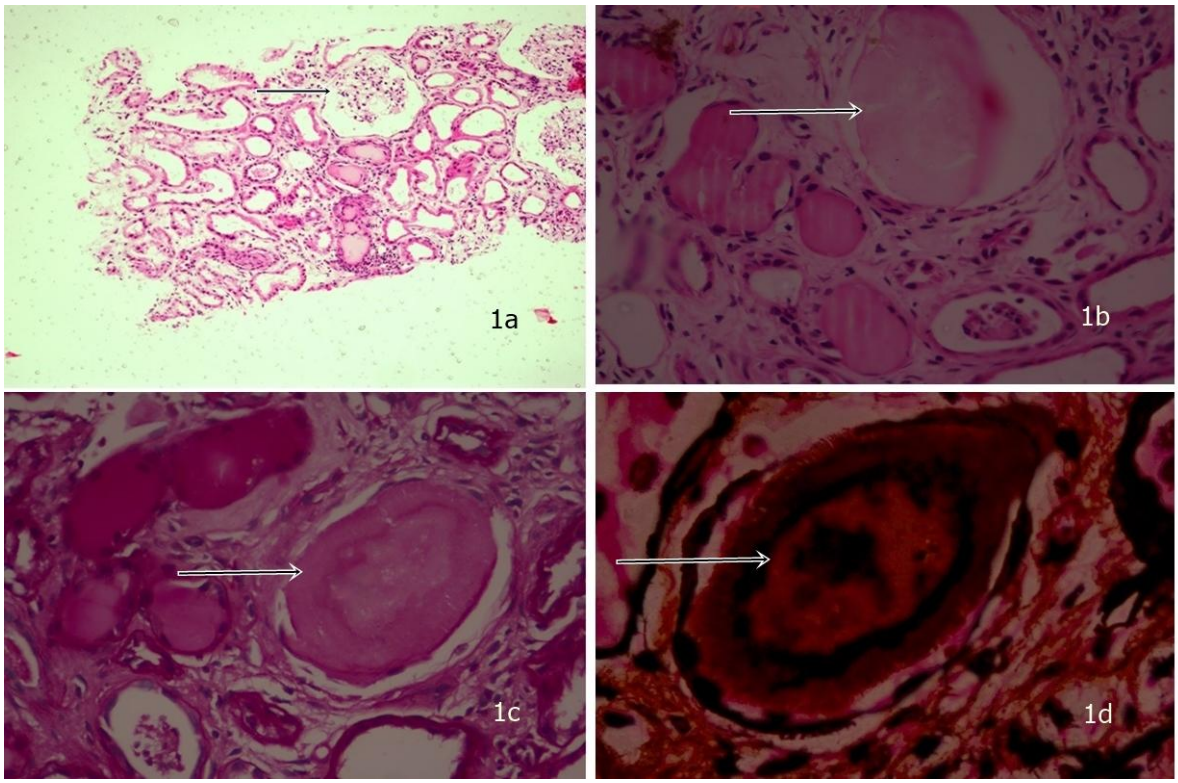

Figure 1: Viable glomeruli (arrow) were near normal in size and cellularity with delicate peripheral capillary loops (Figure 1a, Hematoxylin and Eosin) and tubules showing pale eosinophilic fractured casts (Figure 1b, arrow) which were Schiff poor with radial lamellations on PAS stain (Figure 1c, arrow) and peripheral silver positive radial spicules on Silver stain (Figure 1d, arrow)

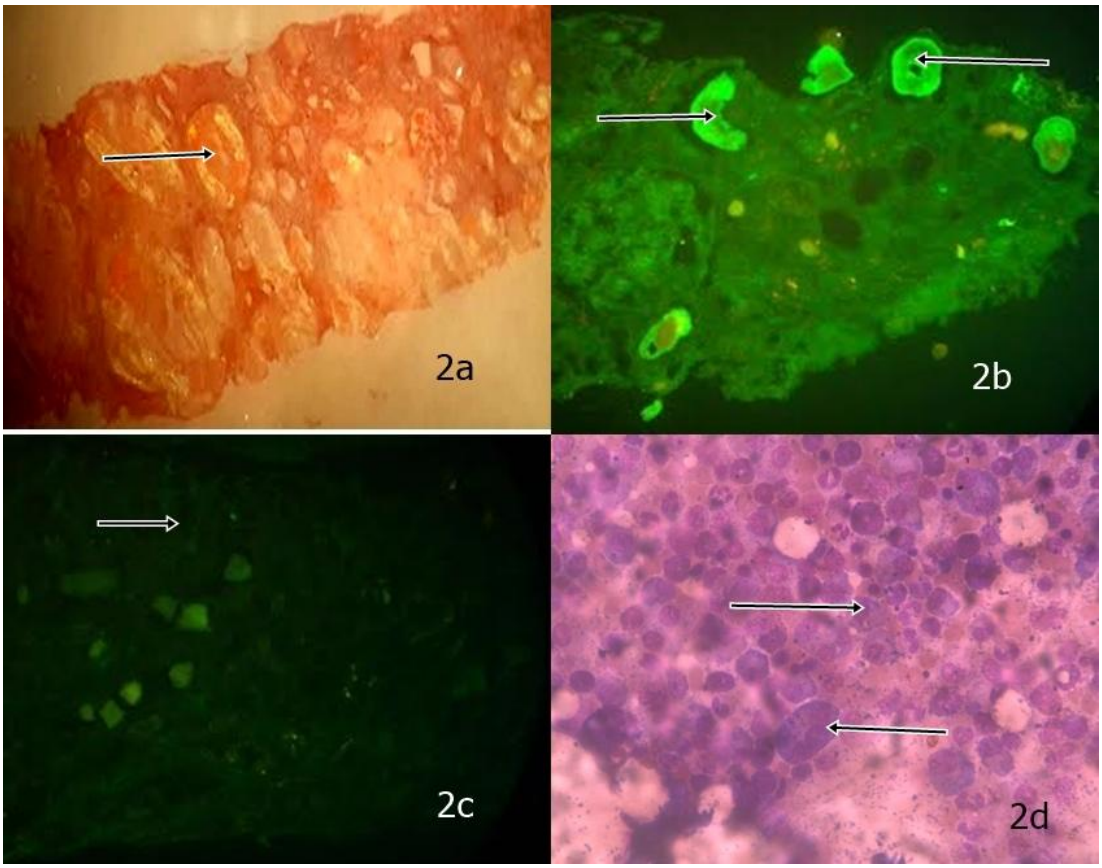

Figure 2: Congo red positive intratubular casts with apple green birefringence under polarized light (Figure 2a, arrow) and the casts showing strong lambda light chain positivity (Figure 2b, arrows) and stain for kappa light chain was negative (Figure 2c, arrow) and thebone marrow showing hypercellular marrow with moderate plasmacytosis (Hematoxylin and Eosin stain, Figure 2d, arrows).

Discussion

The multiple myeloma (MM) affects kidneys by diverse pathologic lesions with most common being cast nephropathy followed by amyloid light chain (AL) amyloidosis; monoclonal immune-globulin (Ig) deposition disease (MIDD); and, less frequently, cryoglobulinemic glomerulonephritis and proliferative glomerulonephritis.[1]

The diagnosis of cast nephropathy is based on the demonstration of tubular casts in the distal nephron that are composed of Ig light chains. The free kappa and lambda light chains have molecular weights of 22500 Dalton and 45000 D respectively are easily filtered across the glomerular filtration barrier. These filtered light chains form tubular casts by co-aggregating with the carbohydrate moiety of Tamm-Horsfall glycoprotein, which is produced in the thick ascending limb of the loop of Henle. The light chains usually form “brittle” or “fractured” casts which are intensely eosinophilic and they lodge themselves in tubular lumina causing cast nephropathy. [1]

Rarely, the tubular light chain casts show evidence of amyloidogenesis and one of earliest reports was associated with IgD myeloma. [2] The presence of tubular amyloid in patients with MM and cast nephropathy is rare with only few published reports. [2-8] The pathophysiology of intratubular amyloid remains unclear since amyloid fibrils are large and likely not filtered through the glomerular capillary walls.[3] One has to assume that the fibrils are formed inside the tubule either from secreted protein by the tubular cells or from filtered light chains. The later is more likely since it is the mechanism by which intratubular casts are formed in multiple myeloma. [1] Furthermore, two case reports suggest that amyloid may have been formed within the tubular epithelial cells from

reabsorbed immunoglobulin light chains and subsequently secreted into the tubular lumen. [3, 9]

The central pale area in these casts is composed of cellular and necrotic debris and occasionally the Tamm-Horsfallglyco protein, around which the amyloidogenic paraprotein. [8]

Renal pathologists need to have the knowledge regarding the occurrence of these type of casts as it can be missed if careful attention is not paid, thereby delaying or preventing an important diagnosis. Congo-red stains and electron microscopy are required to confirm the diagnosis. The uniqueness of our case is amyloidogenic cast nephropathy with lambda chain restriction in case of MM, without glomerular and vascular amyloid depositions.

Our case was treated with weekly doses of Bortezomib (2 mg/weekly doses, dose modified as per eGFR) and Dexamethasone 40 mg was given for 10 weeks, with good initial improvement in renal parameters (S. Creatinine:19.0 to 7.1 mg/dl)and urine volume (oliguric to 3.5 L/day), reduction in FLC levels and he was off hemodialysis after 3 weeks of therapy. He was continued on Linalidomide monotherapy (25 mg daily) along with other supportive measures after 10 weeks. His disease worsened while on Linalidomide with worsening renal parameters (S. Creatinine: 8.0 to 10.5 mg/dl), increasing FLC levels, along with severe anemia, needing re-initiation of hemodialysis and correction of anemia with blood transfusion. Chemotherapy was restarted with Bortezomib (2 mg /weekly doses), Dexamethasone (20 mg once weekly) & Thalidomide 100mg (daily for 2 out of 4 weeks). He was nonoliguric and off hemodialysis for the past 8 weeks with marginal improvement in renal parameters ((S. Creatinine: 10.5 to 7.9 mg/dl) at time of submission of the manuscript.

There is no specific treatment for amyloid cast nephropathy. In three of the reported cases of amyloid cast nephropathy (lambda restricted) associated with MM, they were treated with high dose Dexamethazone [3], Bortezomib [6] and CyBorD (cyclophosphamide, bortezomib and dexamethasone) regimen [7] respectively. The renal outcomes with the treatments was very poor and patients were dialysis dependant at the time of their publication [3,6,7] and one the patients expired within two weeks due to cardiac arrest [6]. In present case we noted an initial renal improvement (Bortezomib + Dexamethasone) followed by worsening when switched over to Linalidomide monotherapy and partial improvement in renal parameters after restarting triple drug therapy (Bortezomib Dexamethasone & Thalidomide).

References

1. Stephen MK and Melvin MS. Multiple Myeloma. JASN 2006; 17(9):2533-2545. DOI: 10.1681/ASN.2006020139.
2. Friman C, Tornroth T, Wegelius O: IgD myeloma associated with multiple extra medullary amyloid-containing tumours and amyloid casts in the renal tubules. Ann Clin Res1970; 2:161-166.
3. El-Zoghby Z, Lager D, Gregoire J, Lewin M, Sethi S: Intra-tubular amyloidosis. Kidney Int 2007; 72:1282-1288.
4. Melato M, Falconieri G, Pascali E, Pezzoli A: Amyloid casts within renal tubules: A singular finding in myelomatosis. Virchows Arch APatholAnatHistol 1980; 387:133-145.
5. Sethi S, Hanna MH, Fervenza FC: Unusual casts in a case of multiple myeloma. American Journal of Kidney Diseases 2009; 54(5): 970-974.
6. Nasr SH, Alobeid BB, Otrakji JA and Markowitz GS. Myeloma cast nephro-pathy, direct renal infiltration by myeloma, and renal extramedullary hematopoiesis. Kidney International (2008) 73, 517–518; DOI:10.1038/sj.ki.5002416.
7. Hideki K, Yoshihide F, Shinichiro A, Yutaka Y, Hiroshi U, Atsushi K, Michio N and Shunya U. Rapid deterioration of the renal function causedby the coexistence of intratubular amyloidosis and myeloma cast

nephropathy. Intern Med 54: 3023-3028, 2015. DOI: 10.2169/internal medicine. 54.5174.

8. Sharma A, Bansal S, Jain R. Unique morphology of intratubular light chain casts in multiple myeloma: The amyloid cast nephropathy. Indian J PatholMicrobiol 2014; 57:629-31.
9. Christopher PL, Scott BG and Patrick DW. Exceptional Case Amyloid proximal tubulopathy: a novel form of light chain proximal tubulopathy. Clin Kidney J (2012) 5: 130–132. DOI: 10.1093/ckj/ sfs004.