



Communication between the Branches of Brachial Plexus on Arm: A Cadaveric Study

Authors

Gautam Chandra Das¹, Amitav Sarma¹, Santosh Kumar Sahu², Ambath D. Momin¹, Gunamani Rabha³, Chandan Bongshiary⁴, Abdul Alim Ahmed³

¹Department of Anatomy, NEIGRIHMS, Shillong, Meghalaya, India

²Department of Anatomy, JMCH, Jorhat, Assam, India

³Department of Anatomy, GMCH, Guwahati, Assam, India

⁴Department of Anatomy, FAAMCH, Barpeta, Assam, India

*Corresponding Author

Gautam Chandra Das, MD

Senior Resident Doctor, Department of Anatomy, North Eastern Indira Gandhi Regional Institute of Health and Medical Sciences (NEIGRIHMS), Shillong, Meghalaya, India

Email:- gautamchdas@gmail.com, Mobile no. : +91 94012 49945

Abstract

Aim of The Study: Communications between the branches of brachial plexus are commonly observed and it has a number of clinical and surgical implications. This study will provide information about variations of Brachial plexus and enable us to have better knowledge of the field during surgery to avoid neurological damages.

Material and Method: The study was conducted in the department of Anatomy, NEIGRIHMS, Shillong, Meghalaya in collaboration with Gauhati Medical College, Guwahati and Jorhat Medical College, Jorhat, Assam on 52 upper limbs during the routine dissections for the undergraduate students within the 2013 -14 and 2014 -15 academic year to examine the variations of Brachial plexus in the arm region. In the study, roots, trunks, divisions, cords, formation of nerves, level of origin of branches and variations in all were noted.

Result and Conclusion: In our study we found only four cases (7.7%) of communications between musculocutaneous and median nerves; otherwise we had not observed any variation in the nerves of brachial plexus in the arm region. The lengths of the communicating branches were measured with the help of measuring tape. These types of variations are important for the neurologists as well as orthopaedicians in dealing with patients of nerve entrapment syndromes of the upper limb.

Keywords: brachial plexus, communicating branch, median nerve, musculocutaneous nerve, variation.

INTRODUCTION

The brachial plexus is formed by the union of the ventral rami of the lower four cervical nerves (i.e C5, C6, C7, C8) and the greater part of the first thoracic ventral ramus (T1). The formation of the

plexus may sometimes prefixed by the contribution of C4 root or it may be post fixed by the contribution of T1. Roots C5 and C6 join to form upper trunk, root C7 forms the middle trunk and C8 and T1 join to form lower trunk. Each

trunk bifurcates into ventral and dorsal divisions. The lateral cord is formed by the union of ventral divisions of the upper and middle trunks. Medial cord is formed by the ventral division of the lower trunk while the posterior cord is formed by the union of the dorsal divisions of all the three trunks [1].

The median nerve (MN) is formed by the union of the terminal branch of the lateral (C5,C6,C7) and medial (C8,T1) cords of the brachial plexus and enters the arm lateral to the brachial artery and subsequently reaches the forearm by passing between the two heads of the pronator teres muscle. The musculocutaneous nerve (C5, C6, C7) is the continuation of the lateral cord of the brachial plexus. It pierces and supplies coracobrachialis, biceps and brachialis and then continues into the forearm as the lateral cutaneous nerve of the forearm [2, 3].

Several investigators have reported the variations in the formation of the brachial plexus and its terminal branches [4]- [6]. From the nineteenth century, it has been reported that communication between the musculocutaneous (MCN) and median nerve (MN) is more common than the communication between the other nerves of brachial plexus [7].

The variations in the course of the musculocutaneous nerve in relation to median nerve is more common, sometime it may run behind the coracobrachialis muscle or adhere for some distance to the median nerve and pass behind the biceps brachii muscle; some fibres of the median nerve may run in the musculocutaneous nerve [1],[8].

The present study was conducted to see the variations of the nerves of the brachial plexus in the arm region and to discuss its clinical significance.

MATERIAL AND METHOD

The study was conducted in the department of Anatomy, NEIGRIHMS, Shillong, Meghalaya in collaboration with Gauhati Medical College, Guwahati and Jorhat Medical College, Jorhat,

Assam on 52 dissected upper limbs from 26 cadavers (Male = 16 and Female = 10 numbers) [Department of Anatomy, Gauhati Medical College, Assam = 11 cadavers (male = 7, female = 4); Department of Anatomy, Jorhat Medical College, Assam = 10 cadavers (male= 6 and female = 4) and Department of Anatomy, NEIGRIHMS, Shillong, Meghalaya = 5 cadavers (male= 3 and female= 2)] during the routine dissections for the undergraduate students in 2013-14 and 2014-15 academic year.

OBSERVATIONS AND RESULTS

In our study, we observed only four cases where MCN gave communicating branch to MN in the arm region. We had not detected any other variations of nerves of brachial plexus in the arm.

Case no. (1)

In a cadaver of around 54 years old male dissected at the department of Anatomy, Gauhati Medical College, Assam an anomalous communication between musculocutaneous and median nerve was noticed in the right upper limb (Fig.1). The communicating branch arose from the musculocutaneous nerve at a distance of 6.5 cm from the tip of coracoid process on right side and joined the median nerve at a distance of 19 cm from the same bony point.

The length of the communicating branch was 12.5 cm from the arising point to the communicating point.

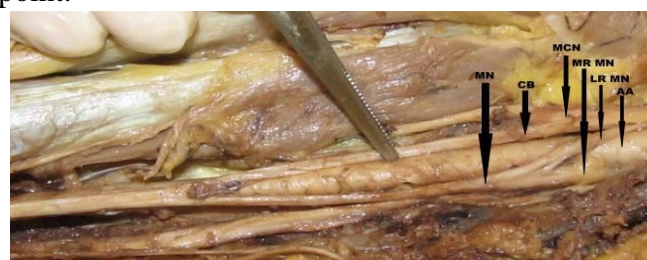

Fig. 1: Photograph showing communication between musculocutaneous and median nerve in right side. (MN- Median Nerve, CB- Communicating Branch, MCN-Musculocutaneous Nerve, LRMN-Lateral Root of Median Nerve, MRMN-Medial Root of Median Nerve, AA- Axillary Artery)

Case no. (2)

In an another cadaver of around 60 years old female, dissected at the department of Anatomy, Gauhati Medical College, Assam, a communicating branch was observed between musculocutaneous and median nerve in the left upper limb (Fig.2). The communicating branch arose from the musculocutaneous nerve at a distance of 8.5 cm from the tip of coracoid process on left side and joined the median nerve at a distance of 24.5 cm from the same bony point. The length of the communicating branch was 16 cm from the arising point to the communication point.

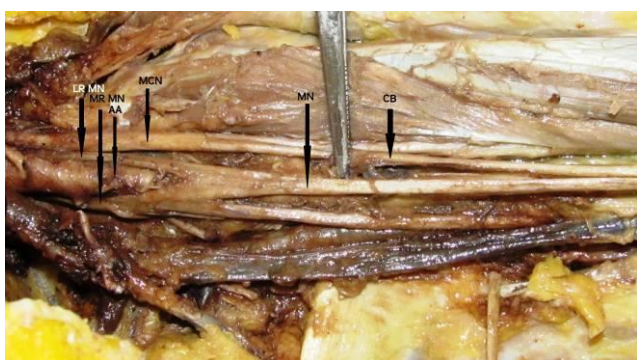


Fig. 2: Photograph showing communication between musculocutaneous and median nerve in left side. (MN- Median Nerve, CB- Communicating Branch, MCN-Musculocutaneous Nerve, LRMN-Lateral Root of Median Nerve, MRMN-Medial Root of Median Nerve, AA - Axillary Artery)

Case no. (3)

In an another cadaver of around 70 years old male, dissected at the department of Anatomy, Jorhat Medical College, Assam the communication between musculocutaneous and median nerve was detected in the left upper limb (Fig. 3). The communicating branch arose from the musculocutaneous nerve at a distance of 5 cm from the tip of coracoid process on left side and joined the median nerve 23.5 cm from the same bony point. The length of the communicating branch was 18.5 cm from the arising point to the communication point.

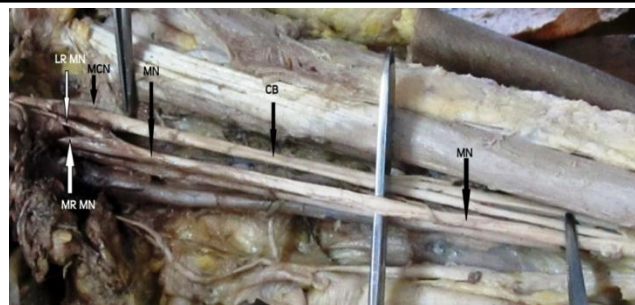


Fig. 3: Photograph showing communication between musculocutaneous and median nerve in left side (MN- Median Nerve, CB- Communicating Branch, MCN-Musculocutaneous Nerve, LRMN-Lateral Root of Median Nerve, MRMN-Medial Root of Median Nerve)

Case no. (4)

In an another cadaver of around 65 years old female, dissected at the department of Anatomy, NEIGRIHMS, Shillong, Meghalaya one communicating branch between musculocutaneous and median nerve was detected in the right upper limb (Fig.4). The communicating branch arose from the musculocutaneous nerve at a distance of 5.5 cm from the tip of coracoid process on right side and joined the median nerve 22.7 cm from the same bony point. The length of the communicating branch was 17.8 cm from the arising point to the communication point.

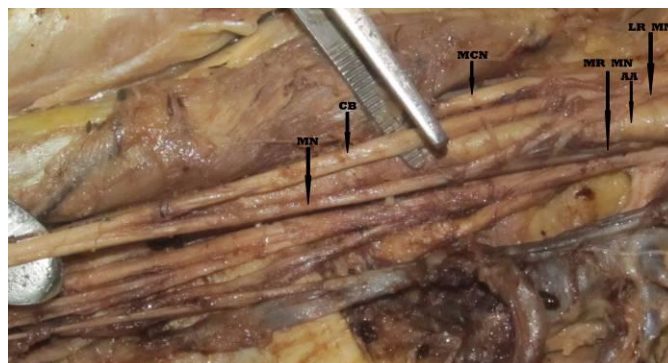


Fig. 4: Photograph showing communication between musculocutaneous and median nerve in right side. (MN- Median Nerve, CB- Communicating Branch, MCN-Musculocutaneous Nerve, LRMN-Lateral Root of Median Nerve, MRMN-Medial Root of Median Nerve, AA- Axillary Artery)

DISCUSSION

Various authors examined connections between the median and musculocutaneous nerves. Knowledge of anatomical variation of these nerves in the axilla or in the arm is essential for neurologists, neurosurgeons as well as for orthopaedicians^[9]. Even though the communications between the different nerves in the arm are rare but Harris was the first person to report about the communication between MCN and MN^[7]. Since then, more investigators have performed different studies to estimate the incidence of communication between these two nerves to impart more clinico-surgical knowledge about the variation. In the present study, we found the incidence of variation 7.7%. It is compared with the previous studies from the years 1985 to 2016 with the incidence of variation ranges from 1.4 to 63.5% (Table 1).

Table1: Showing the incidence of communication between the musculocutaneous nerve and the median nerve.

| Sr No | Author | Year | Incidence (%) |
|-------|---|------|---------------|
| 1 | Watanabe <i>et al.</i> ^[10] | 1985 | 01.4 |
| 2 | Kosugi, Mortia and Yamashita ^[11] | 1986 | 21.8 |
| 3 | Venieratos and Anagnostopoulou ^[12] | 1998 | 13.9 |
| 4 | Choi <i>et al.</i> ^[13] | 2002 | 26.4 |
| 5 | Loukas and Aqueelah ^[14] | 2005 | 63.5 |
| 6 | Guerri-Guttenberg and Ingolotti ^[15] | 2009 | 53.6 |
| 7 | Maeda <i>et al.</i> ^[16] | 2009 | 41.5 |
| 8 | Present study | 2016 | 07.7 |

The communication between the MCN and the MN have been classified in different types by Li Minor^[17], Loukas M *et al.*^[14] and Venieratos and Anagnostopoulou^[12].

Li Minor categorized these communications into following five type:

Type I - there is no communication between the MN and the MCN,

Type II - the fibers of the lateral root of the MN pass through the MCN nerve and join the MN in the middle of the arm,

Type III - the lateral root fibers of the MN pass along the MCN and after some distance, leave it to form the lateral root of the MN.

Type IV - the MCN fibers join the lateral root of the MN and after some distance the MCN arises from the MN.

Type V - the MCN is absent and the entire fibers of the MCN pass through the lateral root and fibers to the muscles supplied by MCN branch out directly from the MN.

Loukas M *et al.* classified the communications after dissecting 129 formalin fixed cadavers.

Type I - the communications were proximal to the point of entry of the musculocutaneous nerve into the coracobrachialis,

Type II - the communications were distal to the point of entry of the musculocutaneous nerve into the coracobrachialis,

Type III - the musculocutaneous nerve did not pierce the coracobrachialis.

Type IV - the communications were proximal to the point of entry of the musculocutaneous nerve into the coracobrachialis and additional communication took place distally.

Venieratos and Anagnostopoulou had classified the communications between musculocutaneous and median nerves into three types considering the coracobrachialis muscle as the reference point.

Type I - the communication was proximal to the entrance of the musculocutaneous nerve into the muscle.

Type II - the communication was distal to the muscle.

Type III - the nerve and the communicating branch did not pierce the muscle.

Abnormal communication between peripheral nerves can be explained by defective embryological basis where some arbitrary factors influence the mechanism of formation of limb muscles and the peripheral nerves during embryonic life. It is observed that the variations in nerve patterns may be due to altered signalling between mesenchymal and neuronal growth cones^[18] or circulatory factors at the time of fusion of brachial plexus cords^[19].

The presence of such nerve communications are not just confined to man, studies on comparative anatomy have reported the existence of such connections in monkeys and in some apes. Thus suggesting that communications may represent the primitive nerve supply of anterior arm muscles^[5]. Though the cause for the existence of communication between these nerves is arbitrary, knowledge of these variations provides more information to the clinician for proper assessment of the case, otherwise complication may arise during various surgical approaches in this area.

CONCLUSION

Communications between the musculocutaneous and the median nerves are one of the commonest neuroanatomical variations of the brachial plexus in the axilla and arm region. Knowledge of the anatomical variations of these nerves is essential to perform various surgical interventions in the axilla and the surgical neck of the humerus.

Conflict-of-interest: None of the authors have any conflicts of interests and no financial disclosure

REFERENCES

1. Standring S. Gray's anatomy. The anatomical basis of clinical practice. 40th ed. London: Elsevier Churchill Livingstone; 2008;780-781.
2. Romanes, G. J. Cunningham's manual of practical anatomy (Upper and lower limbs), Oxford Medical Pub, 1986;15(1): 3
3. Singh V. Textbook of Anatomy. Upper limb and Thorax, Vol. I, 2nd ed. Elsevier India Private Limited. 2014;53.
4. Kerr, AT. The brachial plexus of nerves in man, the variations in its formation and branches. American Journal of Anatomy, 1918; 23(2): 285-395.
5. Miller, RA. Comparative studies upon the morphology and distribution of the brachial plexus. American Journal of Anatomy, 1934; 54(1):143-166.

6. Bergman, RA., Afifi, AK., Miyauchir, RA. Illustrated encyclopedia of human anatomic variation. In: NERVOUS system – plexusses. 1988. Available from: <http://virtualhospital.com.universityofiowacare>.
7. Harris, W. The true form of the brachial plexus. Journal of Anatomy and Physiology, 1904; 38: 399-422.
8. Moore KL, Dalley AF. Clinically oriented anatomy. 4th ed. Philadelphia: Lippincott Williams & Wilkins; 1999.
9. Leffert RD. Anatomy of the brachial plexus. New York: Churchill Livingstone; 1985: 384
10. Watanabe, M., Takatsuji, K., Sakamoto, N., Morit, Y., Ito, H. Two cases of fusion of the musculocutaneous and median nerves. Kalbo gaki Zasshi, 1985; 60:1-7.
11. Kosugi, K. Mortia, T., Yamashita, H. Branching pattern of the musculocutaneous nerve. 1. Cases possessing normal biceps brachii. Jikeikai Medical Journal, 1986; 33:63-71.
12. Venieratos, D., Anagnostopoulou, S. Classification of communications between the musculocutaneous and median nerves. Clinical Anatomy, 1998;11:327-331.
13. Choi D, Rodriguez-Niedenfuhr M, Vazquez T, Parkin I, Sanudo JR. Patterns of connections between the musculocutaneous and median nerves in the axilla and arm. Clin Anat. 2002; 15: 11–17.
14. Loukas, M., Aqueelah, H. Musculocutaneous and median nerve connections within, proximal and distal to the coracobrachialis muscle. Folia Morphologica (Warsz), 2005; 64(2):101-8.
15. Guerri-Guttenberg, RA., Ingolotti, M. Classifying musculocutaneous nerve variations. Clinical Anatomy, 2009; 22(6): 671-83.
16. Maeda, S., Kawai, K., Koizumi, M., Ide, J., Tokiyoshi, A., Mizuta, H., Kodama, K. Morphological study of the communication between the musculocutaneous and

median nerves. Anatomical Science International, 2009;84(1-2):34- 40.

17. Li Minor, JM. A rare variant of median and musculocutaneous nerves in man. Archives Anatomy Histology Embryology, 1992;73:33-42.
18. Kosugi K, Morita T, Koda M, Yamashita H. Branching pattern of the musculocutaneous nerve. 1. Case possessing normal biceps brachii. Jikeikai Med J. 1986; 33:63–71.
19. Sanes HD, Reh TA, Harris WA. Development of the nervous system. 1st Ed. New York, Academic Press. 2000; 189–197.