



Unusual Causes of Large Bowel Perforation – A Report of Three Cases

Authors

Govindappa Saroja Murali, Shubhakar Bhandary

Department of General Surgery, K.S. Hegde Medical Academy
Nithyanandanagar, Deralakatte, Mangalore – 18, Karnataka State, India.

Corresponding Author

Govindappa Saroja Murali

Email: drmurali66007@gmail.com, Phone No: +91-9731922773

Abstract

Large bowel perforations are commonly caused due to malignancy and inflammatory disorders. Large bowel perforations due to causes like stercoral perforation, idiopathic perforation and spontaneous perforation associated with rectal prolapse are very rare. Though uncommonly seen, these perforations are managed clinically in a similar way as perforations due to other causes with differences in managing the underlying condition. The type of surgical intervention required depends on a variety of factors like the duration, amount of fecal contamination, patient's general condition and the underlying pathology. We report such three cases of very rare causes of perforation of large bowel with review of literature.

Introduction

The incidence of large bowel perforation as compared with small bowel perforation is less. Common causes of large bowel perforation include malignancy and inflammatory disorders. Certain uncommon causes have been reported like stercoral perforation and idiopathic perforation. An early recognition and intervention would offer a better chance at reducing the mortality. Management of these patients has undergone a drastic change from staged procedures like colostomy to a primary definitive surgery. With the advent of better antibiotics and surgical options the morbidity and mortality in these patients has been reduced by a significant margin. Nonetheless it still carries a high mortality due to spillage of fecal matter and associated gram negative sepsis.

Case Reports

Case 1: 35 year old man presented to casualty with history of sudden onset pain in lower abdomen with herniation of bowel loops through anal canal. This had happened at the act of defecation and presented to the hospital within an hour of the incident. He had history of rectal prolapse since 2yrs and had not sought any medical attention. On examination he had hypotension and generalized abdominal tenderness. Per rectal examination showed loops of small bowel protruding through the anus (Figure 1). After initial resuscitative measures he was posted for an emergency surgery. At surgery perineum inspection revealed no injuries or defects. Laparotomy revealed a tear in the anterior wall of sigmoid measuring about 10 cms through which bowel loops had herniated out (Figure 1,

inset). The bowel loops were reduced and tear in sigmoid colon was sutured. The patient recovered and was discharged. Definitive surgery for prolapse was done after 6 weeks.

Case 2: 65 year old lady presented with diffuse pain abdomen of 3 days duration. She had history of chronic constipation for which was on laxatives. On examination she was in shock and had features suggestive of peritonitis. Her total leukocyte count was high. Erect abdominal X ray showed pneumoperitoneum suggestive of hollow viscus perforation. She underwent emergency laparotomy. At surgery she was found to have a perforation at the recto-sigmoid junction (Figure 2). The perforated segment was gangrenous and there was contamination with bolus of fecal matter. The gangrenous segment was resected with end to end anastomosis and peritoneal lavage was given. The patient recovered well and was discharged later.

Case 3: A 60 year old lady presented with non-healing ulcer over her left supraclavicular area of 1 year duration. She was started on anti-tubercular therapy after the ulcer biopsy showed caseating granulomas. The ulcer started responding well to treatment and on day 5 of hospital admission she developed sudden onset pain abdomen with abdominal distention. Erect X ray of the abdomen revealed pneumoperitoneum and she underwent an emergency laparotomy. Laparotomy revealed a perforation in the transverse colon (Figure 3). Segmental resection of the transverse colon was done. Histopathological examination of the specimen failed to reveal any granulomas in it.

Figure 1. Eviscerated bowel loops per rectum; tear in anterior rectal wall (inset)

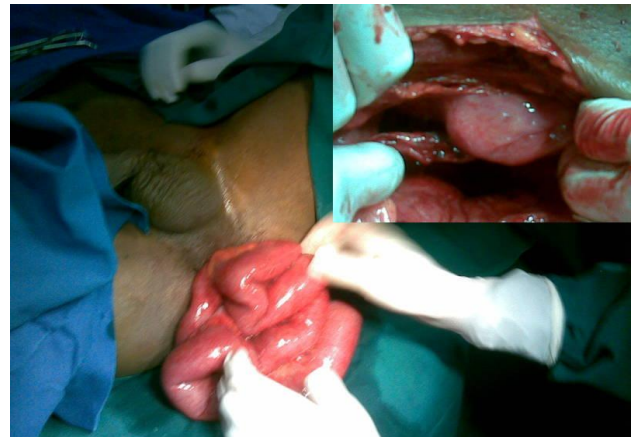


Figure 2 Perforation at the recto-sigmoid junction

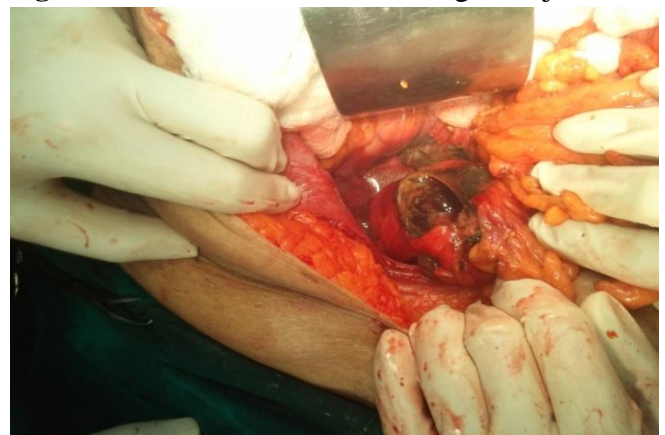
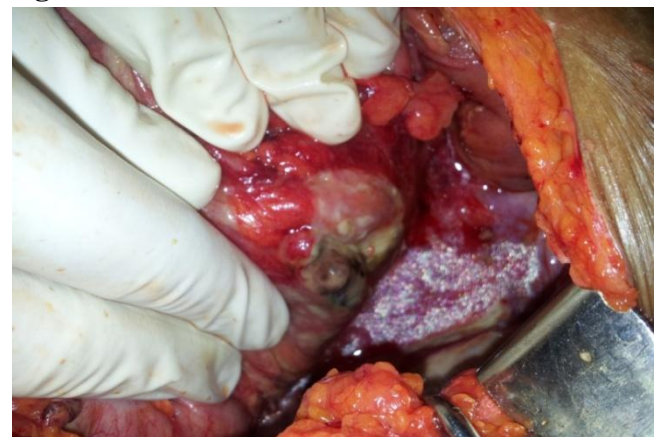
Figure 3. Perforation in the transverse colon



Discussion

Recto-sigmoid rupture with prolapse of bowel through the anus is a rare condition and an emergency. The etiology is unknown and most can be distinguished from traumatic injuries to the rectum. The term “spontaneous rupture” describes those with no specific etiology ^[1,2]. Most often it

occurs due to preceding prolapse common among these patients. There occurs a sudden increase in intra-abdominal pressure during defecation as well as local disturbance in circulation^[3,4]. Two factors predispose the patients to this unusual complication – sudden increase in intra-abdominal pressure and presence of rectal prolapse. Most believe that the primary mechanism of prolapse is a sliding hernia in which pouch of Douglas and the contained viscera form the hernia sac which invaginates the anterior wall of rectum resulting in weakening of the rectal wall^[4,5]. Bowel is examined for viability after reduction in the peritoneal cavity. The treatment of choice is repair or resection of the ruptured segment depending on the degree of contamination and patient's condition. Alternatively a Hartmann operation may be needed, with restoration of bowel continuity at a later stage^[4]. Herniation of small bowel through the colon results in obstruction of the lumen of ruptured recto-sigmoid, blocking the passage of colonic contents into the peritoneal cavity and development of fecal peritonitis^[3,4,5]. This rare condition can be prevented by elimination of the precipitating factor - rectal prolapse.

Stercoral perforation has been defined as perforation of the large bowel due to pressure necrosis from fecal masses. It is recognized as a rare cause of colonic perforation. Most patients report a history of chronic constipation, as well as straining bowels as a precipitant event^[6]. There have been case reports of stercoral perforation in association with antipsychotics, tricyclic antidepressants, verapamil, aluminum-based antacids, immunosuppressive agent safterrenal transplants, non steroid anti-inflammatory drugs (NSAIDs), and opioids including codeine, heroin, and methadone. These drugs are thought to affect colonic motility^[7,8]. Pathophysiologic basis of idiopathic perforation is unknown. Several pathogenetic factors are considered responsible for idiopathic perforation of colon, like constipation, raised intra-abdominal pressure, intraluminal pressure, but nothing has been proved

yet. Idiopathic colonic perforation usually is linear, with broken ends of muscular layer regular, and histology is normal^[9,10].

Large bowel perforation may lead to early septicemic shock and multiple organ failure. So patients need to undergo surgery as soon as the disease is diagnosed. The types of surgeries are different depending upon the time of onset, degree of peritonitis and general physical conditions. The treatment includes primary closure with or without colostomy, bowel exteriorization, resection anastomosis with or without covering colostomy or Hartmann procedure.

References

1. Papapolychroniadis C, Kaimakis D, Giannoulis K, Parlapani A, Karpini E, Georgiou M, Giala M, Harlaftis N. Spontaneous rupture of the rectosigmoid with small bowel evisceration through the anus. *Tech Coloproctol* 2004; 8:126–8.
2. Morris AM, Setty SP, Standage BA, Hansen PD. Acute transanal evisceration of the small bowel: report of a case and review of the literature. *Dis Colon Rectum* 2003;46:1280–3.
3. Walsh T, O'Brien D, Khawaja N, Ryan R, Lenehan P. Bowel evisceration. *Ir Med J* 2004; 97:20–21.
4. JoonJeong, JoonSeong Park, Chang GyoByun, Dong Sup Yoon, Seung Kook Sohn, Yoon Ho Lee, Hoon Sang Chi. Rupture of the rectosigmoid with evisceration of the small bowel through the anus. *Yonsei Medical Journal* 2000;41(2):289-92.
5. Hovey MA, Metcalf AM. Incarcerated rectal prolapse – rupture and ileal evisceration after failed reduction. *Dis Colon Rectum* 1997;40:1254-7.
6. T. D. Haley, C. Long, and B. D. Mann. Stercoral perforation of the colon: a complication of methadone maintenance. *Journal of Substance Abuse Treatment* 1998;15(5):443–444.

7. D. J. Tessier, E. Harris, J. Collins, and D. J. Johnson. Stercoral perforation of the colon in a heroin addict. *International Journal of Colorectal Disease* 2002; 17(6):435–437.
8. R. Haddad, G. Bursle, and B. Piper. Stercoral perforation of the sigmoid colon. *ANZ Journal of Surgery* 2005;75(4):244–246.
9. Basile M, Montini F, Cipollone G, Errichi BM. Spontaneous perforation of large intestine. *Ann ItalChir* 1992;63(5):625–629.
10. Kasahara Y, Matsumoto H, Umemura H, Shirafa S, Kuyam. Idiopathic perforation of sigmoid colon in Japan. *World J Surg* 1981;5(1):125–128.