



Peripheral Cementifying Fibroma – A Dilemma

Authors

Dr Sivaprasad K K¹, Dr Anila Karunakaran², Dr Leena Philipose³

¹Senior Resident, Dept of Dentistry, Govt Medical College, Palakkad, Kerala, India

²Professor and Head, Dept of Dentistry, Govt Medical College, Palakkad, Kerala, India

³Assistant Professor, Dept of Dentistry, Govt Medical College, Palakkad Kerala, India

Corresponding Author

Dr Sivaprasad K .K

Senior Resident, Dept of Dentistry, Govt Medical College, Palakkad, Kerala, India 678013

Email- sivaprasadkk70@gmail.com, Contact -+91 9048397083

ABSTRACT

Solitary gingival enlargements possess a great diagnostic dilemma to the clinicians due to the similarity in their clinicopathological presentation. These enlargements are commonly referred to as fibro-osseous lesion of the jaws. Some clinicians use same terminology for apparently quite different lesion and others give same diagnosis using variable histological profile. Peripheral cementifying fibroma is one of the lesion that possess a great diagnostic dilemma to the clinicians due to its clinicopathological presentation and variable terminology. Peripheral cementifying fibroma is a reactive gingival overgrowth, commonly encountered in anterior maxillary region. We report a case of Peripheral cementifying fibroma in 51 year old female.

Keywords: Solitary Gingival enlargement, Peripheral Cementifying Fibroma

Introduction

Soft tissue gingival swellings often present a diagnostic dilemma with their similar clinical presentation and diverse range of etiology that can produce these kinds of lesions. A solitary gingival enlargement is usually a reactive process rather than a true neoplasm. A fibroma refers to soft tissue benign neoplastic growth due to over production of fibrous tissue in connective tissue. In 1872 Menzel described ossifying fibroma but in 1927 Montgomery was the one who gave a terminology to it¹, in 1972 peripheral fibroma term was coined by Eversole and Rovin². Peripheral cementifying fibroma (PCF) is described as a reactive focal overgrowth of gingival tissue.

Peripheral fibroma with cementogenesis, Peripheral fibroma with osteogenesis, Peripheral fibroma with calcification, calcifying or ossifying fibrous epulis and calcifying fibroblastic granuloma are the various synonyms of PCF³.

Case Report

A 51 year old female reported with complaint of a swelling involving the upper front region since 1 year. She considered treatment for the esthetic reason only, as the swelling increased in size in the past few months. The solitary growth was of 3cm x2cm in size, firm, non tender, sessile involving the attached gingival of the upper right central incisor. The surface of the growth was

smooth and erythematous (Fig 1). Periodontal status was moderate with calculus and soft debris was present. There was no mobility of involved tooth. Radiographic evaluation revealed horizontal bone loss in upper central region (Fig 2). She was not having any systemic illness. Routine blood examinations were within normal limit. After the clinical and radiographic evaluation a provisional diagnosis of irritational fibroma was made. Excisional biopsy was planned along with full mouth prophylaxis and root planning. Under local anesthesia excision of the growth was carried out, intraoperative and postoperative periods were uneventful. The patient was kept under regular follow up. Histopathological examination revealed clusters of globular cementum like material in acellular connective tissue stroma. Plum active fibroblasts are seen with scanty inflammatory cells. Section shows moderate vascularity (Fig 3). Considering the clinical, radiographic and histopathological examination a final diagnosis of Peripheral cementifying fibroma was made. The patient was kept under regular follow up (Fig 4).

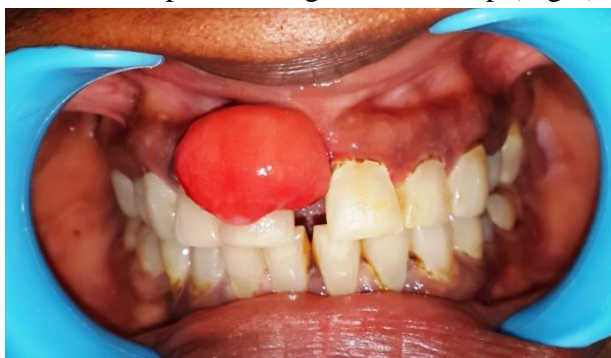

Fig 1 Preoperative View

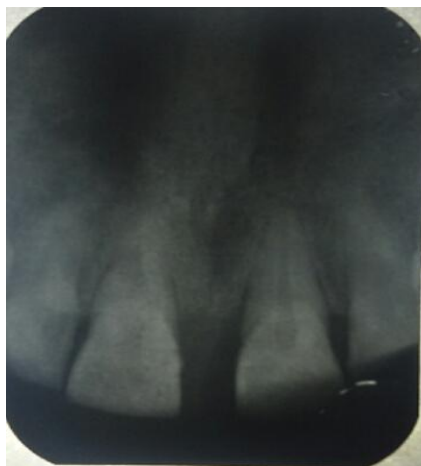

Fig 2 Radiographic View

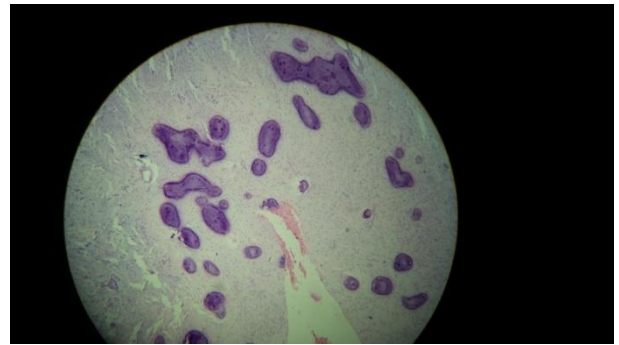


Fig 3 Histopathological View

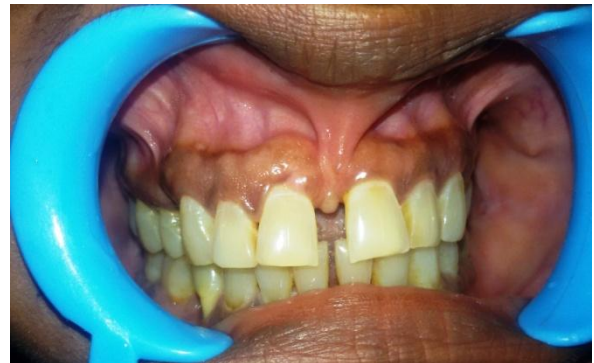

Fig 4 Postoperative View (6 Months)

Discussion

Solitary gingival swellings are always a point of diagnostic dilemma, due to their similarity in clinical presentation and varying histopathological presentation. The varying nomenclature also adds up to the confusion. Peripheral cementifying fibroma is a lesion of considerable controversy due to its nomenclature and pathogenesis. PCF comprises of 1%-3% of the gingival lesions^{4,5,6,7}, with a peak incidence in 2nd and 3rd decade of life having a female predilection⁸. PCF is encountered more often in maxillary anterior region (55%-60%)⁹. Etiopathogenesis includes trauma or local irritants including calculus and plaque¹⁰. PCF may be pedunculated or sessile with a smooth or ulcerated surface having a color range from pink to red, rarely associated with migration of teeth with bone loss^{9,11}. Duration of the lesion may vary from few months to several years and radiographically lesion may be associated with no bony changes to destructive changes in the bone¹². Microscopically three types of tissues are seen in solitary gingival lesions that are dystrophic calcification, bone and cementum like material.

The varying histological presentation results in confusion in the nomenclature. Differentiation of bone and cementum histological is very difficult and it has been suggested that the changes in the microscopic presentation may due to the evolution of a lesion from fibrous to fibrous stages to cementoid stage¹³.

The present case describes a 3cm x 2cm smooth surface, erythematous, solitary lesion in the maxillary incisor region of a female in her 5th decade of one year duration, that was initially diagnosed as fibroma and after histopathological examination revealed cementum like material leading to the final diagnosis of peripheral cementifying fibroma was made. Management of the PCF is surgical excision intoto along with the removal of irritational factors associated with the lesion. Patient need to be kept under long follow up period as recurrence rate as reported by various authors are 9%⁴,16%¹⁴,20%¹⁵

References

1. Yadav A, Mishra MB. Peripheral cementoossifying fibroma of the mandible: A case report .Indian J Stomatol 2011; 2(3),193-6
2. Suchetha A, Veerendra Kumar, Deepika J.A case report on peripheral cementifying fibroma. Journal of Indian Academy of Dental Specialists 2011;2;43-5
3. Shafer WG, Hine MK, Levy BM. A Textbook of oral pathology.4th ed, Philadelphia: Saunders Co. 1983:292-4.
4. Cuisia ZE, Brannon RB. (2001). Peripheral ossifying fibroma- a clinical evaluation of 134 pediatric cases. Pediatr Dent, 23, 245-248.
5. Bhaskar SN, Jacoway JR. (1966). Peripheral fibroma and peripheral fibroma with calcification: Report of 376 cases. J Am Dent Assoc, 73, 1312-20.
6. Kenney JN, Kaugars GE, Abbey LM. (1989). Comparison between the peripheral ossifying fibroma and peripheral odontogenic fibroma. J Oral Maxillofac Surg, 47(4), 378–82
7. Das S, Das AK. (1993). A review of pediatric oral biopsies from a surgical pathology service in a dental school. Pediatr Dent, 15(3), 208–11.
8. Iqbal Ali, Gazala Parveen, Sameer Singh, Manish Dubey, Akheel M.D. (2014). Peripheral Ossifying Fibroma of Maxilla: A case report & Review. Journal of Head & Neck physicians and surgeons, 2(2), 128-35.
9. Terry Farquhar, Jennifer Mac Lellan, Heather Dymont, Ross D. Anderson. (2008). Peripheral Ossifying Fibroma: A Case Report. Journal of Canadian dental association, 74, 809-12.
10. Santosh Kumar R,Sateesh C.P, Shreedhar A. (2011). Peripheral ossifying fibroma: a rarity in elderly males. Journal of dental sciences and research, 2, 62-3.
11. Suchetha A, Veerendra Kumar, Deepika J. (2011). A case report on peripheral cementifying fibroma. Journal of Indian Academy of Dental Specialists, 2, 43-5.
12. Kapoor H, Arora R. (2014). A Massive Peripheral Ossifying Fibroma Uncommon Presentation of a Common Lesion. Journal of Oral Health and Dental Management, 13, 940-5.
13. Batra H, Sharma N, Gulati N, Mohindra S. (2012). Peripheral Ossifying Fibroma - A Case Report. Indian Journal of dental sciences, 4, 70-2.
14. Pendyala G, Joshi S, Marawar PP, Pawar B, Mani A. (2012). Peripheral Ossifying fibroma:A case report. Parvara Med Rev, 4(2), 27-30
15. Eversole LR, Rovin S. (1972). Reactive lesions of the gingiva. J Oral Pathol, 1, 30-8.