



Severe Acute Pancreatitis Presenting As Appendicular Perforation- An Unusual presentation

(Case Report)

Authors

**Sudhansu Sekhar Sutar¹, Ranjit kumar Pati², Prasanta Kumar Dass³,
Debasis Das⁴, Madhusmita Jit⁵**

¹Dept of Gen. & G I Surgery, Tata Steel Medica Hospital, Kalinga nagar, Jajpur Road, Odisha-755026

Email: sudhansu.sutar@medicasynergie.in, Mobile: +918455867985

²Dept. of Anaesthesia & Emergency Medicine, Tata Steel Medica Hospital

Email: ranjit.pati@medicasynergie.in

³Department Of Emergency Medicine, Tata Steel Medica Hospital

Email: pkdass05@gmail.com

⁴Department Of Emergency Medicine, Tata Steel Medica Hospital

Email: devonemanarmy@gmail.com

⁵Department Of Emergency Medicine, Tata Steel Medica Hospital

Email: dr.madhusmitajit@gmail.com

ABSTRACT

Pancreatic & Peripancreatic fluid collection is a common complication of severe Acute Pancreatitis. But rarely it can lead to collections at remote sites in peritoneal, retroperitoneal, mediastinal or inguinoscrotal region and manifesting rare presentations.

Here is a case of a non alcoholic, non diabetic male, presented with abdominal pain, localized at right iliac fossa with rebound tenderness & features of peritonism. Ultrasonography of abdomen & pelvis shows moderate pelvic collection with internal echos & probe tenderness at right iliac fossa.

Patient was diagnosed as a case of Appendicular perforation. On Laparotomy the case was diagnosed as severe acute pancreatitis with secondary/ reactionary appendicitis with pancreatic ascitis, peri pancreatic & pancreatic parenchymal necrosis & pelvic retroperitoneal collection in right iliac fossa extending to the base of appendix.

The patient was managed with appendicectomy, draining of pelvic & retroperitoneal pelvic collection, debridement of necrotic fissure in pelvis in right iliac fossa towards right psoas muscle, debridement of patchy necrotic tissue over small bowel mesentery. Thorough irrigation, lavage & suctioning of necrotic & sloughed area on pancreas & peripancreatic tissue had also been done.

Key words: Acute Pancreatitis, Appendicular perforation.

Introduction

Formation of pseudocyst & fluid collection both in peritoneal & retroperitoneal spaces in abdomen & pelvis are common complication of severe Acute pancreatitis (SAP). Extra pancreatic fluid

collection are more often detected in lesser sac, anterior pararenal space, posterior pararenal space, around left lobe of liver & spleen. Extension to pelvis retroperitoneum is rare.

These sequale, sometime make difficult in the diagnosis of SAP in absence of classical history & physical findings, which is masked by the features of its complication.

Here we present a case of SAP with pelvic & retroperitoneal pelvic collection with reactionary appendicitis simulating as Appendicular perforation.

Case Report

A 22 yrs young male, non alcoholic, non diabetic presented with acute onset of spasmodic abdominal pain of 1 day duration with no history of vomiting or fever. He had h/o intermittent off & on pain abdomen lasting for minutes only, since last 1 month with no medication.

On examination patient was afebrile, non- icteric with normal blood pressure. There was diffuse abdominal tenderness, more marked in right iliac fossa with rebound tenderness & guarding. Haematologicaly, he was having marked leukocytosis only. USG of pelvis & abdomen revealed moderate pelvic peritoneal fluid with internal echos & probe tenderness in right iliac fossa. With these clinical, USG & haematological findings, patient was diagnosed as a case of appendicular perforation & Laparotomy was done with lower mid line incision.

On opening the peritoneum, about 500ml of coffee coloured free fluid was suctioned from the pelvis. There was a retroperitoneal collection of about 200ml thick dark brown turbid fluid in the pelvis in right side extending towards the base of appendix. The appendix was turgid & inflamed. There was no perforation. There were patchy saponification of small bowel mesentery, including mesoappendix. In the suspicion of pancreatitis, the incision was extended upwards to visualize the structure. On inspection, there was about 30% necrosis of head & body of pancreas. The following procedures were performed after identification of all intraabdominal pathologies.

Appendicectomy.

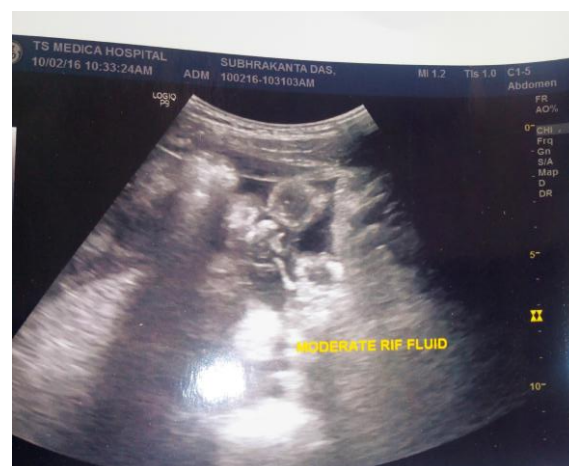Drainage of retroperitoneal collection & debridement of necrotic sloughed tissue from the cavity.

Debridement of patchy necrosis over small bowel mesentery.

Through irrigation, lavage & suctioning of necrosed & sloughed tissue over pancreas & peripancreatic tissue.

Post Laparotomy, the serum Amylase & Lipase were 1550 & 2500 U/L respectively. On 2nd postoperative day, drain fluid Amylase was 1250 U/L, conforming the condition. Patient was empirically started with Inj.Meropenem + sulbactam, Inj Netilmycin, Inj Metronidazole, Inj Pantoprazole, Inj Octreotide & other supportive treatment.

From post operative Day-1, patient had reduced urine output & intermittent spike of fever, which was managed as per protocol. From fourth day, he had normal Urine output & was afebrile. From the same day he was started oral feeds on reappearance of bowel sounds. On day 5, both the drain had minimal output with drain fluid amylase come down to 102 U/L. The drains were removed on 6th day after USG conformation of almost no residual collection in abdomen & pelvis. On day 8, patient was discharged with advice of regular follow up.



USG image of the patient showing moderate fluid in RIF with internal echos.

Figure 1

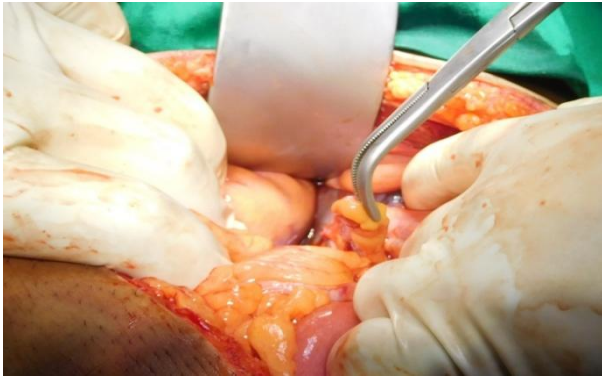


Fig.1 Clinical photograph showing inflamed Appendix, saponification of meso appendix with retro peritoneal pelvic collection

Figure 2

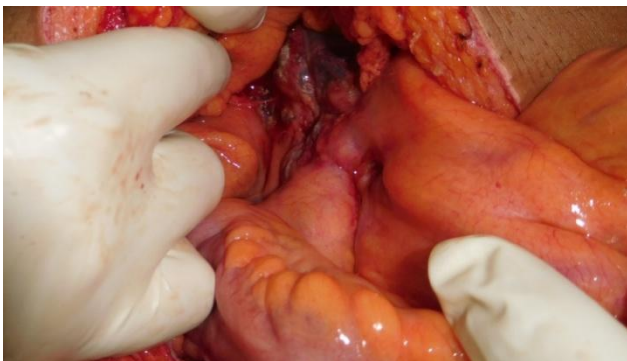


Figure 3

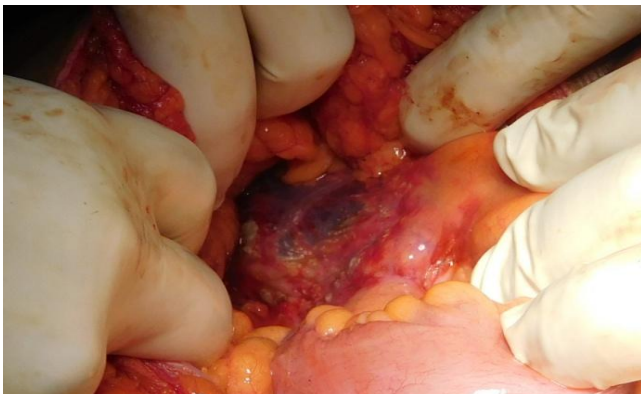
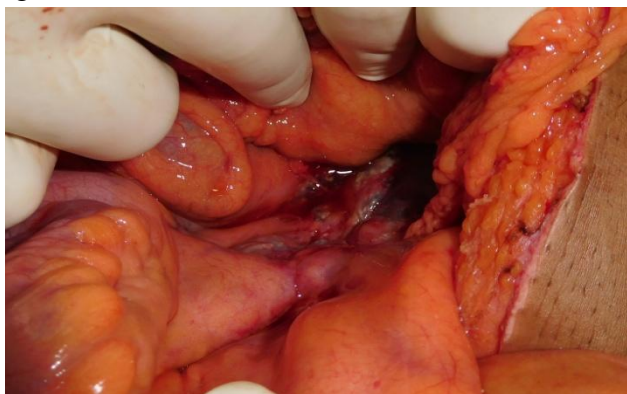


Figure 4



Clinical photographs Fig.2, Fig.3 and Fig.4 shows pancreatic, peri pancreatic and root of mesentery necrosis.

Discussion

Severe Acute pancreatitis manifesting as Acute appendicitis & mimicking clinically as appendicular perforation, is a rare presentation.

Most commonly the peripancreatic inflammatory fluid extends into anterior pararenal space & retro mesenteric plane. The fluid & inflammation may spread posteriorly to involve retrorenal plane & laterally into the latero canal plane or spread inferiorly in the combined interfascial plane to reach pelvic retroperitoneum. These fascial planes provide weak barriers to spread inflammation ⁽¹⁾. The pelvic retroperitoneal space includes pre-vescical space, lateral pelvic walls and retro rectal space.

Based on extent of spread of peripancreatic fluid in retroperitoneal interfascial plane, Ishikawa et al. proposed a severity classification system for acute severe pancreatitis ⁽²⁾ According to pattern of spread, the grades are numbered from I to V, with higher the grade, higher the severity & morbidity.

As per the classification, the spread of inflammation & necrosis to pelvic retroperitoneum has been categorized as Ishikawa grade- IV.

As per the guideline, the role of open surgical intervention in severe Acute pancreatitis is limited as the treatment of SAP has shifted away from early surgical debridement to aggressive intensive medical care ⁽³⁾.

In our case, it was misdiagnosed primarily, because there was no relevant history and it was with mis-leading clinical features & USG findings. It again proved that USG is not gold standard for diagnosis of Acute pancreatitis. There was no index of suspicion to go for CT abdomen or pancreatic enzyme estimation in this case. If SAP found during Laparotomy, lesser sac should be opened & pancreas to be fully inspected. Some surgeons place drain & irrigation catheter around the pancreas ^{(4),(5)}. But there is no consensus guideline for necrotic tissue found on laparotomy. In our opinion, a generous lavage with normal saline and conservative debridement of

sloughed out necrotic tissue with suction should be done to reduce the base for secondary infection.

Peritoneal lavage is a simple method to evacuate the free fluid in abdomen associated with SAP as it has been well established that it is extremely toxic & can induce organ damage due to apoptotic cell death. It can also induce bacterial translocation due to the increase in gut permeability. But a meta analysis of randomised control studies could not reveal its effectiveness on morbidity or mortality in SAP, though a number of studies demonstrated its efficacy in improving the clinical manifestation⁽⁶⁾.

In this case during lavage & suctioning, necrotic tissues come out of pancreas & peripancreatic tissue. So we did conservative necrosectomy of pancreas as well as necrosed pelvic tissues. It is documented that peritoneal lavage may reduce the peritoneal & circulating cytokine concentration, there by reduces morbidity & mortality⁽⁷⁾⁽⁸⁾.

We did the appendicectomy, because it was turgid, grossly inflamed with patchy necrosis of mid mesoappendix, which might cause vascular compromise to appendix in later stage. In our opinion if it could be diagnosed preoperatively, the management would be definitely conservative initially with a follow up CT abdomen, if patient's clinical status deteriorate⁽⁸⁾.

In later stage, step-up intervention i.e. radiological/endoscopic/surgical could have been required if CT abdomen reveals infected necrosis / infected pelvic peritoneal & retroperitoneal collections, depending on individual features & locally available expertise⁽⁹⁾.

Conclusion

To summarise, SAP presenting clinically as Appendicular perforation is unusual, when dilemma in diagnosis arises, a high index of suspicion with careful history & examination along with CT abdomen & pelvis may provide an accurate diagnosis & extent of the disease for its proper management.

Funding: None

Conflict of interest: None

Ethical approval: Not required

References

1. Molmenti EP et al- Anatomy of retroperitoneum: observation of distribution of pathological fluid collection. Radiology – 1996.
2. Ishkawa.K et al- Classification of AC. Pancreatitis based on retroperitoneal extension. Radio/2006.
3. IAP / APA. Evidence based guideline for management of AP.
4. BJM. Acute pancreatitis Dec.7.2015.
5. Way LW. Doherty G.M chapter-27. Pancreas in current surgical diagnosis & treatment. 11th ed.2003.
6. Nihon Rinsho .2004 Nov. 62 pubmed. Indication for & efficiency of peritoneal lavage in SAP.
7. Robert Caronne etal. Clinical effect of Laparotomy with perioperative peritoneal lavage.
8. Hitora M.Nozawa F etal- Relationship between plasma cytokine concentration & multi organ failure in patient with Acute Pancreatitis. Pancreas 2000-pubmed.
9. U.K guideline for management of AC. Pancreatitis Gut-2005.