



## Esthetic Rehabilitation of Crown Fracture Utilizing Orthodontic Extrusion and Restorative Modality

Authors

**Dr Neha Rane<sup>1</sup>, Dr Priyatam Karade<sup>2</sup>, Dr Rutuja Chopade<sup>3</sup>, Dr Vishal Patange<sup>4</sup>**

<sup>1</sup>MDS, Assistant Professor, Dept. of Conservative Dentistry & Endodontics, Mahatma Gandhi Vidyamandir's Dental College & Hospital, Nashik

<sup>2</sup>MDS, Assistant Professor, Dept. of Conservative Dentistry & Endodontics, Pandit Dindayal Upadhyay Dental College & Hospital, Kegao, Solapur

<sup>3</sup>MDS, Assistant Professor, Dept. of Conservative Dentistry & Endodontics Bharati Vidyapeeth Dental College & Hospital, Sangli

<sup>4</sup>MDS, Assistant Professor, Department of Orthodontics and Dentofacial Orthopedics, Vasantdada Patil Dental College and Hospital, Sangli

Corresponding Author

**Dr Rutuja Chopade**

MDS, Assistant Professor, Department of Conservative Dentistry & Endodontics Bharati Vidyapeeth Dental College and Hospital Sangli, Maharashtra

Email: [c.rutuja11@gmail.com](mailto:c.rutuja11@gmail.com)

### ABSTRACT

**INTRODUCTION:** *Complicated crown fractures involve enamel, dentine and the pulp, whereby the most commonly affected tooth is the maxillary central incisor. Fractures of anterior teeth cause not only esthetic and functional, but also psychological problems. Various treatment modalities are available depending upon the clinical, physiological and radiographic status of the involved tooth. In complex cases, a combination of endodontic, periodontal, orthodontic and restorative procedures may be required.*

**CASE DISCUSSION:** *This case report describes the management of a crown fracture of maxillary left central incisor. A complex procedure was designed to manage this case including orthodontic extrusion to move the fracture line above the alveolar bone and surgical recontouring of the altered gingival margin. Finally, the tooth was restored prosthodontically. Prosthodontic treatment was based on performing post and core and all ceramic crown on the extruded tooth.*

**CONCLUSION:** *The treatment resulted in good esthetics and secured periodontal health. This case report demonstrates that a multidisciplinary treatment approach is a reliable and predictable option to save a tooth.*

### INTRODUCTION

Traumatic injuries to teeth and their supporting tissues usually occur in young people and damage may vary from enamel fracture to avulsion, with

or without pulpal involvement or bone fracture. A crown-root fracture is a type of dental trauma, usually resulting from horizontal impact, which involves enamel, dentin and cementum, occurs

below the gingival margin and may be classified as complicated or uncomplicated, depending on whether pulp involvement is present or absent. Most of these injuries occur in permanent maxillary incisors before complete root formation and cause pulp inflammation or necrosis.<sup>1</sup>

Subgingival fracture of anterior tooth causes not only an esthetic and functional breakdown but also a psychological breakdown. Treatment of subgingival fracture of anterior tooth often requires a multidisciplinary approach. A combination of endodontic, periodontal, orthodontic and restorative procedures may be required. Periodontal or orthodontic intervention is required to expose a sound tooth supragingival tooth structure so that a crown ferrule is obtained. A good crown ferrule is mandatory for a long-term restorative success. This procedure leaves us with various options. They are

- crown lengthening,
- surgical extrusion and
- orthodontic extrusion.<sup>2</sup>

Of the above-mentioned options, orthodontic extrusion has been shown to be a better option since it does not alter the biological width or the position of the gingival margin of the tooth involved.

Any subgingival or subosseous extension of a pathologic or traumatic defect that precludes the traditional restorative approach is a possible indication for orthodontic extrusion. Extrusion avoids the loss of a dental unit and simplifies the prosthetic restoration.<sup>3</sup>

Orthodontic extrusion is a biological way of exposure of sound tooth structure and therefore requires a prolonged treatment, as 2 mm subgingival fracture will require an extrusion of about 4 mm. This 4 mm would be required so that there is a 2 mm sound supragingival tooth structure. This amount of extrusion would normally take about 2–4 months time. More than the duration of the extrusion, it is the difficulty to provide esthetics in the anterior region during the course of treatment which is an area of concern.

Loss of esthetics is due to two reasons. One, the fractured tooth is not reconstructed and two, the exposure of the orthodontic brackets during a smile.<sup>2</sup>

In this case report, a multidisciplinary treatment of complicated fracture of left maxillary central incisor in 19 year old patient is presented.

### CASE REPORT

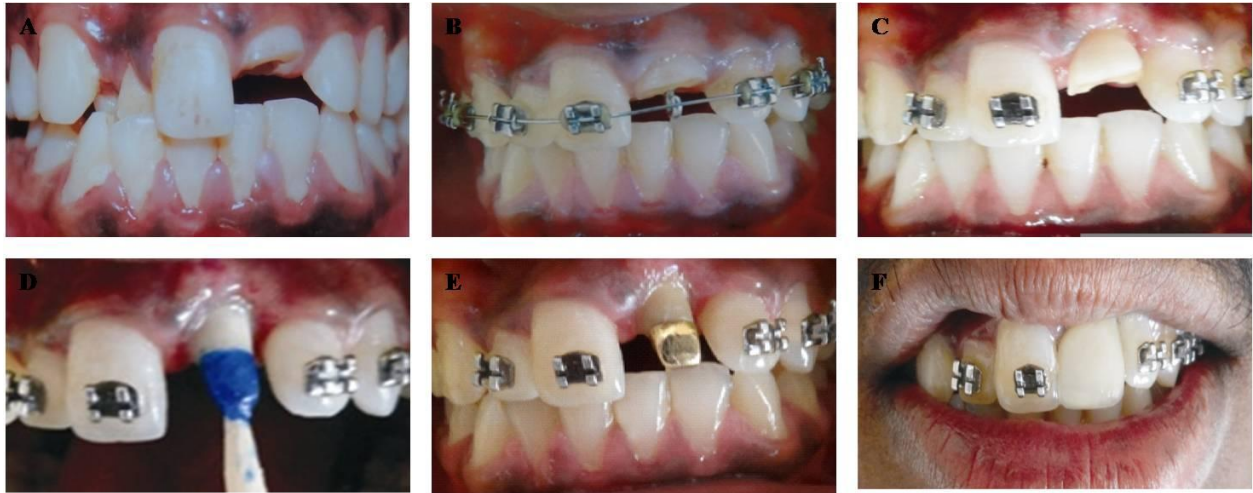A 19 year old patient was referred to the Department of conservative dentistry and endodontics 2 months after an accident which resulted in fracture of left upper anterior teeth. Clinical examination revealed a crown root fracture of tooth 21 (Figure A and G).

Treatment plan was designed and ceramic crown was planned. Therefore, it was necessary to extrude the tooth in the first phase to allow sufficient tooth area available for core build up and crown preparation.

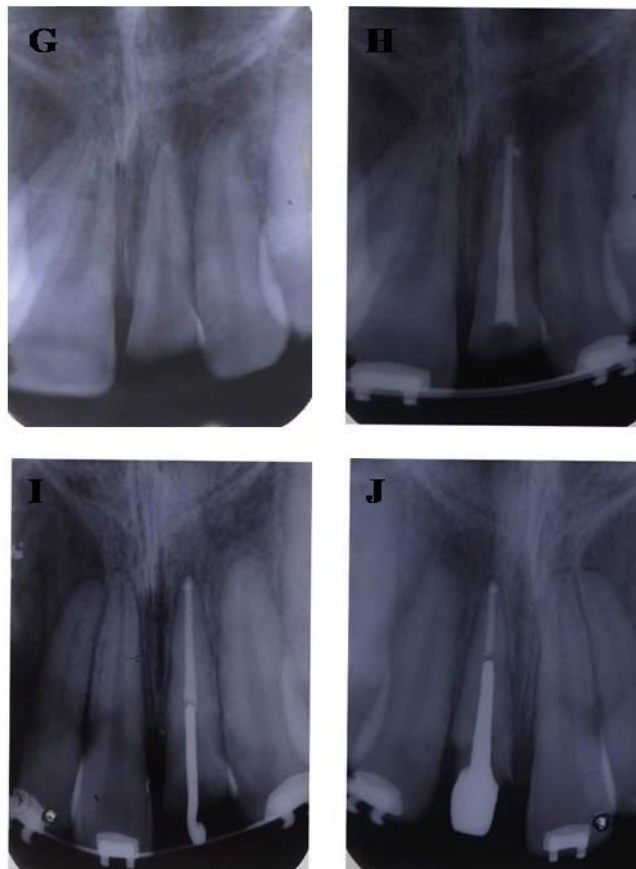
Root canal treatment was performed. Sodium hypochlorite solution was thoroughly used as an irrigant during the treatment. Obturation was done by the cold lateral condensation technique (Figure H). The patient was then referred to an orthodontist for further management.

After evaluation, it was planned to extrude the tooth up to 3mm to allow sufficient tooth area available for core buildup and crown preparation. Gutta percha was removed upto 1 cm and metal attachment was cemented in the canal space for orthodontic extrusion (Figure B and I). After orthodontic extrusion of tooth, periodontal surgery was performed to correct the discrepancy of the gingival margin due to coronal migration of connective tissue and to increase the crown length (Figure C).

In the next phase, post and core built up was performed. Post space preparation and crown preparation was done with 21. Wax pattern was fabricated (Figure D), post cementation was done (Figure E and J) and ceramic crown was cemented (Figure F).



- A. Intra oral pre-operative photograph
- B. Cementation of metal attachment-21
- C. Periodontal surgery performed-21
- D. Crown preparation and wax pattern pattern fabrication-21
- E. Post cementation-21
- F. Intra oral post-operative photograph



- G. IOPA of 21
- H. Obturation of 21
- I. IOPA showing cementation of metal attachment-21
- J. IOPA showing cementation of post-21

## DISCUSSION

Orthodontic root extrusion, or forced eruption, was first described by Heither say in 1973. The aim of this movement was to raise the fractured root surface from within the alveolar bone to a supragingival position. This is accomplished by providing a horizontal component, usually a wire attached to the adjacent teeth, from which a vertical force is then exerted on the root.<sup>4,5</sup>

The indications for root extrusion are any cervical third root problem that involves or extends 0–4 mm below the crest of the alveolar bone, including horizontal fractures, caries, repair of resorption defects and iatrogenic perforations of the coronal third of the root, and where it is necessary to slowly extract a tooth when radiation therapy presents a risk of post extraction osteoradionecrosis.<sup>6</sup>

Orthodontic forced eruption can be carried out indifferent ways. A hook attached to a post can be used to pull the root vertically towards a horizontal bar attached to the adjacent teeth, by means of active elastic. Alternatively, brackets can be bonded to the teeth or restoration, more gingivally to the tooth to be extruded, and more incisally on the adjacent teeth, and extrusive force is provided by an orthodontic wire. It resulted in a good controlled movement of the tooth. The first method was chosen in this case.<sup>7,8</sup>

The main reason for conducting orthodontic forced eruption in a traumatized fractured tooth is the requirement for sufficient tooth structure to provide a ferrule effect over sound dentin for the crown. Occlusal movement of the root along with its gingiva seems to be a function of how rapidly the root is extruded and how much force is used. If the gingival tissue move with the tooth fragment, then surgical contouring may be required before preparation of the tooth for prosthesis.<sup>6,9</sup>

In case of rapid extrusion of the tooth, the periodontal fibers stretch and readjust, but the bone does not have time to remodel because of rapid movement. Thus there is no coronal shift of

the marginal bone, facilitating prosthetic restoration as there is no need to reshape bone.<sup>9</sup> 6<sup>th</sup> generation bonding agent is used for the bonding of the orthodontic bracket because of its higher bond strength.<sup>10</sup>

Cast post and core was used in this case because remaining coronal tooth structure supporting the artificial crown was minimal. It preserves maximum tooth structure as the post is fabricated to fit the radicular space with a superior adaptation to the root canal. The core is an inherent part of the post and does not need to be retained by the post. It is strong with the post and core forming a single unit with no interface between them. It also provides anti-rotational properties.

## CONCLUSION

The treatment resulted in good esthetics and secured periodontal health. This case report demonstrates that a multidisciplinary treatment approach is a reliable and predictable option to save a tooth.

## ACKNOWLEDGEMENT

I am thankful to Dr. Arpit Chanchad for proper orthodontic treatment.

## REFERENCES

1. Fidel SR et al. Clinical management of a complicated crown-root fracture: a case report. *Braz Dent J.* 2011;22(3):258-62.
2. Subbiya A and Murali RV. Management of subgingival fracture by an esthetic approach. *J Conserv Dent.* 2011 Jul;14(3):318-21.
3. Kondapuram Seshu MR and Gash CL. Multidisciplinary management of a fractured premolar: a case report with followup. *Case Rep Dent.* 2012;2012:192912.
4. Villat C, Machtou P, Naulin-Ifi C. Multidisciplinary approach to the immediate esthetic repair and long-term

- treatment of an oblique crown–root fracture. *Dent Traumatol* 2004;20: 56–60.
5. Terata R, Minami K, Kubota M. Conservative treatment for root fracture located very close to gingiva. *Dent Traumatol* 2005;21:111–14.
  6. Simon JHS. Root extrusion. Rationale and techniques. *DentClin North Am* 1984;28:909–21.
  7. Simon JHS, Kelly WH, Gordon DG, Ericksen GW. Extrusion of endodontically treated teeth. *JADA* 1978;97:17–23.
  8. Stern N, Becker A. Forced eruption: biological and clinical considerations. *J Oral Rehabil* 1980;7:395–402.
  9. Malmgren O, Malmgren E, Frykholm A. Rapid orthodontic extrusion of crown root and cervical root fractured teeth. *Endod Dent Traumatol* 1991;7:49–54.
  10. Rutuja v chopade et al. An evaluation and comparison of shear bond strength of two adhesive systems to enamel and dentin: an in vitro study. *Journal of International Oral Health* 2016; 8(1):86-89.