



Dermatofibrosarcoma Protuberans over Anterior Abdominal Wall: A Case Report

Authors

Dr Arnab Sarkar¹, Dr Amul Bhedi², Dr Sushil Damor³

¹Resident Doctor, Department of General Surgery, Medical College and S.S.G. Hospital, Baroda

²Associate Professor, Department of General Surgery, Medical College and S.S.G. Hospital, Baroda

³Assistant Professor, Department of General Surgery, Medical College and S.S.G. Hospital, Baroda

Corresponding Author

Dr Arnab Sarkar

A-288, Somnath Nagar, Nr. Ravi Park, Tarsali, Vadodara- 390009

Email: sarkar.arnab14@gmail.com

Abstract

This is the case of a 66 year old female presented with a swelling over left anterior abdominal wall since five years. Further examination of the morphology of the resected surgical specimen, histological and immunohistochemical studies confirmed it to be a dermatofibrosarcoma protuberans over the anterior abdominal wall. It was successfully managed by a wide local excision with an excellent result and a high degree of patient satisfaction was achieved. Though a rare clinical entity, this tumor has chances of high recurrence, and so it should be borne in mind while making a diagnosis and during its long term follow-up.

Keywords: CD34, Dermatofibrosarcoma protuberans, Imatinib mesylate, Mohs' microscopic surgery, Soft-tissue sarcoma.

Introduction

Dermatofibrosarcoma protuberans (DFSP) is a rare slow growing neoplasm of the skin, usually arising from the dermis, that has a high local recurrence rate. It accounts for <0.01% of all malignancies and <0.1% of all the cutaneous neoplasms, with incidence being 0.8 cases per million-persons an year as reported in literature based on population based cancer registries of various countries. The most common presentation of disease is painless, slow growing subcutaneous nodule and mainly occurs in second and fifth decades of life. It has a homogenous sex distribution with a slight bias towards men.

Surgical excision is the treatment of choice and early recognition is extremely important because of the excellent prognosis following adequate excision. Herein, we present a case report of DFSP from our institution with a review of literature.

Case Report

A sixty- six year old female presented to our outpatient department with a history of left anterior abdominal wall swelling since five years. The swelling had gradually increased to its present size. There was no history of discharge from the swelling, fever or weight loss. The patient gave a

past history of having undergone excision of a similar swelling at the same site six years back and was now facing a recurrence.

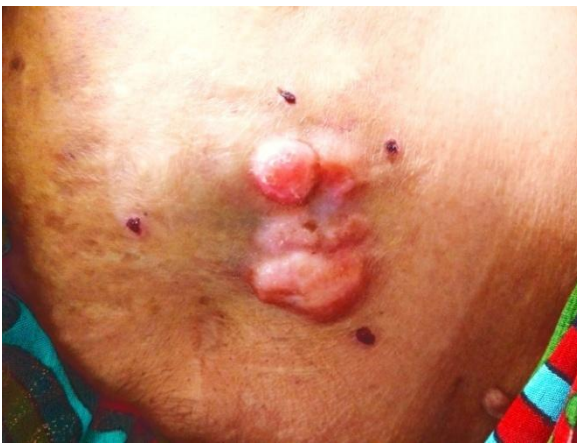
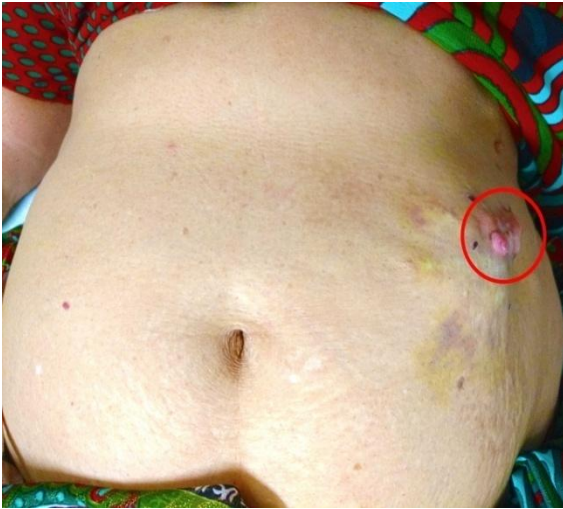
Figure 1 & 2: Picture shows protruding swelling in left hypochondrium having pinkish appearance.

On examination, the skin over the swelling showed tiny red nodules with no discharge from them. On palpation, there was an irregular mass of approximately 6cm by 4cm that was hard and fixed to the skin (Figure 1 & 2). Chest radiograph and routine blood investigations were found to be within normal limits. On ultrasound examination, it suggested a 5.4cm by 3.5cm heterogenous hypoechoic lesion within the subcutaneous and intramuscular plane of the anterior abdominal wall. Trucut biopsy was sent from the tissue and it suggested a low grade spindle cell neoplasm.

The patient was adequately resuscitated with intravenous fluids and antibiotics (intravenous Amoxicillin and Clavulanic acid 20 mg per kg body weight).

Wide local excision of the mass with a surgical margin of 3cm was done and the specimen was sent for histopathological examination.

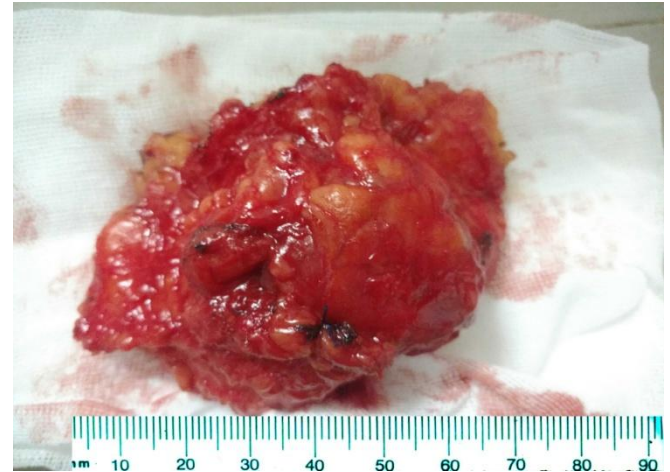

Figure 3: Picture shows gross appearance of the mass of approx 8x6x4.5cm

Grossly, it was a yellowish brown skin covered soft tissue mass of 8cm by 6cm by 4.5cm with a skin flap of 8cm by 7cm (Figure 3). External surface showed multiple nodules ranging from 0.5 to 2cm in diameter. Cut surface showed well circumscribed creamish white nodular mass of about 8cm by 4cm by 3.5cm.

Histological sections showed spindle shaped cell arranged in short fascicles showing storiform pattern (Figure 4). There is infiltration of surrounding fat spaces and small blood vessels. There was little nuclear pleomorphism and scanty mitotic activity. Immunohistochemistry showed the tumor cells positive for CD34.

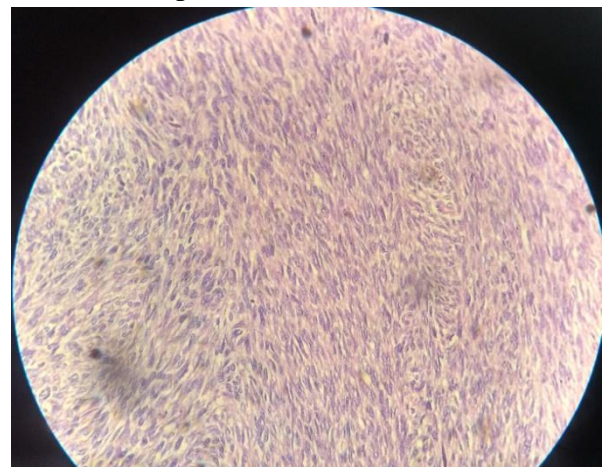


Figure 4: Picture shows storiform pattern of tumor cells in hematoxylin- eosin staining, magnification x200

Histopathologic and immunohistochemical findings were diagnostic for Dermatofibrosarcoma protuberans over the anterior abdominal wall.

The patient had an uneventful post operative period, and is still being followed up in the outpatient clinic for local recurrence (Figure 5).

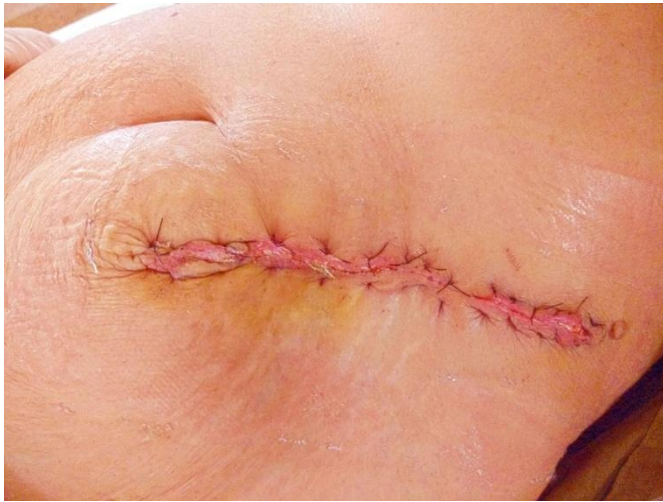

Figure 5: Picture shows post-operative outcome of the patient

Discussion

DFSP is a rare soft tissue tumor that is characterized by its locally infiltrative and recurring properties. Historically, first mentioned by Taylor in 1890, this tumor was first defined to be “progressive and recurring dermatofibroma” by Darier and Ferrand in 1924. It was later in 1925, based on the tendency to give rise to protruding nodules, that Hoffman termed it as DFSP in his three reported cases.^{1,2}

Normally, this DFSP is considered to be a tumor of low-grade malignancy. However, it can transform into a fibrosarcomous DFSP which has more aggressive and higher metastatic potential. It accounts for less than 0.1% of all malignancies, 2-6% of all soft tissue sarcomas and only 1% of the soft tissue sarcomas of the head-neck region. Although DFSP can develop in any part of the body, it is most frequently seen on torso (50-60%), extremities (20-30%) and head-neck region (10-15%) respectively.

In the pathogenesis of DFSP, in almost 90 percent of cases, a unique reciprocal translocation in chromosome 17 and 22 is said to be involved.

There is t(17,22) involving COL1A1 (collagen type 1A1) and PDGFb (platelet derived growth factor) genes respectively.^{5,6}

A history of trauma and previous surgery is a possible etiological factor in the development of DFSP, as in our case the patient had a previous history of surgery.

Initially, this presents as asymptomatic, discrete plaque with irregular borders having reddish-brown or pink appearance resembling hemangioma. Later on, it presents as a painless, multiple nodule protruding from the skin and usually less than 5 cm in size.³ In the present case, the patient had a similar presentation.

Histologically, DFSP is characterized by multiple spindle cells arranged in a storiform pattern with elongated nuclei without significant cytological atypia or pleomorphism. Immunohistochemical studies are highly diagnostic of DFSP. DFSP show immunopositivity to CD34 and vimentin in 84-100% and negative for S100 protein and factor XIIIa. In our case, the tumor showed similar histological features and the cells were diffusely positive for CD34.

The differential diagnoses include dermatofibroma, malignant fibrous histiocytoma, neurofibroma, hypertrophic scars, keloid, fibromatosis, fibrosarcoma, inflammatory myofibroblastic tumor.

The primary treatment of DFSP is complete excision. Because of the infiltrative nature of the tumor, a wide local excision with removal of 2 to 3 cm surgical margin along with it is considered as the main treatment option. But, the average recurrence rate after such a wide excision has been reported to be 8.8%.⁴ This recurrence rate can be lowered down to 1.5% with the use of Mohs’ microscopic surgery, which is considered as the treatment of choice.

Imatinib mesylate⁷ has shown to be effective against both localised and metastatic DFSP with t (17,22). However, DFSP with fibrosarcomous transformation is resistant to conventional chemotherapy. Also, role of radiotherapy as adjuvant therapy appears to be controversial.^{9,10}

The prognosis of DFSP is generally good. The 5 years survival rate of the patients after the appropriate treatment is between 93% and 100%.

Conclusion

DFSP is a rare tumor of cutaneous origin with an intermediate level of malignancy. But, it has a potential for aggressive local invasion and high rate of recurrence. So, special attention has to be given to these cases by proper diagnosis and planning the proper surgery. Also, patients have to be reminded of a long-term follow-up as these can recur in the following long years.

References

1. Stojadinovic A, Hoos A, Karpoff HM, Leung DH, Antonescu CR, Brennan MF, et al. Soft tissue tumours of the abdominal wall: Analysis of disease patterns and treatment. *Arch Surg.* 2001;136:70–9
2. Weiss SW, Goldblum JR, Enzinger and Weiss's soft tissue tumors. 5th ed, Mosby, 2001. P 491- 507
3. Mc Peak CJ, Cruz T, Nicastrì AD. Dermatofibrosarcoma protuberans: An analysis of 86 cases- five with metastases. *Ann Surg.* 1967;166:803–16
4. Khatri VP, Galante JM, Bold RJ, Schneider PD, Ramsamooj R, Goodnight JE Jr. Dermatofibrosarcoma protuberans: Reappraisal of wide local excision and impact of inadequate treatment. *Ann Surg Oncol.* 2003;10:1118–22
5. Sjöblom T, Shimizu A, O'Brien KP, Pietras K, Dal Cin P, Buchdunger E, et al. Growth inhibition of dermatofibrosarcoma protuberans tumours by the platelet-derived growth factor receptor antagonist STI571 through induction of apoptosis. *Cancer Res.* 2001;61:5778–83
6. Kiuru-Kuhlefelt S, El-Rifai W, Fanburg-Smith J, Kere J, Miettinen M, Knuutila S. Concomitant DNA copy number amplification at 17q and 22q in dermatofibrosarcoma protuberans. *Cytogenet Cell Genet.* 2001; 92:192–5
7. McArthur GA, Demetri GD, van Oosterom A, Heinrich MC, Debiec-Rychter M, Corless CL, et al. Molecular and clinical analysis of locally advanced dermatofibrosarcoma protuberans treated with imatinib: Imatinib target exploration consortium study B2225. *J Clin Oncol.* 2005;23:866–73.
8. Loghdey M.S., Varma S., Rajpara S.M., Al-Rawi H., Perks G., Perkins W. Mohs micrographic surgery for dermatofibrosarcoma protuberans (DFSP): a single-centre series of 76 patients treated by frozen-section Mohs micrographic surgery with a review of the literature. *J Plastic Reconstr Aesthet Surg.* 2014;67(10):1315–1321
9. Suit H., Spiro I., Mankin H.J., Efird J., Rosenberg A. Radiation in management of patients with dermatofibrosarcoma protuberans. *J Clin Oncol.* 1996;14(8):2365–2369.
10. Dagan R, Morris CG, Zlotecki RA, Scarborough MT. Radiotherapy in the treatment of DFSP. *Am J Clin Oncol* 2005;28:537-9.