



Solid Pseudopapillary Tumor: A Rare Neoplasm of the Pancreas with Excellent Outcome – A Case Report

Authors

Dr Ajeet Kumar¹, Dr Kalpana Chandra², Dr Suryajit Kumar Singh³,
Dr Guddi Rani Singh⁴, Dr Amit Kumar Sinha⁵, Dr Rawi Agrawal⁶

^{1,3,4,5,6}Senior Resident, Department of Pathology, IGIMS Patna

²Assitant Professor, Department of Pathology, IGIMS, Patna

ABSTRACT

Solid pseudopapillary tumor is an uncommon primary neoplasm of the pancreas that typically affects young women. SPN is generally considered as a tumor of low malignant potential which rarely metastasizes. It is important to differentiate this tumor from other pancreatic neoplasm, as this type is amenable to cure after complete surgical resection, even in cases with capsular invasion or disseminated diseases unlike other malignant tumors of the pancreas. Long term follow up is recommended in all cases of SPNs to prevent recurrence. The importance of accurate diagnosis and early management is emphasized.

Keywords: Pancreas; pseudopapillary tumor.

INTRODUCTION

Solid pseudopapillary tumor (SPT) is an uncommon neoplasm of the pancreas and accounts for 2% of all pancreatic neoplasm. with low incidence rate ⁽¹⁾. This tumor predominantly affects young females who are commonly in their second or third decade of life ^(2,4).

Recently there has been an apparent steady increase in number of cases of this neoplasm probably because of increased radiological imaging and further confirmation of this entity by panel of IHC. Most of the patient presents with vague symptoms of which vague abdominal pain being the commonest one. We report a case of 15-year-old girl who presented with mild jaundice, elevated liver function tests and right upper quadrant pain.

CASE REPORT

A 15 year old girl with no prior medical complaints presented in the emergency department with complaints of epigastric and right upper quadrant (RUQ) pain for four days. The pain was sudden in onset, with intermittent attacks; it was stabbing in nature and radiating to her back. It was associated with nausea and vomiting. Her vital signs were stable. On physical examination, she was mildly icteric but her abdomen was soft. Hematological parameters were within normal limit. Ultrasound was suggestive of a large mass measuring 12 cm, seen involving the pancreatic head with solid & cystic component. On CT scan, a large 12x11x9 cm heterogenous enhancing soft tissue mass at pancreatic head displacing the 2nd part of duodenum laterally (Figure 1). The patient underwent pancreaticoduodenectomy with Appendicectomy.

Gross specimen consisted of parts of intestine with attached tumor mass. Tumor was well encapsulated. Focally capsule was adhered to the tumor. on cut, tumor was soft with solid & cystic areas. Extensive areas of hemorrhage & necrosis was seen (Figure 2). Grossly definite pancreatic tissue was not identified. Also present Appendix measuring 5.5x 0.8 cm and was grossly unremarkable. Histopathology revealed a well-circumscribed tumor with a thick capsule and solid and cystic area. Tumor was predominantly arranged in pseudopapillary architecture with evidence of cellular degeneration. Tumor cells were uniform with round normochromatic nuclei, and eosinophilic cytoplasm. The nucleus of few tumor cells has folded nuclei, finely dispersed chromatin and inconspicuous nucleoli. (Figure 3A) Occasional mitosis was noted. Necrosis and hemorrhage correlated with the gross impressions. Capsule was free of tumour.

ON IHC- CD10, CD56, Cyclin D1, & PR was strongly positive in majority of the tumor cells. CK was weakly positive in majority of the tumor cells. Beta catenin was positive in nuclei & cytoplasm of majority of tumor cells. Synaptophysin, Chromogranin, CK8/18 was negative (Figure 3 B-F).

Pancreas showed benign appearing acini with few cystically dilated glands and was free of tumor. Appendix showed submucosal fibrosis. Both proximal and distal cut end of the intestine was free of tumour.

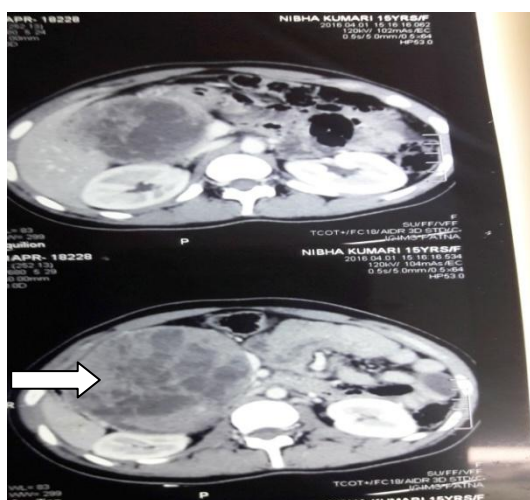


FIG -1-CT Scan shows a large heterogenous soft tissue mass at pancreatic head displacing the 2nd part of duodenum laterally.

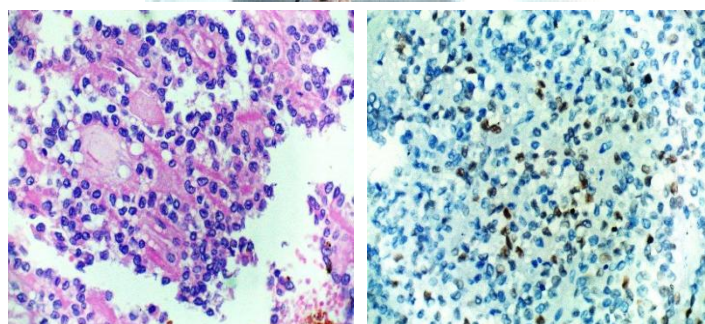
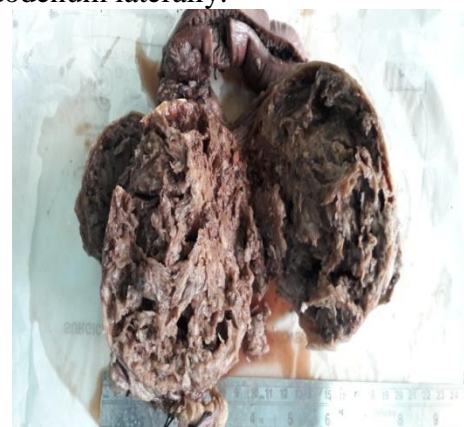

FIG 2-Gross pic shows solid and cystic areas with extensive hemorrhage & necrosis

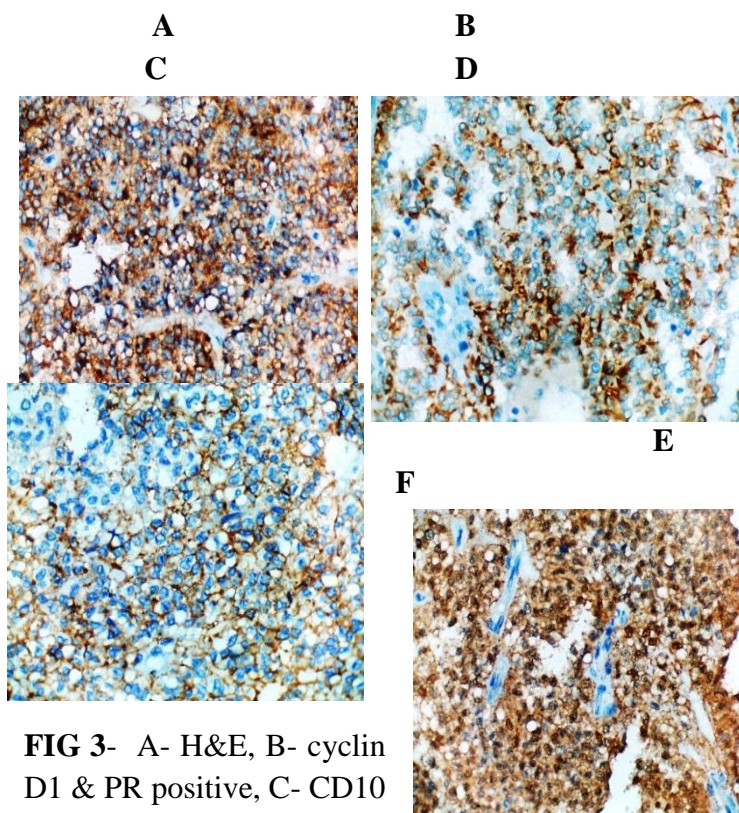


FIG 3- A- H&E, B- cyclin D1 & PR positive, C- CD10 positive, D- CK positive, E- CD 56 positive, F- Beta catenin positive

DISCUSSION

Solid pseudopapillary tumor (SPT) of the pancreas was first described by Frantz in 1959⁽³⁾. World Health Organization (WHO) in 1996 defined it as “solid pseudo papillary tumor” of the pancreas^[4]. The histogenesis of this tumor is unclear. Many investigators favour the theory that SPTs originate from multipotent primordial cells, whereas others suggest an extrapancreatic origin from genital ridge angle-related cells^[5]. The strong predilection for female sex suggests that this is a hormone dependent tumor. Expression of PR receptor and CD10 favors an association between female sex and tumorigenesis. This rare tumor seems to have a predilection for young Asian and African-American women. The male to female ratio is 1:10 and the mean age at presentation is 22 years. It is often clinically asymptomatic or present with a gradually enlarging abdominal mass. Jaundice is a rare presentation^[6].

The most frequent location of SPNs are head of pancreas (39.8%), followed by tail (24.1%). Majority of this tumor is identified on CT but now a day's MRI has been more preferred diagnostic modality. The lab investigation including tumor marker like CA19.9 and CEA are generally non contributory.

Most SPNs are benign tumor; however features of malignancy can occur in about 15% of cases. Recently tumor size and proportion of solid component has been identified as predictors of malignancy.(younglim kim suk bae moon) Hwang et al. found that malignant SPNs tend to be larger than benign tumours (median 10 cm vs median 5cm). The solid component is more in malignant SPNs 88.5% vs 41.5% at presentation. This is also not clear that whether SPNs which is undergoing malignant transformation is growing larger or those SPNs with innate malignant potential tend to grow larger with more proportion of solid component. Many studies have showed that the most common site for metastasis is the liver and the omentum^[7,8] and majority of such tumors are located at pancreatic body and tail. Nishihara et al have reported that venous invasion, degree of nuclear atypia, mitotic rate and presence of necrobiotic cell rests are helpful in determining the prognosis

but Jaksic et al could not find these factors to correlate with the prognosis

CONCLUSION

SPN is a rare neoplasm of pancreas with low malignant potential. Timely and appropriate surgical intervention gives excellent outcome. This case is reported only because this entity is underreported from India

REFERENCES

1. Campagno J,Oertel JE,Kemzar M.Solid and papillary epithelial neoplasm of pancreas,probably of small duct origin; a clinicopathological study of 52 cases.Lab Invest 1979;40:248-49
2. Sciafani LM,ReuterVE,Coilt DG,Brennan MF:The malignant nature of papillary and cystic neoplasm of the pancreas.Cancer 1991;68:153-58
3. Frantz VK. Tumors of the pancreas. In: Atlas of tumor pathology. Washington, DC: *Armed forces Institute of Pathology*, 1959: 32-33
4. Ng KH, Tan PH, Thng CH, Ooi LL. Solid pseudopapillary tumour of the pancreas. *ANZ J Surg*. 2003, 73:410-415
5. Zuriarrain A, Nir I, Bocklage T et al. Pseudopapillary tumor of the pancreas in a 17-year-old girl. *J Clin Oncol* 2011; 29:e 395–e396
6. Chen X, Zhou GW, Zhou HJ et al. Diagnosis and treatment of solidpseudopapillary tumors of the pancreas. *Hepatobiliary Pancreas Dis Int* 2005;4:456–59.
7. Sun CD, Lee WJ, Choi JS et al. Solid-pseudopapillary tumours of the pancreas: 14 years' experience. *ANZ J Surg* 2005;75:684–89.
8. Mao C, Guvendi M, Domenico DR et al. Papillary cystic and solid tumors of the pancreas: a pancreatic embryonic tumor? Studies of three cases and cumulative review of the world's literature. *Surgery* 1995;118:821–28.

