

www.jmscr.igmpublication.org

Impact Factor 3.79  
ISSN (e)-2347-176x  
ISSN (p) 2455-0450



**Journal Of Medical Science And Clinical Research**

IGM Publication

An Official Publication Of IGM Publication

## A Retrospective Study of Appendicitis as a Cause for Acute Abdomen in Dengue Fever

Authors

**Dr. K.Ravichandran<sup>1</sup>, Dr. R.Ramesh<sup>2</sup>, Dr. K.C.M.Rajkumar<sup>3</sup>**

<sup>1</sup>Assistant Professor of Surgery, Dept of Surgery, Rajah Muthiah Medical College, Annamalai University, Annamalainagar, Chidambaram, Tamil Nadu.

<sup>2</sup>Professor of Surgery, Dept of Surgery, Rajah Muthiah Medical College, Annamalai University, Annamalainagar, Chidambaram, Tamil Nadu.

<sup>3</sup>Post Graduate Student, Dept of Surgery, Rajah Muthiah Medical College, Annamalai University, Annamalainagar, Chidambaram, Tamil Nadu.

### Abstract

**Aim:** To study the incidence and emphasize the importance of Acute appendicitis as a cause of Acute abdomen in Dengue fever and the role of conservative and surgical management and its outcome.

**Background:** The incidence of appendicitis is a common acute abdominal surgical emergency encountered in surgical practice. Very rarely it is due to viral disease like Dengue in endemic areas. Its occurrence in Dengue, is a dreaded complication.

**Materials and methods:** This is a retrospective hospital based study of Appendicitis as a cause for Acute abdomen in Dengue fever in 10 patients out of 42- symptomatic patients of Acute abdomen in Dengue, admitted between November 2010-November 2014 in surgical ward of Rajah Muthiah Medical College. All these patients were diagnosed with confirmatory tests, analysed, findings and outcome studied and the findings were observed by laparoscopic/open appendicectomy.

**Results:** All the admitted 10 cases of Acute appendicitis in Dengue were treated conservatively but for 2 cases which were operated. Outcome was good and no mortality.

**Conclusion:** Do not miss or under estimate Appendicitis in Dengue. Priority should be given and timely surgical intervention is a must, when conservative management fails.

**Keywords:** Appendicitis, Appendicular Mass, Peyer's Patches, Dengue, Acute abdomen, Leucopenia, Thrombocytopenia.

### Introduction

Dengue (Break-Bone Fever) is a mosquito borne disease carried by *Aedes Aegypti* mosquito caused by Dengue virus. Its common symptoms

are high fever, severe head ache, vomiting, retro orbital pain, muscle pain, joint pain and rashes. More serious form of Dengue (DHF, DSS) has blood plasma leakage, low blood pressure, bleeding and rarely abdominal pain.

Acute abdomen in Dengue can occasionally present as acute surgical emergency requiring urgent surgical intervention. Presenting abdominal catastrophe may be due to Acute Appendicitis, acute acalculous cholecystitis, Non specific mesenteric adenitis, non-specific peritonitis and rarely intestinal perforation. Appendicular, ileal, jejunal, Gastric perforation were encountered in adult patients (at the sites of Peyer's patches, depending on the volume of aggregations of Peyer's patches)

The cause of the onset of severe abdominal pain associated with signs of the acute abdomen in patients with Dengue is unclear. Rarely Nephritis, Hepatitis, Pancreatitis, Pleural effusion, Pericardial effusion, Perinephric collection and Sub-hepatic collection are also noted in Dengue.

In all patients with DHF the incidence of acute abdominal pain is high. Other theories proposed to explain acute abdominal pain in patients with dengue fever include, plasma leakage and serious effusions containing high protein content together with lymphocytic infiltrations in patients presenting with acute appendicitis, pancreatitis, and acalculous cholecystitis.

The pathogenesis of acute appendicitis in DHF is not fully understood, but may result from localized microangiopathy in the appendicular wall.

Histopathologic analysis of the excised appendix showed a predominant infiltration of lymphocytes, which was not consistent with acute bacterial appendicitis. The histological finding of enlarged mesenteric lymph nodes with serous fluid collection and oedema may result in the

inflammatory changes identified in patients with acute appendicitis.

Progressive Thrombocytopenia, progressive leucopenia, neutrophil leukocytosis, NSI-Positivity, with a positive IgG and IgM enzyme-linked immuno absorbent assay confirmed the Dengue. CRP levels increased in appendicitis.

The immunological system is compromised in Dengue and hence the associations like nephritis, hepatitis, splenomegaly, pancreatitis.

### **Objectives**

To emphasize Acute appendicitis as one of the rare cause of Acute abdomen in Dengue fever and to study the incidences in 1. Appendicitis as a cause for Acute abdomen in Dengue, 2. Age. 3. Sex. 4. Symptom. 5. Management (conservative/surgical), 6. Per-operative findings, 7. Appendicitis with other causes of acute abdomen in Dengue and its outcome.

### **Materials and Methods**

This study was a retrospective study conducted during the period of November 2010-November 2014. Inclusion Criteria: 42 patients who suffered with Dengue with abdominal pain in the age group between 13-60 years were included in this study. out of 42 cases of acute abdomen in Dengue, 10 appendicitis cases as the cause of acute abdomen in Dengue were analysed and the incidences in- Appendicitis as a cause for Acute abdomen in Dengue, Age, Sex, Symptom, Management (conservative/surgical), Per-operative findings, and Appendicitis with other causes of acute abdomen in Dengue were

analysed. The data have been collected from Medical Records Department at Rajah Muthiah Medical College, Annamalainagar, chidambaram.

**Result**

42 patients were admitted as Dengue Fever with acute abdomen in RMMC-Hospital during November 2010-November 2014, and out of which 10 patients were diagnosed as Dengue with acute appendicitis. All the 10 cases were observed for the first 3 days and after ascertaining no clinical improvement, they were taken-up for surgery. In 10-cases, 6-patients were male and 4-were females. out of 6-male patient 5-were treated conservatively and 1-patient underwent lap appendicectomy. Out of 4 female patients, 3 were treated conservatively and 1 patient had mass and hence lap was converted to open and open appendicectomy done.

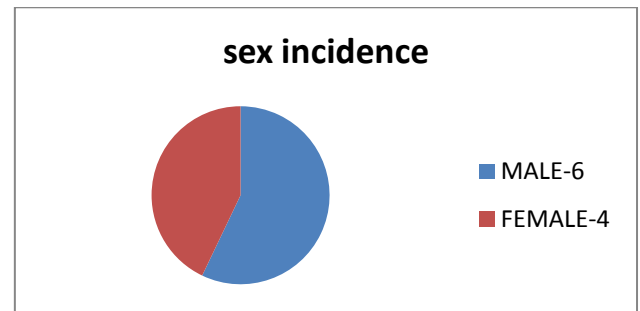
**Chart : 1** Incidence of Appendicitis as a cause for Acute abdomen in Dengue fever in 42 cases.

Appendicitis as a cause for Acute abdomen in Dengue fever in 42 cases.		
sex	Number of cases	%
Male	6	14.3
Female	4	9.5
Total	10	23.8

**Chart-2 A** Sex Incidence of Acute Appendicitis in Dengue with acute abdomen in 10 out of 42 cases.

Total Number of Cases of Dengue with Acute Abdomen Due to Appendicitis = 10		
sex	Number of cases	%
Male	6	60
Female	4	40

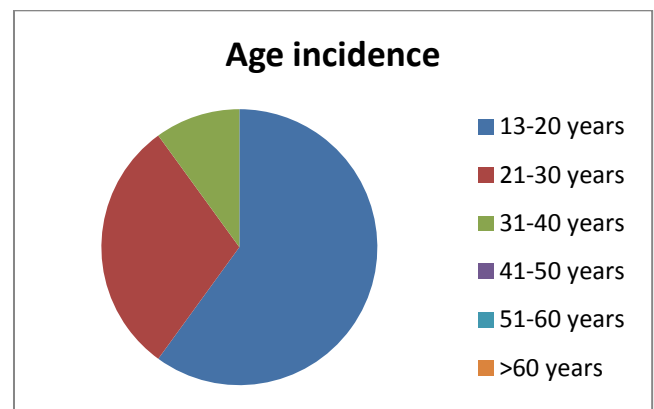
**Chart-2 B** Sex Incidence of Acute Appendicitis in Dengue with acute abdomen



**Chart-3 A** Age incidence of Acute Appendicitis in Dengue with acute abdomen in 10 cases.

Total number of patients	10	
Age group	No: of patients	%
13-20 Years	6	60
21-30 Years	3	30
31-40 Years	1	10
41-50 Years	0	0
51-60 Years	0	0
Above 60 Years	0	0

**Chart-3B** Age incidence



**Chart-4** Symptom wise incidence of Acute Appendicitis in Dengue with acute abdomen in 10 cases.

Total number of patients	10	
Symptom	No: of patients	%
Fever	10	100
Severe headache	4	40
Muscle pain	5	50
Joint pain	3	30
Rashes	2	20
Nausea	8	80
Abdominal pain	10	100
Guarding	10	100
RIF Tenderness	10	100

**Chart- 5** Management wise incidence of Acute Appendicitis in Dengue with acute abdomen in 10 cases.

Sex	cases	%	Conservative	%	Surgery	%
Male	6	60	5	50	1(lap)	10
Female	4	40	3	30	1(lap/open)	10

**Chart-6** Per-operative findings in lap/open appendicectomy in Acute Appendicitis in Dengue with acute abdomen in 2 out of 10 cases.

Operative findings	Number of cases
Inflamed appendix	2
Inflamed mesoappendix	2
Inflamed mesenteric lymphnodes,	1
Minimal ascitis	2

**Chart : 7** Incidence of Appendicitis with other causes of acute abdomen in Dengue

Total number of patients	42	
Causes of Acute abdomen in Dengue	No: of patients	%
Acute Appendicitis	10	23.8
Acalculous Cholecystitis	2	4.8
Gastritis	16	38.1
Peptic ulcer	8	19.0
Haemorrhage	0	0
Hollow viscous perforation	0	0
Pancreatitis	1	2.4
Hepatitis	1	2.4

## Discussion

The Dengue with acute abdomen patients had most of the symptoms like high grade fever, head ache, myalgia, joint pain, rashes and retro orbital pain of various degrees. The pain and mild guarding in the Right iliac fossa only invited the suspicious thought of appendicitis.

The Blood investigations (WHO-Diagnostic Criteria for Dengue) Thrombocytopenia < 100,000 cells/cmm,>20% increase in Haematocrit, leucopenia were present. Progressive Thrombocytopenia, progressive leucopenia, NSI-Positivity,

with a positive IgG and IgM enzyme-linked immuno absorbent assay confirmed the Dengue. ESR were normal or slightly raised in patients with DHF and, lower than normal in DSS, but it was elevated in Acute appendicitis with Dengue. CRP was elevated both in DHF and Acute appendicitis.

In our patients with clinical signs of Appendicitis in Dengue, most of the USG findings like Target sign, Fire of ring appearance, transverse diameter of appendix > than 6mm,appendicular wall thickening and peri appendiceal fluid collection were positive. In blood, neutrophil leucocytosis were found. X-ray abdomen showed signs of localized paralytic ileus in 4 cases. x-ray chest showed no pleural effusion or pericardial effusion. The intraluminal obstruction produced by the inflammation of the payers patches produces appendicular luminal narrowing, obstruction as a result of edema and stasis. This produces bacterial proliferation, collection of toxic substances, damage of mucosa and transmural involvement of appendicular wall resulting in appendicitis. Localized microangiopathy in the appendicular wall resulting in vascular compromise leading to mucosal ischemai, mucosal edema,mucosal ulceration, defective mucosal barrier mechanism, mounting of appendicular intraluminal pressure resulting in obstructive or non-perforative or perforative type of appendicitis .

All the Appendicitis cases in Dengue were treated according to the general progression of the disease and the patient's clinical scenario either by conservative or surgical modality.

**Criteria that was followed for discharge of patients:** Absence of fever for >48 hours without antipyretics, normal -BP/pulse rate/respiratory rate, visible clinical improvement, no respiratory distress, platelet count >100,000/ cumm and leucocyte count > 8000 cells/cmm, good appetite, adequate intake of food, appearance of bowel sounds, clearance of bowel, normal urine output and no signs of wound infection or hematoma.

The possibilities that were borne in mind before diagnosing Acute appendicitis in Dengue were-  
1. Simultaneous development of Dengue and Acute appendicitis. 2. Mesenteric lymphadenitis mimicking Acute appendicitis and 3. Acute abdominal pain in RIF due to other cause.

### Conclusion

Dengue fever though presenting as a febrile viral illness, rarely presents as an acute abdominal emergency as acute appendicitis. However, this presentation should be suspected in patients with thrombocytopenia, leucopenia, neutrophil leucocytosis and Right iliac fossa pain particularly, during a viral outbreak of Dengue fever and advised to undergo early surgery to prevent a catastrophe.

This awareness should be highlighted in Tropical and Endemic regions. An eagle view of other complications like acute pancreatitis, acute acalculous cholecystitis & non-specific peritonitis should also be watched for. Even perforation of ileum, jejunum, stomach should also be spied because of the involvement of the peyer's patches. Any patient presenting with Splenomegaly, hepatomegaly, volumetric increase of the

pancreas, Ascitis, pleural effusion, pericardial effusion, hepatic subcapsular collection and presence of fluid in the perirenal space, should alert the physician about DHF/DSS in Dengue endemic areas.

In all our cases USG Abdomen showed usual features of appendicitis. In lap/open surgery of abdomen, minimal ascitis was found and inflammation of appendix was conspicuous. Laparoscopic/open appendicectomy revealed appendicular pathology due to viral infection was only responsible for symptoms, which were confirmed by histopathologic examination post-operatively.

There are multiple complications of Dengue that has to be corrected, as and when required. Delaying or missing the diagnosis of Appendicitis in Dengue infection cannot be taken lightly as it can cause catastrophe. If in doubt open the abdomen. This vital message is important in Dengue prevalent seasons and in endemic areas.

### Reference

1. Kyle J.L., Harris E. Global spread and persistence of dengue. Annual Review of Microbiology. 2008;62:71–92. [PubMed]
2. Promphan W., Sopontammarak S., Pruekprasert P., Kajornwattanakul W., Kongpattanayothin A. Dengue myocarditis. Southeast Asian Journal of Tropical Medicine and Public Health. 2004;35(3, September):611–613. [PubMed]
3. Derycke T., Levy P., Genelle B., Ruszniewski P., Merzeau C. Acute pancreatitis secondary to

- dengue. *Gastroenterologie Clinique et Biologique*. 2005;29(1, January):85–86. [[PubMed](#)]
4. Vinodh B.N., Bammigatti C., Kumar A., Mittal V. Dengue fever with acute liver failure. *Journal of Postgraduate Medicine*. 2005;51(4, October–December):322–323. [[PubMed](#)]
  5. Shuaib F., Todd D., Campbell-Stennett D., Ehiri J., Jolly P.E. Knowledge, attitudes and practices regarding dengue infection in Westmoreland, Jamaica. *West Indian Medical Journal*. 2010;59(2, March):139–146. [[PubMed](#)]
  6. Singhi S., Kissoon N., Bansal A. Dengue and dengue hemorrhagic fever: management issues in an intensive care unit. *Journal of Pediatrics*. 2007;83(Suppl 2):S22–S35. [[PubMed](#)]
  7. Khor B.S., Liu J.W., Lee I.K., Yang K.D. Dengue hemorrhagic fever patients with acute abdomen: clinical experience of 14 cases. *American Journal of Tropical Medicine and Hygiene*. 2006;74(5, May):901–904. [[PubMed](#)]
  8. Wu K.L., Changchien C.S., Kuo C.M., Chuah S.K., Lu S.N., Eng H.L., Kuo C.H. Dengue fever with acute acalculous cholecystitis. *American Journal of Tropical Medicine and Hygiene*. 2003;68(6, June):657–660. [[PubMed](#)]
  9. Brown M.G., Salas R.A., Vickers I.E., Heslop O.D., Smikle M.F. Dengue virus serotypes in Jamaica, 2003–2007. *West Indian Medical Journal*. 2011;60(2, March):114–119. [[PubMed](#)]
  10. Premaratna R., Bailey M.S., Ratnasena B.G., de Silva H.J. Dengue fever mimicking acute appendicitis. *Transactions of the Royal Society of Tropical Medicine and Hygiene*. 2007;101(7, July):683–685. Epub 2007 Mar 21. [[PubMed](#)]
  11. Goh B.K., Tan S.G. Case of dengue virus infection presenting with acute acalculous cholecystitis. *Journal of Gastroenterology and Hepatology*. 2006;21(5, May):923–924. [[PubMed](#)]
  12. Shamim M. Frequency, pattern and management of acute abdomen in dengue fever in Karachi, Pakistan. *Asian Journal of Surgery*. 2010;33(3, July):107–113. [[PubMed](#)]