



## Dyke-Davidoff-Masson Syndrome: A Rare Case in Children

Authors

**Dr. Vijay Baburao Sonawane, Dr. V.A Kotrashetti, Dr. Mumtaz Shariff  
Dr. Kapil Bainade, Dr. Ajay Harit**

### ABSTRACT

*Cerebral Hemiatrophy is rare in clinical practice of children. We report a case of 10 years old male child, who presented in an unusual manner with behavioral abnormalities like aggression, self-mutilating behavior and recurrent seizures while CT Angiography of the brain revealed characteristic features diagnostic of Infantile type of Cerebral Hemiatrophy or Dyke-Davidoff-Masson Syndrome (DDMS).*

**Keywords:** *Dyke-Davidoff-Masson Syndrome, Hemiatrophy*

### INTRODUCTION

Dyke-Davidoff-Masson Syndrome (DDMS) refers as the atrophy or hypoplasia of one cerebral hemisphere (hemiatrophy) which is secondary to brain insult in fetal or early childhood period. It is rarely encountered in clinical practice of children.

We report a case of 10 year old male child, who presented in an unusual manner of behavioral disturbances in the form of aggression and self-mutilating behavior with recurrent seizures and mental retardation. CT Angiography of the brain revealed the DDMS.

### CASE REPORT

A 10 year old male child, born full term to non-consanguineous parents, presented with

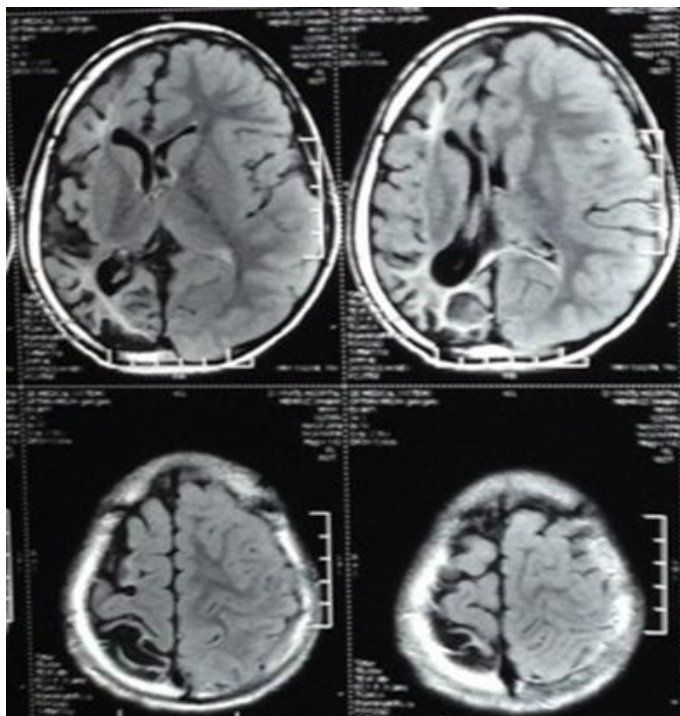
behavioral abnormalities in the form of aggression, self-mutilating behavior and recurrent generalized seizures since the age of 2 years. He also had history of transient left sided hemiparesis at the age of 3 years. There was history of birth asphyxia.

He had delayed milestones of development and microcephaly (< 3<sup>rd</sup> centile) without any neurocutaneous marker or facial asymmetry. The bilateral carotid pulsations were normal with no bruit. Vision and Hearing were normal.

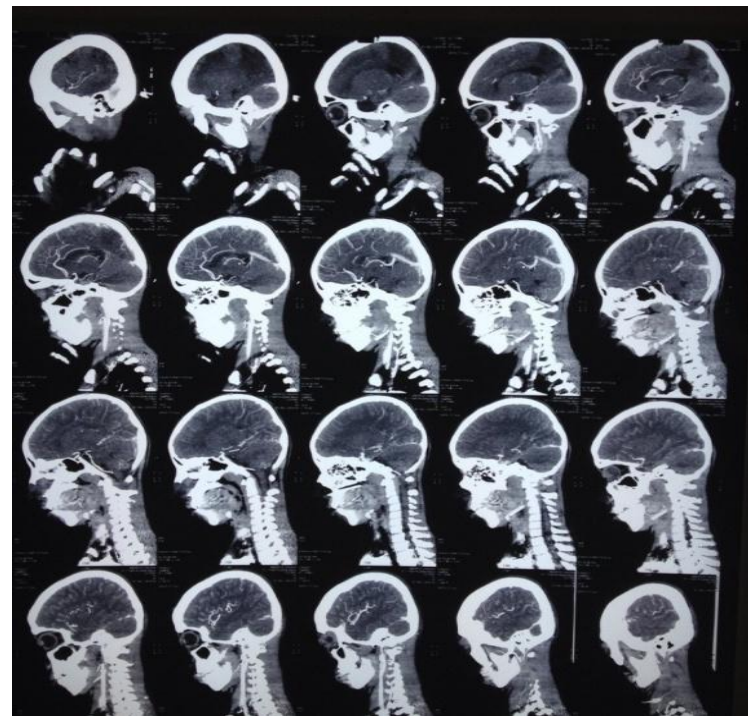
Neurological examination revealed cognitive dysfunction and mental retardation with normal cranial nerves, other systemic examination being normal.

MRI Brain showed large Gliotic areas involving the right fronto-parito-occipital and temporal lobes with dilatation of underlying sulci and exvacuodilatation of ventricular system suggestive of sequel of vascular or hypoxic insult (FIG.1).

CT Angiography of Brain showed generalized prominence of cortical sulci and ventricular dilatation and features suggestive of right cerebral hemiatrophy. There is thickening of right parietal skull vault with hyperpneumatisation of frontal and mastoid sinuses. It shows of thinning right supraclinoid and cavernous portion of right common carotid artery, middle cerebral artery and anterior cerebral artery suggestive of Dyke Davidoff Mason Syndrome (FIG.2). Child was started on anticonvulsant (Valparin) and has been convulsion free thereafter. The child was started on oral valparin; 10 mg/kg in two divided doses, gradually increased every week till the dose of 30 mg/kg is achieved. He responded well thereafter.



**FIG.1** MRI Brain Showing Gliotic areas with sulci and ventricular dilatation



**FIG.2** CT Brain Angiogram Showing F/S/O Right Cerebral Hemiatrophy

## DISCUSSION

Dyke-Davidoff-Masson Syndrome was described as skull radiographic and pneumatoencephalographic changes in their series of 9 patients whose clinical characteristics included hemiparesis, seizures, facial-asymmetry and mental retardation in 1933<sup>[1]</sup>. It is characterized by asymmetry of cerebral hemispheric growth with atrophy or hypoplasia of one side and midline shift, ipsilateral osseous hypertrophy with hyperpneumatisation of sinuses mainly frontal and mastoid air cells with contralateral paresis<sup>[2]</sup>. Seizures can be focal, generalized or complex partial seizure with secondary generalization<sup>[3]</sup>.

Cerebral Hemiatrophy can be of two types, infantile (congenital) and acquired. In congenital hemiatrophy, when the insult occurs in-utero, there is shift of midline structures towards the side of the disease and the sulcal prominence replacing the gliotic tissue is absent<sup>(4)</sup>. The main causes of

acquired type are trauma, tumor, infection, ischemia, hemorrhage and prolonged febrile seizure.

In our case, the findings of right cerebral hemiatrophy with enlarged cortical sulci, microcephaly, recurrent seizures and behavioural problems like aggression and self-mutilating behaviour reflect an onset of brain insult after the completion of sulci formation which was not reported in literature earlier. A possible etiological relation of cerebral hemiatrophy and seizures has been reported by different studies in India<sup>(5,6)</sup>. The condition needs to be differentiated from Basal ganglia germinoma, Sturge Weber syndrome, Linear nervous syndrome, Fishman syndrome, Silver-Russell syndrome and Rasmussen encephalitis<sup>(7,8)</sup>.

Computed tomography and in particular, magnetic resonance imaging are the procedures of choice with respect to assessment of the etiology and extent of cerebral parenchymal involvement in cerebral hemiatrophy.

The treatment is symptomatic and should target convulsion, hemiplegia, hemiparesis and learning difficulties. Prognosis is better if hemiparesis occurs after the age of 2 years and in absence of prolonged or recurrent seizures. Children with intractable disabling and hemiplegia are the potential candidates for hemispherectomy with a success rate of 85%<sup>(9)</sup>.

According to Sharmal et al decreased carotid artery blood flow due to coarctation of aorta can also cause cerebral hemiatrophy<sup>[10]</sup>. Garg et al reported a possible etiological relation of cerebral hemiatrophy with febrile seizures. In their three

cases of cerebral hemiatrophy, Saner and colleagues, reported the middle cerebral artery stroke to be the cause<sup>[4,6]</sup>.

However, according to Shetty et.al, mental retardation is not always present and seizures may appear months or years after the onset of hemiparesis. The clinical findings may be of variable degree according to the extent of the brain injury<sup>[11]</sup>.

In our patient mental retardation was present whereas seizures developed at the age of 2 years.

## REFERENCES

1. Goyal J, Shah V, Rao S & N. Jindal : Dyke Davidoff Masson syndrome inChildren. The Internet Journal of Pediatrics and Neonatology. 2009, 10:2.
2. Pendse NA, Bapna P, Menghani V, Diwan A. Dyke-Davidoff-Masson Syndrome Indian JPediatr.2004;71:943. [PubMed]
3. Hsin YL, Chuang MF, Shen TW, Harnod T. Temporo-spatial analysis define epileptogenic and functional zone in a case of DDMS. 2011;20:713–716. [PubMed]
4. Sener RN, Jinkins JR. MR of cranio-cerebralhemiatrophy. ClinImaging. 1992;16:937. [PubMed]
5. Nair KP, Jaykumar PN, Taly AB, Arunodaya GR, Swamy HS, Shanmugam V. CT in simple partial seizure in children: a clinical and computed tomography study. ActaNeurolScand 1997; 95:197-200.
6. Garg RK, Karak B. Cerebral hemiatrophy: a possible etiological relation with febrile

- seizures. *Indian Pediatrics* 1998; 35: 79-81.
7. Rao KC. Degenerative diseases and hydrocephalus. In: Lee SH, Rao KC, Zimmerman RA, editors. *Cranial MRI and CT*. New York: McGraw-Hill; 1999. pp. 212-4.
  8. Zilkha A. CT of Cerebral hemiatrophy. *Am J Roentgenol*. 1980;135:259-62. [PubMed]
  9. Naraian NP, Kumar R, Narain B. Dyke-Davidoff-Masson Syndrome. *Indian Pediatrics* 2008; 45: 927-928.
  10. Sharma S, Goyal D, Negi A, Sood RG, Jhobta A and Surya M. Dyke-Davidoff Masson Syndrome. *Indian Journal of Radiology & Imaging* Ind, 2006 16:2:165-166.
  11. Shetty DS, Lakhkar BN, John JR. Dyke-Davidoff-Masson syndrome. *NeurolIndia* [serial online] 2003 [cited 2011 Apr 15]; 51:136.