



Pseudo-Exfoliation Syndrome – Correlation of Preoperative Axial Length, Pupillary Diameter, Lens Thickness and Intra Operative Complications During Phacoemulsification

Authors

**Dr. Nikhilesh Wairagde, Dr. Pramod Chipure, Dr. Vikas Mahatme, Dr. Chitra Pande,
Dr. M.D Pawar**

Corresponding Author

Dr. Nikhilesh Wairagde

Senior Consultant At Mahatme Eye Bank Eye Hospital, Nagpur India

ABSTRACT

175 eyes with Pseudo-exfoliation syndrome (PXF) undergoing cataract surgery by phacoemulsification were studied at this prospective non comparative study conducted at Mahatme Eye Bank Eye Hospital, Nagpur, India. The study aimed at finding out association if any between preoperative Axial Length, Pupillary diameter, Lens thickness and intraoperative complications during phacoemulsification. It was found that association of axial length and lens thickness with intraoperative complications was not significant (P value = 0.58 and 0.54 respectively). The mean pupillary diameter in eyes with complications was less (4.60 ± 0.98) mm as compared to 5.61 ± 1.60 mm in eyes without complications. The relation between these groups was statistically significant. (P value=0.018).

Key Words: Pseudo-exfoliation syndrome (PXF), Phacoemulsification, cataract surgery, Axial Length, Pupillary diameter, Lens thickness, intraoperative complications of cataract surgery, PCR (Posterior Capsular Rupture), zonulodialysis, iridodialysis

INTRODUCTION

First described by Lindberg¹ in 1917 and later on by Alfred Vogt² in 1918, Pseudo-exfoliation (PXF) means accumulation of grey white fibrogranular extracellular pseudo-exfoliative

material produced by abnormal basement membrane of ageing epithelial cells in trabeculum, equatorial lens capsule, pupillary margin of iris and ciliary body of the eye.³ It may be an ocular manifestation of a systemic disorder. A study

carried out in South India reported prevalence of PXF as 3.8% and 3.01%^{4,5}

PXF induced iridopathy and phacopathy with zonular instability make routine cataract surgery a challenging task. Scorolliet al⁶ (1998) found that there is 5 times greater risk of intraoperative complications in cataract surgery in such patients as compared with normal cases. This study aims at finding out if there is any association between preoperative Axial Length, Pupillary diameter, Lens thickness and intraoperative complications during phacoemulsification.

MATERIALS AND METHODS

The prospective hospital based non-comparative study was conducted at Mahatma Eye Bank Eye Hospital, Nagpur, India from November 2012 to April 2014. Study protocol was approved by institute's ethical committee. Sample size of 175 was decided according to previous studies⁷. 175 patients with pseudo-exfoliation syndrome undergoing cataract surgery were studied.

Inclusion criteria:

All eyes having slit lamp biomicroscopic picture of pseudo-exfoliation syndrome and undergoing cataract surgery by phacoemulsification.

Exclusion criteria:

1. Previous Ocular trauma
2. Hyper mature cataract
3. Previous intraocular surgery
4. Uveitis
5. Manifest luxation or extensive subluxation of the lens visible preoperatively at Slit lamp examination

6. Cataract extraction combined with additional intraocular surgical procedures (pars planovitrectomy, trabeculectomy, keratoplasty)

Methodology included

Preoperative Evaluation & Investigations:

- Written and informed consent
- Patients were interviewed in detail by using predesigned proforma.
- Measurement of preoperative blood pressure, random blood sugar
- Pre anesthetic check-up by the anesthetist.

Ophthalmic Examination:

- Distance and near visual acuity
- External eye examination
- Intraocular pressure
- Fundus examination using 90 D lens after Pupillary dilation with mydriatic and cycloplegic drops (phenylephrine 5.0% and tropicamide 0.5%),
- Measurement of pupil diameter with the help of caliper.
- K reading
- Anterior segment examination using slit lamp biomicroscopy to look for: pseudoexfoliation material overlens capsule (Figure 1), pupillary border. subluxation of lensphacodonesis:
- Slit lamp examination of lens. Grading of nuclear opacity according to the Lens Opacities Classification System III (LOCS III)⁸ and the Wilmer Classification.⁹

A SCAN BIOMETRY:

A scan was performed (using single machine); by immersion technique and patient in supine position and following parameters noted.

- Axial length
- Lens thickness(measured with 55 to 59 dB)

- IOL power calculation by using SRK-II formula.

SURGICAL TECHNIQUE:-

A standard Phacoemulsification surgery was performed by the experienced surgeons with the use of same kind of microscope and PHACO machine. Intraoperative complications if any were noted down.

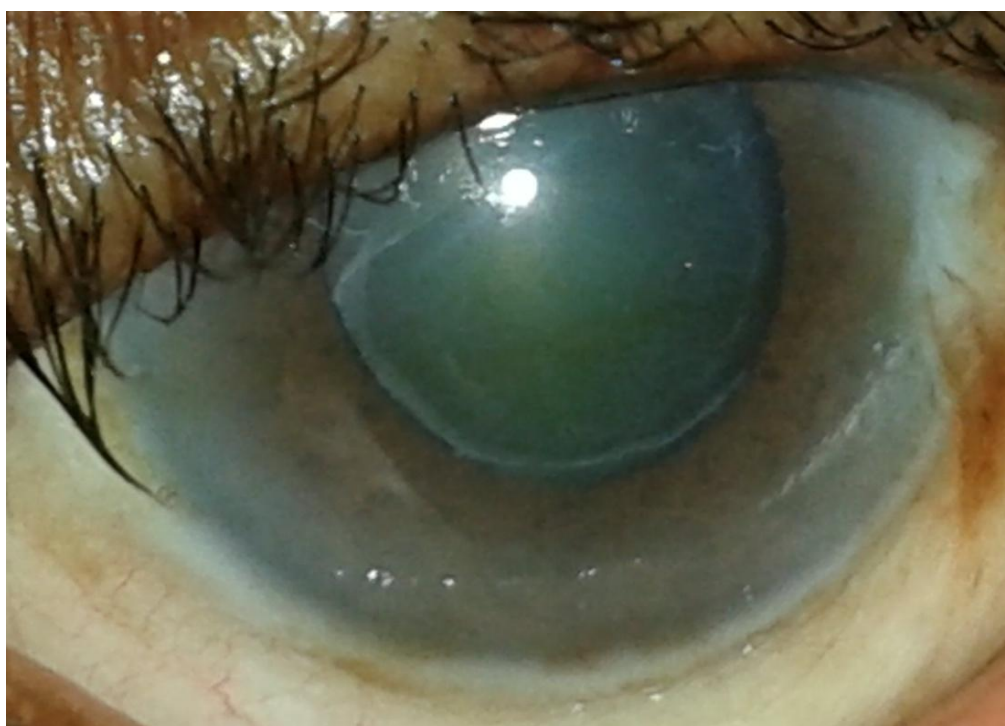


Fig. 1 photograph of pseudoexfoliation material on lens capsule

OBSERVATIONS

175 patients attending the hospital were examined according to study proforma and cataract surgeries were performed by phacoemulsification. Intraoperative complications if any, were noted. Figure 2 shows the complications occurred during cataract surgery by phacoemulsification. A total of

15 (08.56%) complications occurred among all eyes going for cataract surgery. The major complications were PCR with Vitreous loss (5.71%) followed by Zonular dialysis (1.71%) and Iriodialysis (1.14%).

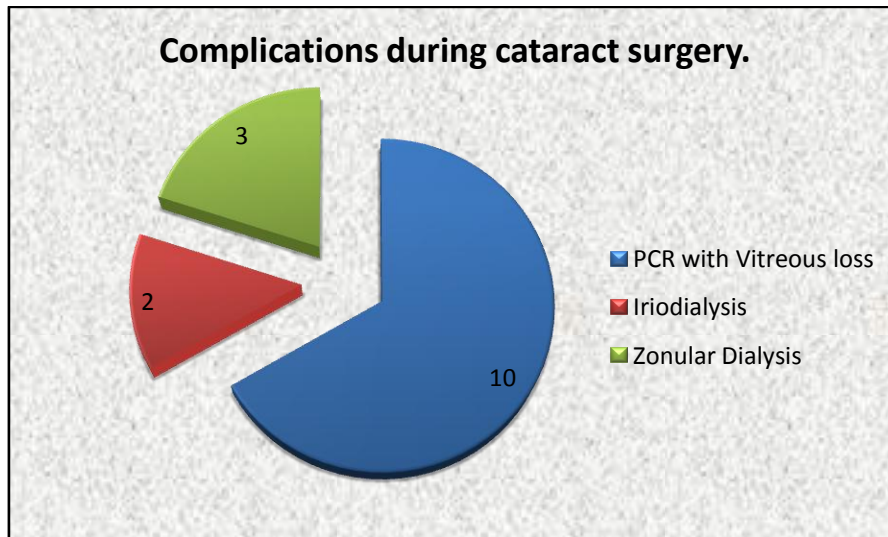


Figure 2: Complications during cataract surgery

Table 1 depicts the relation of axial length of eye with intraoperative complications during phacoemulsification. The mean axial length of eye with complications was more 23.30±0.89 mm as

compared to 23.17±0.87 mm mean axial length of eye without complications. The values were not statistically significant. (P value=0.5751).

Table No.1: Relation of axial length with complication during surgery

Axial length (mm)	With complications	Without complications	t value	p-value
Mean ±SD	23.30±0.89	23.17±0.87	0.5617	P=0.5751, NS

T value=0.5617, P value=0.58 (not significant).

Table 2 shows the association of pupillary diameter and intraoperative complications.

Table No. 2 : Relation of pupillary diameter and complications:

Pupillary Diameter (mm)	With Complications (%)	Without Complications (%)	Total (%)
Poor (2-4)	10 (16.94)	49 (83.06)	59(33.71)
Fair (5-6)	04 (5.06)	75 (94.94)	79 (45.15)
Satisfactory (7-9)	01 (2.37)	36 (97.63)	37 (21.14)
Total	15 (8.57)	160 (91.43)	175 (100)
Chi ² for linear trend = 6.888			
d.f. =2 P value=0.0086, (Highly Significant).			

It was found that nearly 30.86% of eyes had poor and 47.43% had fair dilation during surgery as compared to satisfactory dilatation (21.71%). Pupillary diameter was graded as poor, fair and satisfactory as in above table. It was found that as pupillary diameter decreases incidence of

complications increases. The mean pupillary diameter in complicated eyes was less 4.60 ± 0.98 mm as compared to 5.61 ± 1.60 mm in eyes without complications. The association between small pupil and complication was statistically significant as shown in figure 3.




Figure 3: Mean pupillary diameter and intraoperative complications

In the study, although the mean lens thickness in eyes with complications was more (4.67 ± 0.53 mm) as compared to without complication

(4.59 ± 0.54) mm, the difference between two groups was not significant statistically. (Table 3)

Table No.3: Relation of lens thickness and intraoperative complications

Lens thickness (mm)	With complications	Without complications	t value	p-value
(Mean \pm SD)	4.67 ± 0.53	4.59 ± 0.54	0.6211	0.5353, NS*

T value=0.6211, P value=0.05 (Not significant).

Table 4 demonstrates association of preoperative factors independently with the intraoperative complications during phacoemulsification in eyes

with PXF. Significant association seen between pupillary diameter and intraoperative complications p value=0.016.

Table no. 4: Multiple logistic regression analysis to identify the independent risk factors of intraoperative complication in pseudoexfoliation syndrome

Parameter	Odds Ratio	95 % C.I.	P-value
PD (Pupillary Diameter in mm)	0.48	0.27-0.88	0.0160,S
AL(Axial Length in mm)	1.42	0.70-2.86	0.324,NS
LT(Lens thickness in mm)	1.87	0.60-5.82	0.280,NS

(NS=Not significant, S=Significant)

DISCUSSION

In the study, 175 eyes with pseudoexfoliation syndrome undergoing cataract surgery by phacoemulsification were studied with an objective of association of various preoperative factors to the intraoperative complications during cataract surgery.

In the present study a total of 15 (08.56%) complications occurred. The major complications included Posterior Capsular Rupture (PCR) with Vitreous loss =10 (5.71%) followed by Zonular dialysis=03 (1.71 %) and Iridodialysis =02(1.14%), (Figure 1). Similarly, study conducted by JawadM et al¹⁰ in eyes with pseudoexfoliation syndrome, there was vitreal prolapse in 10.5%, PCR in 9%, Iridodialysis in 1%, decentration of IOL in 4% and Zonular dialysis in 4% patients. In the study done by S. Bangal, et al¹¹ and SkutaGL¹² intraoperative complications were PCR 6%, vitreous loss 4%, zonular dialysis 2% and iridodialysis 2%.

In the study we found that the mean axial length in the eye with intra operative complication was

23.30 ±0.89 mm as compared to 23.17 ±0.87 mm in eye without complications. The values show no significant association between the axial length of eye and complications during cataract surgery. (P value=0.58). Similar findings were seen in study conducted by M. Kuchleet al⁷. In the study he found that the mean axial length of eye during surgery with complications was 22.92 ±1.09 as compared to 23.66 ±1.36 mean axial length of eye without complications. The association was not significant. (P value=0.07).

In the present study, 33.71% of eyes had poor and 45.15% had fair pupillary dilation during surgery as compared to satisfactory dilatation in 21.14%. We found that in eyes with poor pupillary dilatation incidence of complication is more 10(16.96%) as compared to other two groups. The difference between poor, fair and satisfactory dilatation was statistically significant. (Chi²=6.89; P value=0.0086 highly significant.). Also, mean pupillary diameter in eyes with intraoperative complication was small (4.60 ±0.98 mm) as compared to (5.61 ±1.60 mm) in eyes without

intraoperative complication. The relation between these groups was statistically significant (P value=0.018) (Table no. 8). Small pupil is risk factor in a cataract surgery in eyes with PXF. The eyes with PXF dilate less than normal. This leads to increase chances of intraoperative complications mostly posterior capsule rupture during cataract surgery.

Mean lens thickness in eyes with intraoperative complication was more (4.67 ± 0.53 mm) as compared to that in non-complicated cases (4.59 ± 0.54 mm). However the difference between these two groups was not statistically significant. (P value=0.5353). Thus there was no statistically significant association between lens thickness and complications. Similar findings was found in the study done by Kuchle et al⁷. The mean axial length in eyes with complication eyes was 22.92 ± 1.09 mm as compared to 23.66 ± 1.36 mm in eyes without complications. The relation between these groups was not statistically significant in their study as well.

In present study Multiple Logistic regression analysis was performed to identify the independent risk factors for incidence of intraoperative complication which describes the association of various preoperative factors to the intraoperative complications. It was shown that small pupillary diameter was the only significant factor out of the three, among eyes with pseudoexfoliation syndrome operated for cataract surgery by phacoemulsification. The other factors like axial length of eye and lens thickness showed no statistically significance among intraoperative complications.

CONCLUSION

The present study showed that preoperative axial length and lens thickness have no relation with intraoperative complications after Phacoemulsification in eyes having pseudoexfoliation syndrome. However, there was statistically significant association between pupillary diameter (PD) and intraoperative complications; lesser the PD, more are the intraoperative complications.

REFERENCES

1. Lindberg JG. Clinical investigations on depigmentation of the pupillary border and translucency of the iris in cases of senile cataract and in normal eyes in elderly persons: ACTA Ophthalmol Suppl 1989; 190:1-96
2. Vogt A. Einneues Spaltlampenbid des Pupillargebietes; Hellblauer Pupilear saumfillzmit Nautchenbildunzaus der Lisenvorderkapsel. Klin Monatsbl Augenheilkd 75:1; 1925
3. Sood N.N. Prevalence of pseudoexfoliation of the lens capsule in India; ACTA Ophthal.1968; 46:211-214.
4. H. Aravind, P Raju, P.G. Paul, M Baskaran, S Ve Ramesh, R J George, C McCarty, L Vijaya ; Pseudo-exfoliation in South India; Br. J of Ophthalmol 2003; 87:1321-1323 doi: 10.1136/bjo.87.11.1321
5. Thomas R, Nirmalan PK, Krishnaiah S. Pseudo-exfoliation in southern India: The Andhra Pradesh eye disease study; Invest Ophthalmol Vis Sci 2005; 46:1170-6

6. Scorolli L, Campos E.C, Bassein L, Meduri R.A. pseudo-exfoliation syndrome: A cohort study on Intraoperative complications in cataract surgery. *Ophthalmologica* 1998; 212:278-280 (DOI: 10.1159/000027307)
7. Michael kuchle, Arne Viestenz, Peter Martus, Angelika Handel, Anselm Junemann, , and Gottfried O. H. Naumann; Anterior chamber depth and complications during cataract surgery in eyes with pseudoexfoliation syndrome; *American journal of ophthalmology*, 2000, March;129(3); 281-285.
8. Chylack LT, Wolfe JK, Singer DM, Leske MC, Bullimore MA, Bailey IL, Friend J, McCarthy D, Wu SY. The lens opacities classification system III. *Arch Ophthalmol*. 1993;111:831–836.
9. Taylor HR, West SK. A simple system for the clinical grading of lens opacities. *Lens Res*. 1988; 5:175–181.
10. Jawad M, Nadeem AU, Khan AH, Aftab M. Complications of cataract surgery in patients with pseudoexfoliation syndrome. *J Ayub Med Coll Abbottabad*. 2009 Apr-Jun; 21(2):33-6
11. Surekha Bangal, Akshay Bhandari, Pratik Gogri. Outcome of Cataract Surgery in Patients with pseudoexfoliation. *Del J Ophthalmol* 2012;23(3):183-186
12. Skuta GL, Parrish RK 2nd, Hodapp E, Forster RK, Rockwood EJ. Zonular dialysis during extracapsular cataract extraction in pseudoexfoliation syndrome. *Arch Ophthalmol*. 1987 May ;105 (5): 632-4.