

www.jmscr.igmpublication.org

Impact Factor 3.79  
ISSN (e)-2347-176x



## Incidence of Chronic Groin Pain in Patients Undergoing Lichtenstein's Hernioplasty

Authors

**Rajesh G Chandnani<sup>1</sup>, Viral Patel<sup>2</sup>, Abhishek Chinya<sup>3</sup>, K N Patki<sup>4</sup>, J K Desai<sup>5</sup>**

Surat Municipal Institute of Medical Education & Research (SMIMER), Shahara Darwaja, Umarwada, Surat,  
Gujarat state

Email: rgchandnani@gmail.com, virmed@gmail.com, drabhishekchinya@yahoo.com,  
dr.kiranpatki@gmail.com

### ABSTRACT

*Chronic groin pain affects about a third of patients undergoing Lichtenstein's repair of inguinal hernia. This is a frequently under-stated list of complication of this common technique for repair of inguinal hernia. In view of its associated distress to the patient affecting their quality of life after surgery and having reviewed literature I decided to find out the incidence of this complication and its effect on quality of life affecting patients undergoing Lichtenstein's repair of Inguinal hernia at our institute.*

*30 patients were followed up to three months after surgery to find out the incidence of groin pain and quality of life. 40% of patients had occasional-mild groin pain and one patient had moderate to severe pain prompting him to seek numerous consultations for the same. Its affect on quality of life was also assessed and is given in this paper.*

**Keywords-***Chronic groin pain, Inguinal hernia, Lichtenstein's repair, open inguinal hernia repair*

### INTRODUCTION

Henry Kissinger once stated that "soccer is a game that hides great complexity in the appearance of simplicity." He could have very well been

describing an inguinal hernia repair. Inguinal hernia repair can prove to be very challenging if strict adherence to anatomic planes of dissection is not followed and without the knowledge of proper

anatomy. One of the most common complications in postoperative inguinal hernia patients is the occurrence of post hernia repair chronic groin pain, defined as pain that persists after the normal healing process has occurred typically three months after surgery. Chronic groin pain is most often the result of nerve injury sustained during improper dissection. Careful dissection of the five major nerves encountered during the procedure and their protection can help to reduce this complication substantially and its concomitant adverse effects on quality of life. Most surgeons have been more concerned with recurrence rates than with occurrence of post herniorrhaphy chronic groin pain. However, with the advent of tension-free mesh repairs, inguinal hernia recurrences are uncommon, unless underlying patient factors predispose to the development of hernias. Furthermore, not all patients suffering with chronic groin pain seek medical assistance, especially for mild symptoms. Few are referred back to the operating surgeon, and only a small percentage of patients seek help from pain specialist. In fact, one study demonstrated that after 24 to 36 months of follow-up, approximately 30% of patients undergoing inguinal herniorrhaphy reported pain or discomfort and nearly 6% reported high-intensity pain resulting in inability to perform activities of daily living. This was in comparison with a recurrence rate of only 4.5%. The point of maximal tenderness is usually at the pubic tubercle,

usually from incorporation of a stitch or stapler into the periosteum. In recent years, emphasis has shifted toward evaluation of the patient's quality of life after surgical intervention and relief of symptoms, with presence of inguinal pain viewed as an endpoint in evaluating hernia surgery. This emphasis is of particular importance. If a patient is undergoing herniorrhaphy to reduce inguinal pain, it would be a disservice to cause undue pain secondary to improper groin dissection. It is also crucial to determine whether any other associated pathology exists and can contribute to the sensation of inguinal pain because this will lead to persistent pain after surgical intervention.

Anatomical considerations: To prevent technical errors resulting from improper nerve dissection a thorough understanding of the innervations to the groin and the anatomic locations of the nerves is essential for their preservation and protection from injury. This will help to not only better understand the aetiology of the problem, but also to provide a means of preventing this complication. There are five main nerves that must be identified and preserved during an inguinal herniorrhaphy: the ilioinguinal, the iliohypogastric, the genitofemoral, and the lateral femoral cutaneous and the femoral nerves. Table 1 presents a complete review of the origin and course of these vital structures.

Table No 1.

| Nerves                    | Origin                   | Course   | Function  |
|---------------------------|--------------------------|--|---|
| Ilioinguinal              | T12-L1<br>Nerve<br>Roots | It emerges from the border of the psoas major, passes the quadrates lumborum and ilicus, perforates the transverses abdominis and then accompanies the spermatic cord.   | Supplies sensory innervation to the proximal and medial thigh. In females it innervates the mons pubis and labium majus; in males it innervates the root of the penis and upper scrotum.  |
| Iliohypogastric           | T12-L1<br>Nerve<br>Roots | Same as ilioinguinal   | Same as ilioinguinal  |
| Genitofemoral             | L1-L2<br>Nerve<br>roots  | It emerges from the medial border of the psoas muscle and subsequently divides into a genital and femoral branch. The genital branch pierces the transversalis fascia, where it travels with the spermatic cord to the scrotum; the femoral branch travels with external iliac artery and passes beneath the inguinal ligament and extends to the anterior surface of the thigh. | The genital branch supplies sensation to the mons pubis and labium majus. In males it supplies sensation to the scrotum and motor fibers to the cremasteric muscle. The femoral branch supplies innervations to the anteriolateral thigh. |
| Lateral femoral cutaneous | L2-L3<br>Nerve<br>Roots  | It emerges from the lateral border of the psoas muscles, goes towards the anterior superior iliac spine and passes under the inguinal ligament.  | Provides sensory innervations to the anteriolateral thigh. Injury most commonly results in severe burning sensation along its course.   |
| Femoral                   | L2-L3<br>Nerve<br>Roots  | Emerges at the inferior border of the psoas muscle and passes beneath the inguinal ligament to innervate the thigh.  | Provides sensory branches to the anterior thigh. Predominant function is motor innervations to the quadriceps resulting in muscle atrophy if injured.   |

**MATERIALS AND METHODS**

This prospective study was carried out in a public hospital in the city of Surat over a period of one year. Patients with primary inguinal hernia in the age group of 18-60 years were included. The study was carried out after permission of ethical committee of Surat Municipal Institute of Medical Education and Research (SMIMER).

**AIM:** To find out the incidence of chronic groin pain in patients operated by Lichtenstein's technique at our institute (SMIMER).

The patients will be followed up for three months for assessments of groin pain and discomfort following surgery.

**Study Design:** Cohort (Prospective) study.

**Setting:** Department of surgery, Surat Municipal Institute of Medical Education and Research.

**Study Period:** 01/June/2010-31/May/2011.

**Inclusion Criteria:**

1. Inguinal hernia repair by Lichtenstein's technique.
2. Prolene mesh
3. Adults above 18 years of age.

**Exclusion Criteria:**

1. Recurrent hernia
2. Obstructed hernia
3. Strangulated hernia
4. Prostatic enlargement
5. Children below 18 years of age.
6. Previous h/o lower abdominal surgery.
7. Pre-operative groin pain.
8. Chronic analgesic use for other painful conditions.
9. Neurological disease.
10. Malignancy.

Those with diabetes mellitus and hypertension were controlled prior to surgery. Those with cough, constipation were adequately treated and taken for surgery after they were free of symptoms. Habits like smoking were discouraged and patients were motivated to give them up.

**OPERATIVE TECHNIQUE****ANAESTHESIA:**

All patients were operated under spinal anaesthesia.

**INCISION:**

An adequate incision 1.5 cms above and parallel to medial two thirds of inguinal ligament was taken.

**INGUINAL CANAL EXPOSURE:**

The external oblique aponeurosis was slit open from superficial ring to a distance just lateral to the deep inguinal ring along the line of its fibres. Flaps of external oblique aponeurosis were raised to raise the upturned part of the inguinal ligament and the pubic tubercle below and the conjoint tendon arch superiorly.

**HOOING UP THE CORD:**

The cord is then hooked up at the pubic tubercle and freed up to the deep inguinal ring by means of blunt and sharp dissection and held with a cord tape.

**EXCISION OF CREMASTRIC TISSUE:**

The cremasteric muscle enclosing the cord is opened up to form upper and lower leaves. These are then separated from the cord and the sac and divided between clamps and ligated. The inguinal nerves (ilioinguinal, iliohypogastric and genital branch of genitofemoral nerve) are protected.

### DISSECTION OF THE SAC

The sac is then identified and completely freed from the cord. In case of the indirect hernia the dissection is carried out till the preperitoneal fat is seen at the deep inguinal ring.

### DEALING WITH THE SAC

In case of indirect hernias the sac was opened, content reduced, sac high ligated at the deep ring and excised while for the direct sacs they were simply inverted.

### LICHTENSTEIN'S HERNIA REPAIR

In case of direct hernia transversalis fascia was repaired with continuous suture of 2/0 prolene. A 4 X 6 inch prolene mesh was placed and overlapped laterally around the cord at the level of deep inguinal ring after splitting the mesh laterally to snugly fit the cord at deep ring and admitting tip of little finger to ensure that it is not tightly wrapped around the cord. The mesh was fixed inferiorly to inguinal ligament with continuous sutures of 2/0 prolene and superiorly to 3-4 cms superior to the inferior margin of conjoint tendon with 3-4 random interrupted stitches of 2/0 prolene taking care to avoid nerve. A stitch was also taken lateral to the cord fixing the overlapped part of the mesh together.

### CLOSURE

Cord is repositioned followed by the closure of external oblique aponeurosis with 2/0 chromic catgut continuous sutures and an adequate new superficial ring is reconstructed. Skin closure is achieved with interrupted 2/0 ethilon sutures.

All the surgeries were carried out above the level of 2<sup>nd</sup> year surgery resident. Also whenever 2<sup>nd</sup> year or

3<sup>rd</sup> year residents operated they were always assisted by seniors of the unit.

Pain was assessed using Visual Analog Scale (VAS). VAS is a 10 cms scale with 0 being no pain felt by the patient and 10 being the worst pain felt by the patient.

/1—2—3—4—5—6—7—8—9—10/

10 cms

Symptom score of 0 being no pain and 10 being worst possible pain felt by the patient. Pain was assessed at day 0, 5<sup>th</sup> day and three months after surgery.

Gilbert designed a classification for primary and recurrent inguinal hernias done through an anterior approach. It is based on evaluating 3 factors:

1. Presence or absence of a peritoneal sac
2. Size of the internal ring
3. Integrity of the posterior wall of the canal

Five types of primary and recurrent inguinal hernias.

- Types 1, 2 and 3 are indirect hernias; types 4 and 5 are direct.
- Type 1 hernias have a peritoneal sac passing through an intact internal ring that will not admit 1 fingerbreadth (ie < 1 cm); the posterior wall is intact.
- Type 2 hernias (the most common indirect hernia) have a peritoneal sac coming through a 1-fingerbreadth internal ring (ie < 2cm); the posterior wall is intact.
- Type 3 hernias have a peritoneal sac coming through a 2-fingerbreadth or wider internal ring (ie > 2cm).
- Type 3 hernias frequently are complete and often have a sliding component. They begin

to break down a portion of the posterior wall just medial to the internal ring

- Type 4 hernias have a full floor posterior wall breakdown or multiple defects in the posterior wall. The internal ring is intact and there is no peritoneal sac.
- Type 5 hernias are pubic tubercle recurrence or primary diverticular hernias. There is no peritoneal sac and the internal ring remains intact. In cases where double hernias exist, both types are designated(e.g, types 2/4).
- Informed consent was taken from the patient before the surgery.
- Inj Diclofenac sodium post-op, thereafter Tab Ibuprofen 400mg, three times a day for the first three days was given to the patient immediately after surgery.
- **Data collection and analysis:**Data will be collected by the data collection sheet and analysed using SPSS software.
- **Health questionnaire**(for assessment of QOL due to pain):
  1. Mobility
    - A. I have problem in walking.
    - B. I have some problem in walking
    - C. I am confined to bed.
  2. Self care(Washing, dressing)
    - A. I have no problem in selfcare.
    - B. I have some problem in selfcare.
    - C. I am unable to wash and dress myself.
  3. Usual activity(Work,study and housework)
    - A. I have no problem in usual activity.
    - B. I have some problem in usual activity.
    - C. I am unable to do usual activity.
  4. Pain/Discomfort

- A. I have no pain /discomfort.
- B. I have moderate pain/discomfort.
- C. I have extreme pain/discomfort.

#### 5. Anxiety/depression

- A. I am not anxious/depressed.
- B. I am moderately anxious/depressed.
- C. I am extremely anxious /depressed.

#### RETURN TO WORK:

All patients were encouraged to return to work after suture removal.

#### FOLLOW UP:

Patients were asked to follow up three months after surgery. Those who didn't follow up enquiries were made on phone. Patients were asked to follow up on the 5<sup>th</sup> day also who for some reason requested early discharge.

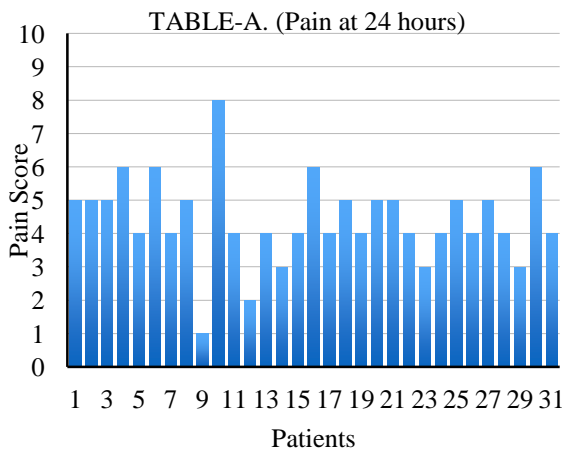
#### RESULTS

31 patients were operated in this trail to assess the incidence of groin pain in operated patients.

- a) 19 patients had right sided, 10 patients had left sided and 2 patients had bilateral inguinal hernia.
- b) 22 patients had indirect inguinal hernia (gilbert's type 1-3) and 9 patients had direct inguinal hernia (gilbert's type 4).
- c) All patients were male patients in this trail.
- d) One patient did not follow up three months after surgery and also could not contacted on phone, so he was not included in the symptom analysis at three months after surgery.

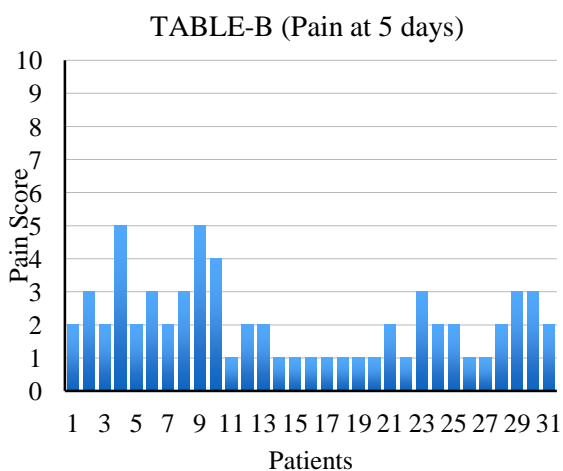
**PAIN SCORE AT 24 HOURS**

TABLE A show pain at the end of 24 hours. 12 patients had pain equal to or more than moderate pain (pain score->5) at the end of first 24 hours with one patient having sever pain (pain score 8) at 24 hours average pain score was 4.



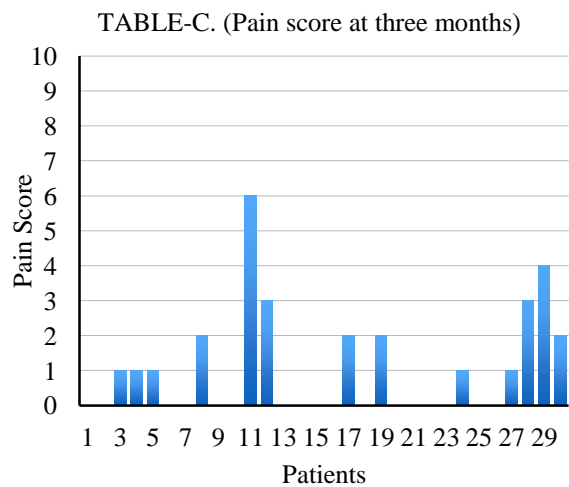
**PAIN SCORE AT 5 DAYS**

TABLE B shows pain at end of 5 days. All the patients had equal to and less than moderate pain withoutanalgesics. Average pain score was 2. P value <0.05.which is statistically highly significant difference in pain between 24 hours and 5 days. It was calculated using SPSS software.



**PAIN SCORE AT 3 MONTHS**

TABLE C shows pain at the end of 3 months. P value<0.05, which is statistically highly significant differenceinpainbetween 5 days and 3 months. It was calculated using SPSSsoftware. 12 patients had mild pain/discomfort of whichmajority had ‘occasional mild pain/discomfort and mild pain/discomfort only during prolonged



standing/working/straining. 1 patient had pain score of 6 and he had some difficult in walking because of continuous pain. He was anxious also and has consulted other doctors for pain. He has been advised by us to follow up for treatment of pain. Average pain score for the group of patients having pain/discomfort was 2, at the 3 months after surgery.

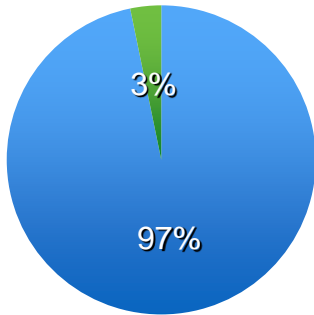
**WOUND INFECTION**

One patient had serous collection which was treated with removal of the affected stitches and draining the collections. In the rest sutures were removed on 10<sup>th</sup> post-op day.

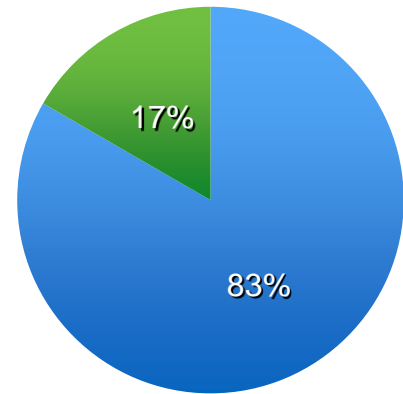
QUALITY OF LIFE

Usual activity (Work, Study, Housework)

■ I have no problem in usual activity    ■ I have some problem in usual activity

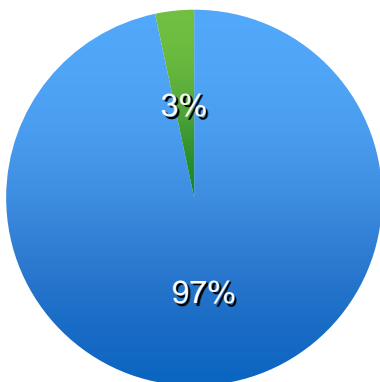


Mobility  
 ■ No problem in walking    ■ Some problem in walking



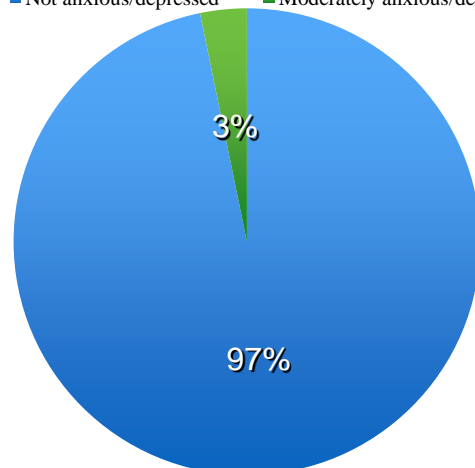
Self care (Washing, Dressing)

■ I have no problem in self care    ■ I have some problem in self care



Anxiety / Depression

■ Not anxious/depressed    ■ Moderately anxious/depressed





## DISCUSSION

In this prospective study the aim was to find out the incidence of post operative chronic groin pain in hernia repair done by Lichtenstein's technique which is the most common technique practised at our institute. The reported incidence of chronic groin pain after inguinal hernioplasty in various studies around the world [2],[3],[4],[6],[10] varies from 0% to 50%. The number of patients afflicted with chronic groin pain following inguinal hernioplasty is grossly underestimated and unacceptably high. In our study out of 31 patient 1 patient did not follow up for assessment 3 months after surgery nor could he be contacted on phone so he was excluded from the assessment of chronic groin pain.

Therefore out of 30 patients 12 patients had mild pain/discomfort (40%) of which majority had 'occasional' mild pain/discomfort and mild pain/discomfort only during prolonged standing/working/straining. This is consistent with the average incidence of groin pain around the world. One patient had chronic groin pain sufficiently severe (pain score 6/10) at the end of three months so has to cause him some difficulty in walking. He was anxious also as he went around consulting different doctors for pain. He was advised to follow for treatment for pain at our hospital. Multiple hypothesis have been formulated to attempt to try to explain the reason of chronic groin pain after hernia repair ranging from entrapment of nerve in the suture to chronic fibrosis and mesh acting as a foreign body following extensive groin dissection in open hernia surgery. Direct injury to nerve that result in partial or complete transaction can lead to neuroma formation

and subsequent development of chronic pain. Some have implicated the role of mesh as well it has been demonstrated experimentally that when peripheral nerve tissue comes in contact with polypropylene mesh, myelin degeneration, oedema and fibrosis result and can lead to neuralgia and peripheral neuropathy. Multiple studies have examined the issue and the weight of the evidence seems to favour a lack of association with mesh and the occurrence of chronic pain. A description of six specific manoeuvres to reduce the risk of nerve injury during open herniorrhaphy has been described avoiding indiscriminate division of subcutaneous tissue, avoiding removal of the cremasteric muscle fibre, avoiding extensive dissection of the ilio-inguinal nerve, identifying and preserving all neural structure, avoid making inguinal ring too tight and avoiding placement of suture in the lower edge of the internal oblique muscle. Nerve trauma can be caused by several mechanisms including partial or complete transaction, stretching, contusion, crushing, cautery damage or suture compression. The best modality for treatment of chronic groin pain is yet to be elucidated and is an area that continues to perplex even the most competent of surgeons. Treatment modalities include oral analgesics, regional nerve blocks, re-operation with mesh excision and surgical neurectomy. Continued experience with this long term complication of inguinal herniorrhaphy will undoubtedly result in the other proposed solutions.

## CONCLUSION

Chronic groin pain after inguinal hernia repair is a well recognised complication which has not been given due importance when it comes to pre-operative counselling of patients in OPD. Failure to do so may offset some of the advantages of this surgery and given its worldwide occurrence to the tune of 0-50% (average 30-40%). It may bring some disrepute to this type of surgery in the mind of patients, though majority of these occurrences are mild, occasional pain. Moderate to severe pain sufficient to interfere in daily activities occurs in 3-6% of patients. In our series it was 3.3%. As already discussed though the exact aetiology of chronic groin pain remains obscured methods by which this complication can be reduced to minimum are: Identification of all three inguinal nerves (at least two, ilioinguinal and iliohypogastric nerve if the genital branch of genitofemoral nerve which is difficult to identify is not identified) and its gentle handling and safeguard, tissue respect (minimum dissection of subcutaneous tissue and avoiding excision of cremasteric muscle), avoiding tight internal ring by wrap around the mesh and avoiding taking sutures near the nerves. If in doubt about involvement of nerves in suture placement it is better to excise the nerve beyond the internal ring. Studies have shown that this reduces the incidence of post operative groin pain though local numbness may be a problem which reduces considerably in the following months due to taking over by the adjoining nerves.

## ACKNOWLEDGEMENTS

Dr Rajesh Chandnani, Assistant Professor Surgery.  
Dr Viral Patel, Resident, Surgery  
Dr Abhishek Chinya, Resident, Surgery  
Dr K N Patki, Associate Professor, Surgery  
Dr J K Desai, Professor, Surgery

## REFERENCES

1. British journal of surgery 2002,89, 1476-1479
2. Annals of surgery, vol. 233, No.1, 1-7.
3. Annals of surgery, Vol.244, Number 1, July 2006
4. Br J Surg.2010 Aug;88(8): 1122-6.
5. Int Surg. 2010 Jan-Mar;95(1):40-8
6. Surg cli of N.America, Feb 2008, p208
7. Hernia 2004;8(4):343-9.
8. Clin J Pain 2003;19:48-54.
9. Am J Surg.1989;157:331-333.
10. Ann R CollSurg Engl.2007 April;89(3):218-220