



Management of Posterior Urethral Injuries - Our Experience

Authors

S V Krishna Reddy¹, Ahammad Basha Shaik²

Department of Urology¹, Community Medicine & Biostatistics²,

Narayana Medical College, Nellore, Andhra Pradesh, India

Corresponding Author

Dr. S.V.Krishna Reddy

M.S.,M.Ch (Urol)

Professor, Department of Urology

Narayana Medical College & Hospital, Nellore-524001, Andhra Pradesh, India

Email: vijaya.nel@gmail.com

Abstract

Background: *The management of posterior urethral injuries is controversial and much debate continues regarding the immediate, early and delayed definitive therapy.*

Objective: *We report our institutional experience and long term results of early endoscopic realignment of traumatic posterior urethral injuries and its comparison with delayed realignment and delayed open urethroplasty.*

Materials and Methods: *A total of 112 cases of post traumatic urethral injuries were admitted between May 2002 to December 2012, Out of which only complete disruption posterior urethral injuries were included in this study, which constituted 48 patients. These patients were divided into 3 groups. All patients had initial suprapubic urinary diversion. Group-1 [n-21] included patients who underwent early primary endoscopic realignment done within 6-8 days after injury. Group-2 [n-12] included patients who were referred for delayed realignment after 4-6 weeks. Group-3 [n-15] included patients who had delayed open urethroplasty after 3 months. The frequency of urethral dilatation, optical internal urethrotomy, was evaluated over a period of 18 months.*

Results: *Group-1 [n-21] Patients who underwent early primary endoscopic realignment had a mean frequency of urethral dilatation of 2.6 ± 1.8 and optical internal urethrotomy at 1.4 ± 1.6 while Group-2 [n-12] patients who underwent delayed realignment had a mean of urethral dilatation of 0.8 ± 1.2 and optical internal urethrotomy at 3.6 ± 1.4 . Group-3 [n-15] patients had mean frequency of urethral dilatation at 1.2 ± 0.9 and optical internal urethrotomy at 0.8 ± 0.4 over period of 18 months.*

Conclusion: *Early primary endoscopic realignment in our experience reduces time to spontaneous voiding, decrease the need for major reconstructive surgery and long term supra pubic urinary diversion*

Key Words: *urethral injury, pelvic fracture, endoscopic realignment*

INTRODUCTION

Urethral disruption occurs in approximately 10% of pelvic fractures, but almost all membranous urethral disruption related to blunt trauma have an associated pelvic fracture [1]. The pelvic fractures that lead to urethral disruptions are usually secondary to motor-vehicle accidents (68%-84%) or falls from heights and pelvic crush injuries (6%-25%) [2]. The management of posterior urethral disruption which is a major complication of pelvic fracture secondary to blunt trauma is controversial and much debate continues regarding the timing and method of management [3]. The primary goals of management of posterior urethral injuries are to re-establish urethral continuity, avoid stricture formation, and preserve sexual function. Traditionally, as described by Waterhouse the main stay of therapy was simply creating a suprapubic cystostomy and delayed repair was performed 3 months later [4-7]. Recently early primary endoscopic urethral realignment has been advocated to re-establish the posterior urethra as enabling shorter hospitalization, shorter operative time, less blood loss and less urethral stricture [8-11]. Advances in

endourology have made endoscopic management of most of these injuries feasible without greatly compromising on the final result. The published results of these different posterior urethral injury management methods appear quite varied.

In this study, we report our institutional experience and long term results of early primary endoscopic realignment verses delayed realignment and delayed open urethroplasty for posterior urethral disruption.

MATERIALS AND METHODS

A total of 112 cases of post traumatic urethral injuries were admitted between May 2003 to December 2013. The American Association for Surgery and Trauma (AAST) grading was used to divide urethral injuries into five types which emphasises on the degree of disruption and degree of urethral separation [12].

The American Association for Surgery and Trauma (AAST) injury severity scale for urethra:

Type-1- Contusion

Type-2- Stretch injury but no disruption of urethra

Type-3- Partial disruption of urethra

Type-4-Complete disruption with urethral separation <2cm

Type-5-Complete disruption with urethral separation >2cm

Out of which only male posterior urethral injuries Type-4 and Type-5 injury cases were included in this study, which constituted 48 patients. 36 patients had type-4 and 12 patients had type-5 injury. Our study was prospective, which was approved by an institutional ethics committee. Written informed consent was taken from all patients for photographing, recording and also its use for scientific and medical education purposes. To minimize selection bias and ensure that the type injury was homogeneous, inclusion criteria were designed to screen complete posterior urethral disruption cases. After paying attention to the immediate life-threatening injuries and condition, the initial urological treatment of these patients was to insert suprapubic catheter to relieve the urinary retention and divert urine from injury site. All patients were subjected to X-ray pelvis, retrograde urethrogram and ultrasonography. X-ray pelvis was done to assess the type of fracture (Fig-1). Retrograde urethrogram to identify the type of urethral injury, whether it was partial or complete (Fig-2). In few cases where there was suspicion of associated bladder injury, micturating cystourethrogram or a Computerized tomography of abdomen and pelvic films was done. Abdominopelvic Computerized tomography were performed to identify the urethral defect length, the bladder neck competence, the prostate position, and the extent

of pelvic hematoma. These patients were divided into 3 groups. Group-1 [n-21] included patients with type-4 injury who underwent early primary endoscopic realignment done within 6-8 days after injury. Group-2 [n-12] included patients with type-4 injury who underwent immediate suprapubic cystostomy and referred for delayed realignment 4-6weeks. Group-3 [n-15] included 12 patients who had type-5 injury and who underwent immediate suprapubic cystostomy and delayed open urethroplasty after 3 months. 2 patients with type-4 injury had delayed open urethroplasty after 1year.

For Group-1 [n- 21], all patients had initial suprapubic cystostomy for urinary diversion. The urethral continuity was then restored within two weeks by endoscopic urethral realignment as described by Towler and Eisen [14,15]. Urethral catheter was left in place for an average of six weeks after realignment. For Group-2 [n: 12] patients cystostomy tube was left in place for more than four weeks until retrograde and antegrade urethrogram showed secondary healing of urethra. The urethral continuity was restored by optical internal urethrotomy by suprapubic bougie guidance or suprapubic fiberoscopic aid as described by Chuang [16]. Urethral catheter was left in place for another 4-6 weeks. For Group-3 [n-15] 12 patients cystostomy tube was left in place for 3 months and delayed open urethroplasty was done and urethral catheter left in place for another 4-6 weeks. In 3 patients delayed open urethroplasty was done after 1 year due to failed optical urethrotomy in one patient in group-1 and two patients in group-2. At the end of 4-6 weeks

urethral catheter was removed and all patients were followed up at regular interval for quality of urinary flow, incontinence, impotence and stricture formation by uroflowmetry, post-void residual urine, and repeat urethrogram as indicated. The need for further urological interventions (e.g. urethral dilatation or internal urethrotomy) and the incidence of complication (e.g. urinary incontinence, urethral stricture, impotence) were then recorded for each group.

Statistical analysis

The data has been entered into the MS-Excel and analyzed by using IBM SPSS V.20.0 (SPSS, Chicago, IL, USA). Categorical variables, number and percentages were calculated. For continuous variables, mean values were calculated.

RESULTS

All the 48 patients in this study were males and more than half had motorcycle accidents. The mean age of the patients was 32, and there was no statistical difference in age or associated injuries between groups. Group-1 [n-21] patients required 2.6 ± 1.4 units of blood during the urethral realignment, but no transfusion was required in group-2 [n- 12] who was delayed realignment patients. Group-3 [n-15] patients required 1.2 ± 0.4 units of blood. Following the initial treatment, urethral stricture complications developed in 47 out of the 48 cases (97.9%). Only one patient in Group-1 [n-21] who had early primary realignment was free from stricture. One patient in group-1 was lost to follow-up within one year. Therefore a total of 47 completed the 18 months follow-up. The frequency of internal

urethrotomies during 18 months follow up period was much higher in Group-2 [n- 12] than in Group-1[n-20] patients (3.2 ± 1.2 vs 1.9 ± 0.8) and much less in Group-3 patients (0.9 ± 0.4) to overcome recurrent urethral stricture. The average rate of urethral dilatation was much higher in the first year in both groups (2.6 ± 0.6 Vs 1.3 ± 0.4) in Group-2 and Group-1 respectively. In Group-3 [n-15] the frequency of urethral dilatation was much less (0.6 ± 0.4). Most of the patients in Group-1 [n-20] who had early primary realignment were managed with urethral dilatation on outpatient basis in the second year follow up and only few patients required internal urethrotomies at a frequency of 0.9 ± 0.2 . In Group-2 patients who had delayed realignment required internal urethrotomy at a frequency of 1.4 ± 0.6 in the second year and also underwent urethral dilatation on outpatient basis when possible. In Group-3 [n-15] no patient required internal urethrotomy, but few patients required urethral dilatation at a frequency of 1.2 ± 0.6 in second year. One patient in Group-1[n-20] and two patients in Group-2 [n-12] with who had delayed realignment underwent open anastomotic urethroplasty due to intractable urethral obliteration by the end of first year of follow up. Impotency was seen in 1 out of 21 (4.7%) in Group-1, 1 out of 12 (8.3%) in Group-2 and 2 out of 15 (13.3%) in group-3 patients. There was no incontinence cases reported in all the groups of patients.

Table-1: Clinical features and investigations of patients

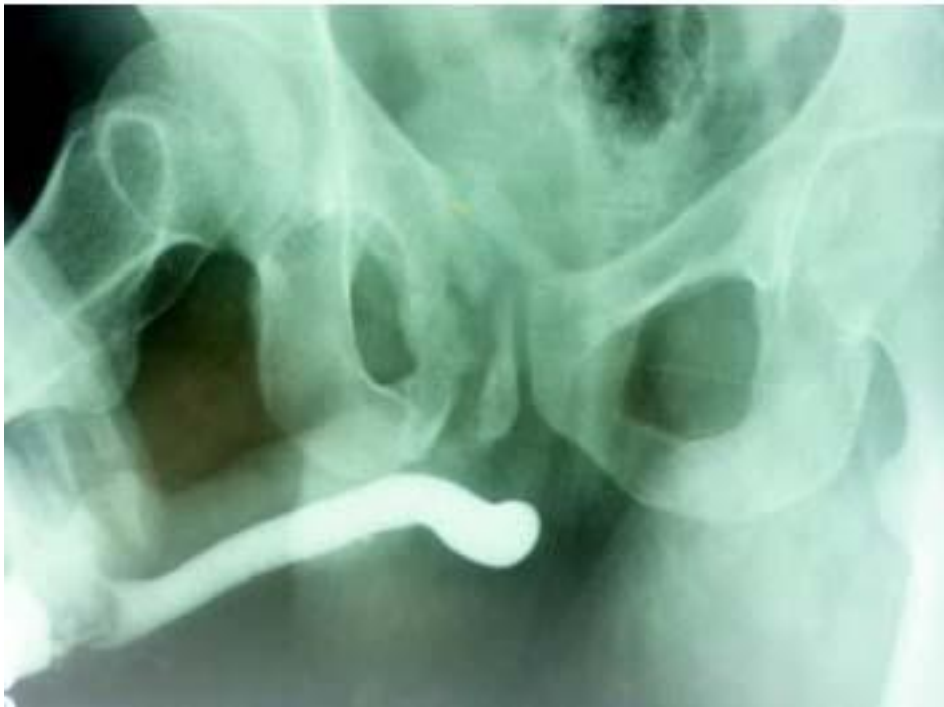Variables	Frequency	Percentage (%)
Age (n=48)		
< 35 Years	36	75.00
> 35 Years	12	25.00
Aetiology		
Road Traffic Accidents (RTA)	29	60.42
Fall from Height	12	25.00
Straddle Injury	7	14.58
Investigations		
X-Ray pelvis	48	100.00
Ultrasound	48	100.00
Retrograde Urethrogram	48	100.00
Micturating Cystourethrogram	12	25.00
CT Scan Abdomen	6	12.50

Table-2: Treatment and Complications

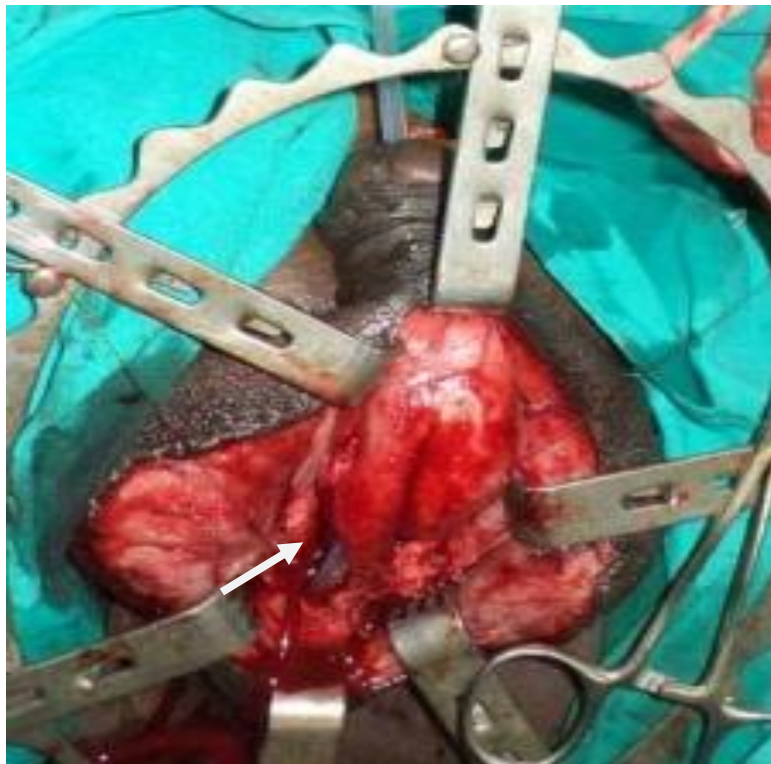Complications	Group-1	Group-2	Group-3
(%)	(n=20)	(n=12)	(n=15)
Stricture	90.9	100.00	100.00
Impotence	4.5	8.3	13.3
Incontinence	0	0	0

Figure 1:

RGU (Retrograde urethrogram) showing normal anterior urethra with cut off at proximal bulbar urethra with fracture pubic rami.

**Figure 2:**

Photograph showing cut ends of urethra before urethroplasty.



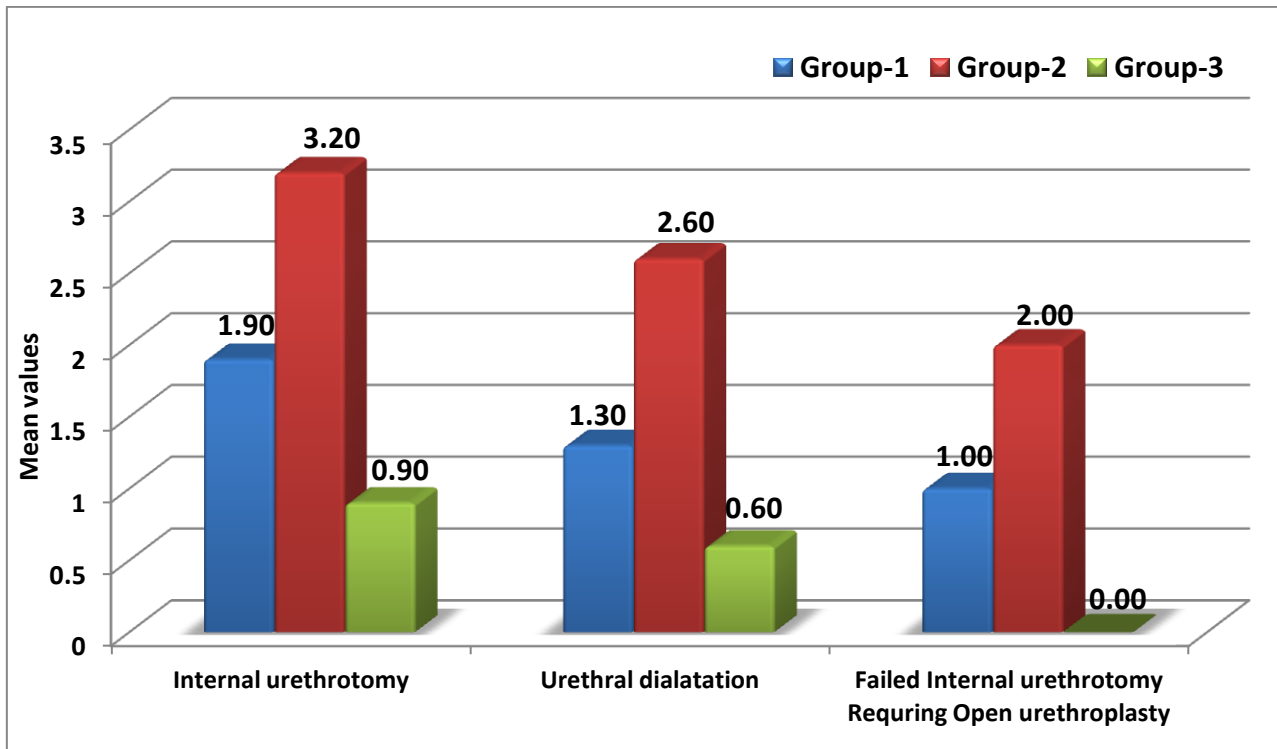


Figure 3: Comparison of mean values of management of complications in three groups.

DISCUSSION

Posterior urethral injuries are uncommon [13]. Most of these injuries are caused from pelvic fractures or straddle injuries. Type I and Type II constitute about 25% of cases, type III injuries account for another 25 % of cases and the remaining 50% are type IV and type V injuries [2]. The main goal of treatment of traumatic urethral injuries is to re-establish urethral continuity while minimizing the risk of complications such as incontinence, impotence and stricture formation [3]. The key to initial management also lies with proper diagnosis, accurate staging, and proper selection of an intervention [14]. Many reports have discussed the treatment modalities, but the ideal method of management remains controversial [7,10]. Once

the resuscitation and management of life threatening injuries are over, further step in the management of urethral injury is bladder drainage. Bladder drainage prevents further extravasations and also helps in monitoring of urine output. Definitive management options include early primary urethroplasty, early primary endoscopic realignment, delayed realignment and delayed urethroplasty [3]. Early primary urethroplasty procedure is technically challenging as it invariably requires lot of dissection at the site of trauma with high rates of post operative impotence (56%) and incontinence (21%), as shown in a large scale review of 871 patients by Koraitim MM *et al* [7]. By avoiding early intervention, postoperative impotence and incontinence decreased to 19% and 4% respectively [7]. Several studies have noted an associated risk of stricture formation as high as 100% after primary suprapubic urinary diversion,

requiring major reconstructive surgery [10,11]. Alternatively, endourologic procedures to establish urethral continuity have been developed and performed with reduced blood loss, shorter hospitalization, and potentially less severe stricture formation [5-6,8-9]. Since it was first described in 1934 by Ormond and Cothran, several techniques have been used to pass stent across the urethral injury [16]. The early attempts at early urethral realignment were done by retrograde catheterization of injured urethra through cystoscopy and involved varying levels of paravesical dissection. Sachse in 1974 attempted the first endourologic repair of posterior urethral disruption using direct vision urethrotomy in a delayed fashion [17]. Modern endoscopic instrumentation and minimal invasive techniques have facilitated a progression from early surgical repair to early endoscopic realignment of urethra. Endoscopic urethral realignment employs actual realignment with endoscopic guidance in an antegrade and retrograde fashion instead of a "railroading" technique [18]. Immediate primary realignment is typically performed in patients with minimal trauma and a stable hemodynamic status. Early primary realignment is typically performed within one week after injury when there will be less bleeding noted, because the hematoma around ruptured urethra becomes stable and the tissue around ruptured posterior urethra is still soft, without significant scar formation [3]. Immediate or early realignment can achieve good results with low complication rates [19-21]. Most recent series on primary endoscopic realignment are small, but showed favorable outcomes in the

rates of impotence (22%), incontinence (6%) and stricture formation (50%) [8]. Tazi *et al* noted that urethral strictures developed after primary endoscopic realignment is short and accessible to an endoscopic urethrotomy [22]. In our study, stricture formation rate in all three Groups was found in 47 patients (97.9%) who required additional procedure in the form of urethral dilatation, visual internal urethrotomy, and anastomotic urethroplasty. The stricture rate has been higher compared to other series probably because majority of our patients have been severely injured and have been completely disrupted urethra. The frequency of internal urethrotomies was higher in delayed realignment patients than in patients who underwent early primary endoscopic realignment and delayed open anastomotic urethroplasty in our study. Po Chin Chang *et al* [23] had similar results where twenty two patients were retrospectively analyzed in posterior urethral disruption injury. Moudouni *et al* have demonstrated that endoscopic realignment is associated with minimal morbidity and more over failure of endoscopic realignment has not compromised delayed formal urethral reconstruction [9]. It is generally believed that endourological procedures do not adversely affect erectile functions, since there is minimal manipulation of periprostatic tissue and no additional trauma to the cavernous nerve. Dhabawala *et al* [24] reported that impotency was caused by original injury itself and it is not due to the urethral repair. Some investigators reported no difference in both impotence and incontinence rates in patients

treated with primary realignment versus those with delayed urethroplasty [25,26].

CONCLUSION

Early primary endoscopic realignment seems to be first choice for treating traumatic urethral injuries. This new therapy has the advantages of shorter hospitalization, shorter operative time, less blood loss and less incidence of urethral stricture, impotence and urinary incontinence. In case of failure, endoscopic realignment does not compromise the result of secondary urethroplasty. Early endoscopic realignment in our experience reduces time to spontaneous voiding, decrease the need for major reconstructive surgery and long term suprapubic urinary diversion.

Source of Support: Nil.

Conflict of Interest: None declared.

REFERENCES

1. Palmer JK, Benson GS, Corriere JN. Diagnosis and initial management of urological injuries associated with 200 conservative pelvic fractures. *J Urol* 1983;130:712-4.
2. Koraitim MM, Mazouk ME, Atta MA, et al. Risk factors and mechanism of urethral injury in pelvic fractures. *Br J Urol* 1996; 71:876.
3. Koraitim MM. Pelvic fracture urethral injuries: the unresolved controversy. *J Urol* 1999;161:1433-41.
4. Morey AF, Mc Aninch JW. Reconstruction of posterior urethral disruption injuries: outcome analysis in 82 patients. *J Urol* 1997;157: 506-10.
5. White JL, Hirsch IH, Bagley DH. Endoscopic urethroplasty of posterior urethral avulsion. *Urology* 1994;44: 100-5.
6. Chuang CK, Lai MK, Chu SH. Optic internal urethrotomy under transrectal ultrasonographic guide and suprapubic fiberoptic aid. *J Urol* 1994;152:1435-7.
7. Koraitim MM. Pelvic fracture urethral injuries: evaluation of various methods of management. *J Urol* 1996;156:1288-91.
8. Jepson BR, Boullier JA, Moore RG, Parra RO. Traumatic posterior urethral injury and early primary endoscopic realignment: evaluation of long-term follow-up. *Urology* 1999;53:1205-10
9. Moudouni SM, Patard JJ, Manujnta A, Guiraud P, Lobel B, Guille F. Early endoscopic realignment of post-traumatic post urethral disruption. *Urology* 2001;57: 628-32.
10. Mouraviev VB, Coburn M, Santucci RA. The treatment of posterior urethral disruption associated with pelvic fractures: comparative experience of early realignment versus delayed urethroplasty. *J Urol* 2005;173:873-6.
11. Hadjizacharia P, Inaba K, Teixeira GR, Kokorowski P, Memetriades D, Best C. Evaluation of immediate endoscopic realignment as a treatment mortality for traumatic urethral injuries. *J Trauma* 2008;64:1443-8.

12. Moore EE, Cogbill th, Malagoni MA, *et al.* Organ injury scaling. *Surg Clin North Am.* 1995;75:293-303.
13. Andrich DE, Greenwell TJ, Mundy AR. Treatment of pelvic fracture-related urethral trauma: a survey of current practice in the UK. *BJU Int* 2005;96:127-30.
14. Brandes S. Initial management of anterior and posterior urethral injury. *Urol Clin North Am* 2006;33:87-95.
15. Kielb SJ, Voeltz ZL, Wolf S . Evaluation and management of traumatic posterior urethral disruption with flexible cystourethroscopy. *J Trauma* 2001;50:36-40.
16. Wilkinson FO. Rupture of the posterior urethra with a reveiw of twelve cases. *Lancet* 1961;1(7187): 1125-9.
17. Sache H. Treatment of urethral stricture: Transurethral slit in view using sharp section. *Fortschr Med* 1974; 92: 12-15.
18. Ikuerowo SO, Omisanjio OA, Esho JO, Balogun BO, Akinola RA. Combined antegrade and retrograde endoscopic realignment of traumatic urethral disruption. *Internet J Urol* 2010;7:1.
19. Gheiler E, Frontera J. Immediate primary realignment of prostomembranous urethral disruption using endourologic techniques. *Urology* 1997; 49: 596-9.
20. Ku J, Kim M, Jeon Y, Lee N, Park Y. Management of bulbous urethral disruption by blunt external trauma: The sooner, the better? *Urology* 2002;60:579-83.
21. Yasuda K, Yamananishi T, Isaka S, Okano T, Masai M, *et al.* Endoscopic re-establishment of membranous urethral disruption. *J Urol* 1991; 145: 977-9.
22. Tazi H, Ouali M, Lrhorfi MH, Moudouni S, Tazi K, *et al.* Endoscopic realignment for post-traumatic rupture of posterior urethra. *Prog Urol* 2003; 13: 1345-50.
23. Chang PC, Hsu YC, Shee JJ, Huang ST, Huang HC, *et al.* Early endoscopic primary realignment decreases stricture formation and reduces medical costs in traumatic complete posterior urethral disruption in a 2- year follow-up. *Chang Gung Med J* 2011; 34(2):179-85.
24. Dhabuwala CB, Hamid S, Katsikas DM, Pierce JM Jr. Impotence following delayed repair of prostatomembranous urethral disruption. *J Urol* 1990;144(3): 677-8.
25. Follis H, Kock M, Medougal W. Immediate management of prostamembranous urethral disruptions. *J Urol* 1992; 92: 12-5.
26. Husmann DA, Wilson WL, Boone TB, Allen TD. Protatomembranous urethral disruption: Management by suprapubic cystostomy and delayed urethroplasty. *J Urol* 1990; 144: 76-8.