



IGM Publication

Journal Of Medical Science And Clinical Research

An Official Publication Of IGM Publication

Gingival Aggressiveness during Pregnancy

Authors

Dr Arvind Garg¹, Dr Asmita Arora², Dr Shweta Aggarwal³, Dr Arun Garg⁴**Dr Viniti Goel⁵**

¹Professor & Head, Department of Periodontics, JCD Dental College & Hospital, Sirsa, Haryana, India. 125055. Email: *docarvindgarg@gmail.com*

²Senior Lecturer, Department of Periodontics, JCD Dental College & Hospital, Sirsa, Haryana, India. 125055. Email: *asmita.sethi@gmail.com*

³Reader, Department of Periodontics, JCD Dental College & Hospital, Sirsa, Haryana, India. 125055. Email: *dr_shwetaagarwal@hotmail.com*

⁴Reader, Department of Periodontics, JCD Dental College & Hospital, Sirsa, Haryana, India. 125055. Email: *doc7602@gmail.com*

⁵Reader, Department of Periodontics, Luxmi Bai Dental College and hospital, Patiala, Punjab, India. Email: *vinitigoel@hotmail.com*

Corresponding Author

Dr Arvind Garg

Professor & Head

Department of Periodontics, JCD Dental College & Hospital, Sirsa, Haryana, India. 125055.

Email: *docarvindgarg@gmail.com*

ABSTRACT

Increased circulatory hormones especially progesterone during pregnancy leads to increase in severity of gingivitis. A fibro-granulomatous lesion can sometimes develop during pregnancy and is referred to as pregnancy granuloma. Pregnancy granuloma or pregnancy tumor occurs in 0.2% to 9.6% of pregnancies. They are clinically and histologically indistinguishable from pyogenic granuloma occurring in non-pregnant women or men, appearing most commonly in second or third month of pregnancy. The authors here report a case series of pregnancy tumors depicting the hormonal influence as an important etiological factor. The hormonal changes occurring during pregnancy may be associated with generalized or localized gingival enlargement and the presence of local factors such as microbial plaque may accentuate the gingival response. Rarely the enlargement bleeds spontaneously and can cause serious complications during pregnancy.

Key words: *pyogenic granuloma, pregnancy tumor, granuloma gravidarum*

INTRODUCTION

The term pyogenic granuloma was proposed by Hartzell [1] in 1904, although it is a misnomer since the condition is not associated with pus and does not represent a true granuloma. It arises in response to various stimuli such as chronic low-grade irritation, traumatic injury, hormonal factors or certain kind of drugs. Females are more commonly affected probably due to vascular effects of hormones that occur during puberty, pregnancy and menopause. The appearance ranges from red/pink to purple and can be smooth or lobulated. Older lesions begin to change into pink colour. Pyogenic granuloma can be sessile or pedunculated mass with a broad base. Its size ranges from a few millimeters to centimeters. It can grow rapidly and will often bleed profusely with little or no trauma. The diagnosis can be confirmed by preparing histological sections of the biopsy specimens. The treatment that has been widely used and often recommended is conservative excision of the lesion, where the recurrence rates may vary from 0 to 16% [2].

CASE REPORTS

A record of nine female patients was observed who had reported with the following sign and symptoms *i.e.* Swelling in the oral cavity accompanied with pain, difficulty during mastication and tendency to bleed on touch. Data regarding their age, sex, occupation, address, site of lesion, predisposing factors, clinical characteristics and treatment was duly recorded. On clinical examination, the size of the lesion

varied from 0.5cm in diameter up to 2.5cm (Fig.1).

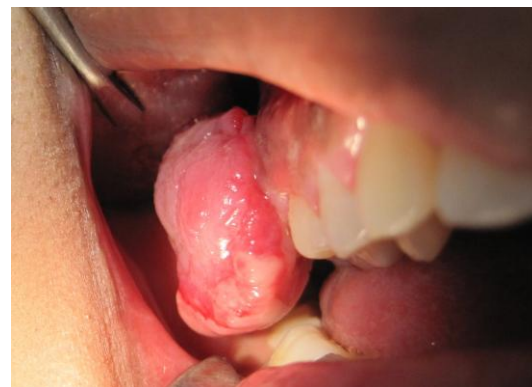

Figure 1. Buccal view of Pyogenic Granuloma.

In all the subjects, the lesion was initially of a pin head size then gradually increased to the present size. Local factors (plaque and calculus) were present around the teeth corresponding to the lesion in all the subjects. Apart from a combination of etiologies, like chronic low-grade irritation from local factors, traumatic injury, we have found in our subjects a common factor, that is, five of the total subjects were in second and third trimester of pregnancy with no systemic health problems, indicating hormonal changes as an important etiological factor.

The treatment plan consisted of thorough oral prophylaxis comprising scaling and root planing to remove the local factors, followed by surgical excision using simple gingivectomy (Fig. 2 & Fig.3) and histopathological examination of the excised mass. Surgical excision of the lesion was curative and no evidence of recurrence of swelling was observed (Fig. 4).

The histopathological examination revealed a hyperplastic stratified squamous epithelium with an underlying fibrovascular stroma that shows a large number of aggregation of vascular channels lined with a single layer of endothelial cells and

areas of extravasated blood. A mixed acute and chronic inflammatory cell infiltrate was noted. There were no signs of atypia. The microscopic diagnosis was pyogenic granuloma.

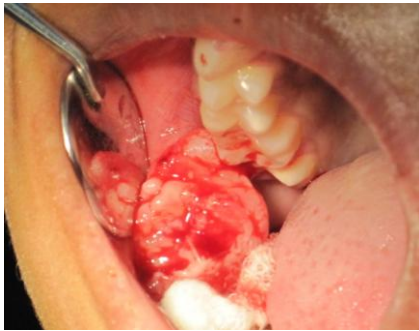


Figure 2. Excising Granuloma.

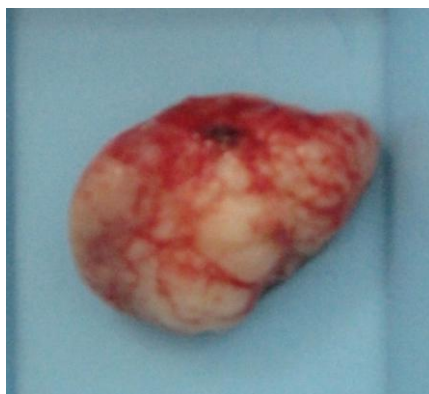

Figure 3. Excised Granuloma.

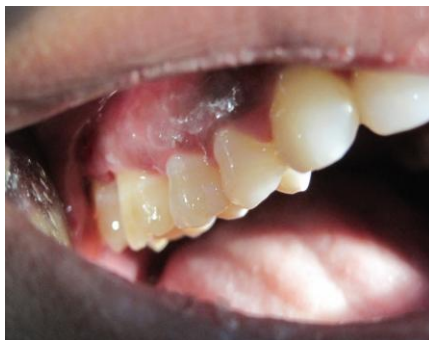

Figure 4. Post Operative Healing.

DISCUSSION

Pyogenic granuloma (PG) in a non-neoplastic inflammatory hyperplasia of skin or mucous membrane strongly associated to the chronic local irritation and trauma. In the oral cavity, the lesions are more common in the marginal gingival of

subjects with poor oral hygiene, growing in response to the presence of dental plaque [3].

PG of the gingiva develops in 0.2 to 9.6 % of pregnancies, hence the terms “pregnancy tumor” and “granuloma gravidarum” are often used. Other conditions that can be included in the differential diagnosis of a gingival mass include peripheral fibroma, peripheral giant cell granuloma, and peripheral ossifying fibroma.

The hormonal imbalance coincident with pregnancy heightens the organism's response to irritation [4]; however, bacterial plaque and gingival inflammation are necessary for subclinical hormone alterations leading to gingivitis. Generally, it appears in the 2nd - 3rd trimester of pregnancy, with a tendency to bleed and a possible interference with mastication. When tendency to bleed spontaneously is present, it can pose serious complications to the patient during pregnancy and treatment, as shown in Figure 1. Severe bleeding from a pregnancy tumor has been previously reported [5]. In the present case scaling and root planing was done followed by surgical excision. Within a month after treatment, patient reported to prevent any complications as the patient was in second trimester of pregnancy.

During pregnancy there is an increase in levels of both progesterone and estrogen, which, by the end of third trimester, reach levels 10 and 30 times the levels during menstrual cycle, respectively [6]. Estrogen enhances vascular endothelial growth factor (VEGF) production in macrophages, an effect that is antagonized by androgens and which may be related to the development of pregnancy

tumor. These regulatory effects of sex steroids may be manipulated as therapeutic or prophylactic measures in pregnancy tumor [7]. Progesterone functions as an immunosuppressant in the gingival tissues of pregnant women, preventing a rapid acute inflammatory reaction against plaque, but allowing an increased chronic tissue reaction, resulting clinically in an exaggerated appearance of inflammation [8]. Angiostatin was expressed significantly less in PG than in healthy gingiva and periodontally involved gingiva. The molecular mechanism for regression of pregnancy tumor after parturition remains unclear. It has been proposed that, in the absence of VEGF, Angiopoietin-2 (Ang-2) causes blood vessels to regress. The protein level of Ang-2 was highest in the pregnancy tumors, followed by those after parturition and normal gingiva. The amount of VEGF was high in the granuloma in pregnancy and almost undetectable after parturition.

Kornman and Loesche reported that the subgingival flora changes to a more anaerobic flora as pregnancy progresses. *P. intermedia* appear to be the only microorganism that increases significantly during pregnancy. This increase appears to be associated with elevations in systemic levels of estradiol and progesterone and to coincide with the peak in gingival bleeding. It is also suggested that during pregnancy a depression of the maternal T-lymphocyte response may be a factor in the altered tissue response to plaque [9].

In pregnancy, the emphasis should be on preventing gingival disease before it occurs and treating existing gingival disease before it

worsens. All patients should be seen as early as possible in pregnancy. Those without gingival disease should be instructed in plaque control procedures & patients with gingival disease should be treated promptly, before the effects of pregnancy on gingiva become apparent. Every pregnant patient should be scheduled for periodic dental visits. At these appointments, the importance of prevention should be stressed to avoid serious periodontal problems during pregnancy. As in the present case series, if proper oral hygiene had been instilled at the right time, the severity of the disease would have been less pronounced.

REFERENCES

1. Hartzell MB. *Granuloma pyogenicum*: J Cutan Dis, 22:520, 1904.
2. Zain R, Khoo S, Yeo J. Oral pyogenic granuloma clinical analysis of 304 cases. Singapore Dent J, 1995; 20(1):8-10.
3. Vilmann A, Vilmann P, Villman H. Pyogenic Granuloma: evaluation of oral conditions. Br J Oral Maxillofac Surg, 1986; 24(5):376-82.
4. Eversole LR (2002) Clinical outline of oral pathology: diagnosis and treatment, 3rd edition, BC Decker, Hamilton, 113-114.
5. Wang PH, Chao HT, Lee WL, Yuan CC, Ng HT. Severe bleeding from a pregnancy tumor. A case report. J Reprod Med. 1997; 42(6):359-62.
6. Amar S, Chung KM: Influence of hormonal variation on the periodontium in women. Periodontol 2000, 1994; 6:79.

7. Kanda N, Watanabe S. Regulatory roles of sex hormones in cutaneous biology and immunology. *J Dermatol Sci.* 2005;38:1–7.
8. Ojanotko-Harri AO, Harri MOP, Hurrita HP, et al: Altered tissue metabolism of progesterone in pregnancy gingivitis and granuloma. *J Clin Periodontol* 1991;18:262.
9. Klokkevold PR, Brian LM, Carranza FA: Influence of systemic disease and disorders on the periodontium. In: Newman MG, Takei HH, Carranza FA (eds): *Carranza's Clinical Periodontology*, 9th ed. Philadelphia: Saunders; 2003.