



Tuberculosis Of The Gastrointestinal Tract- The Great Mimic A Rare Case Report

Authors

Balaji Purushotham¹, Sivakumar Madhu²

¹Professor, Minimal Access Surgery, Minimal Access Surgery Unit, Madras Medical College, Chennai

²Senior Resident & Fellow Scholar, Minimal Access Surgery, Department of Minimal Access & GI Surgery, GHC, Chennai

Correspondence Author

Dr. Sivakumar Madhu

Senior Resident & Fellow Scholar, Minimal Access Surgery,
Department of Minimal Access & GI surgery, GHC, Chennai

Email: sivak.madhu@gmail.com

ABSTRACT

Back ground: Segmental colonic tuberculosis being a rarity in sigmoid colon with limited no of cases reported so far.

Case report: A 68yrs old male presented with lower abdominal pain of 1 month duration, associated with dysuria/difficulty in micturition. There was history of loss of appetite & weight with constipation present on & off. Investigation revealed a stricture involving long segment of sigmoid colon and adherent to posterior wall of the bladder on the left side. Possibility of malignant/inflammatory etiology. Cystoscopy guided biopsy of bladder lesion showed granulomatous lesion. Diagnostic laparoscopy done and proceeded with Laparotomy/Resection of stricture segment of sigmoid colon and primary colocolic anastomosis. Histopathology report confirmed tuberculosis colitis. Patient was started on antituberculous (ATT) medication. Patient is on regular follow up.

Conclusion: Tuberculosis is known to involve any segment of gastrointestinal tract. While tuberculosis of the small bowel is common, isolated primary tuberculosis of the large bowel is quite uncommon. Tuberculosis of colon forms only 3 to 4% of intestinal tuberculosis. Tuberculosis of the colon tends to be segmental and usually obstructive symptoms dominate. However the diagnostic challenge is very high when isolated colonic segments are involved with tuberculosis.

Keywords: Tuberculosis (TB), Gastrointestinal (GI) tract, Antituberculous drug (ATT).

INTRODUCTION

Tuberculosis (TB) infection is still common and remains an important cause of morbidity and mortality, particularly in developing nations^{[1],[2]}. The gastrointestinal (GI) tract is the sixth commonest extra pulmonary site to be affected after lymphatic, genitourinary, bones and joints, miliary and meningeal involvement^[1]. Manifestations can be non-specific and mimic many conditions, including malignancies.

CASE REPORT

A 68yrs old male, manual labourer by occupation presents with lower abdominal pain – 1 month, Associated with H/O dysuria & difficulty in micturition. Associated with constipation on & off. H/O LOA / LOW +. No other specific complaints. No other co-morbidities present.

ON EXAMINATION

General condition fair. The patient was moderately built and nourished. Examination of abdomen: Flat, umbilicus normal in position, all quadrants moves equally with respiration, No obvious mass palpable per abdomen, No organomegaly / free fluid. Per rectal examination- normal study. Other system examination – normal.

All basic blood investigations were found to be within normal limit. Urine cytology-f/s/o acute infective pathology, no e/o malignant cells seen. USG ABDOMEN: hypo echoic mass lesion with echogenic foci seen in the urinary bladder wall measures 2.8 x 1.9 cm.? Mass urinary bladder.

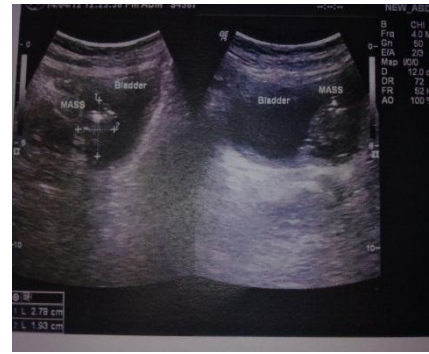

Figure 1: USG Abdomen showing bladder wall lesion

BARIUM ENEMA: Segmental narrowing of sigmoid colon with abrupt transition zone. Features more likely of growth than inflammation.? Diverticulum / polyp in descending colon / sigmoid junction.

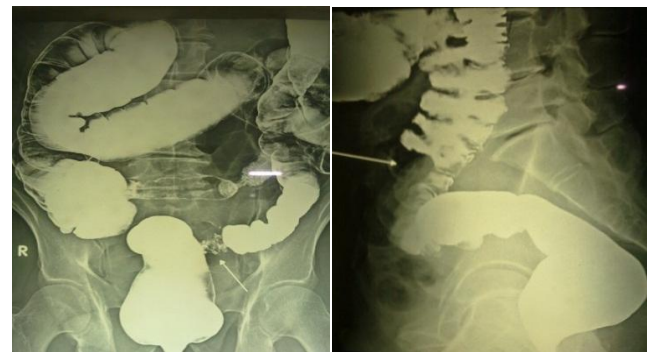


Figure 2: Barium Study showing Sigmoid Stricture

CONTRAST CT ABDOMEN: There is long segment circumferential wall thickening involving sigmoid colon. Small nodular heterogeneously enhancing soft tissue lesion involving left posterolateral wall of urinary bladder.

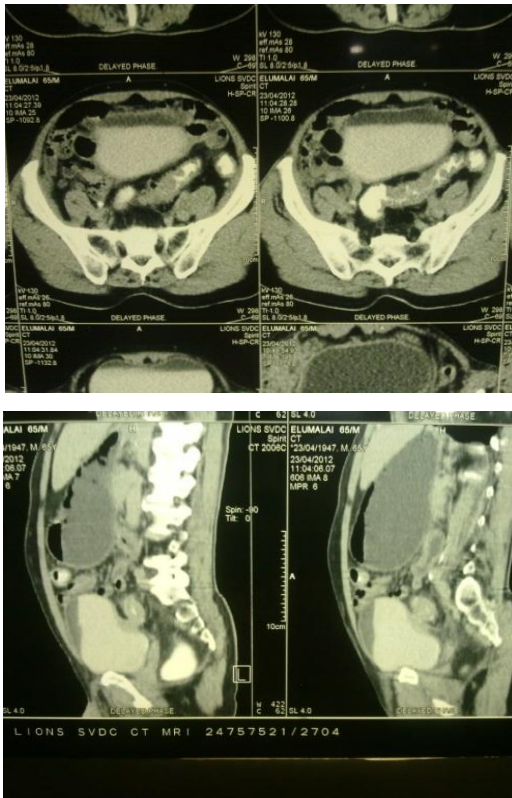


Figure 3: Contrast CT showing Segmental thickening of the Sigmoid tethering to the bladder wall

CEA- 2.3 ng/ml. COLONOSCOPY: scope passed 20cms from anal verge & not beyond that due to luminal narrowing. Imp:? Rectal stricture. Biopsy could not be attempted. DIAGNOSTIC CYSTOSCOPY: Papillary lesion noted in left lateral wall of bladder, distant from ureteric orifice, with bulge noted. The same was biopsied and sent for HPE. Rest of bladder mucosa normal. HPE-Cystitis probably tuberculous origin. No evidence of active foci of tuberculosis elsewhere. Diagnostic laparoscopy done, shows stricturous growth involving segment of sigmoid colon found adherent to the posterior & left lateral wall of bladder. Hence, proceeded with laparotomy. A firm mass of size 8*6cm present in sigmoid colon found adherent to the left posterolateral wall of bladder. On table frozen section done, shows granulomatous colitis. In view of benign

pathology resection of stricture segment of sigmoid colon with cuff of bladder mucosa with primary colocolic anastomosis with two layer closure of bladder wall done. Excised specimen shows, Stricture of length 8cm involving sigmoid colon.

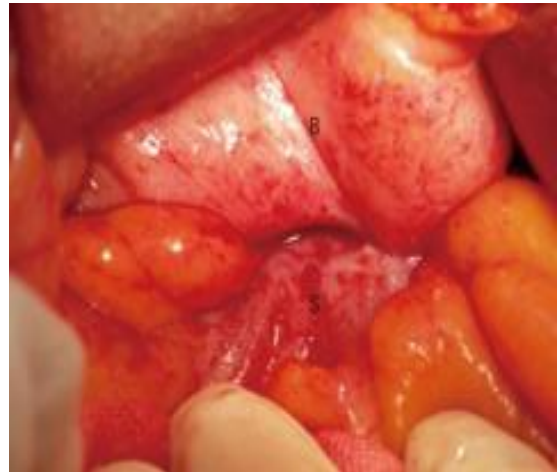

Figure 4: Sigmoid Adherent to the bladder wall

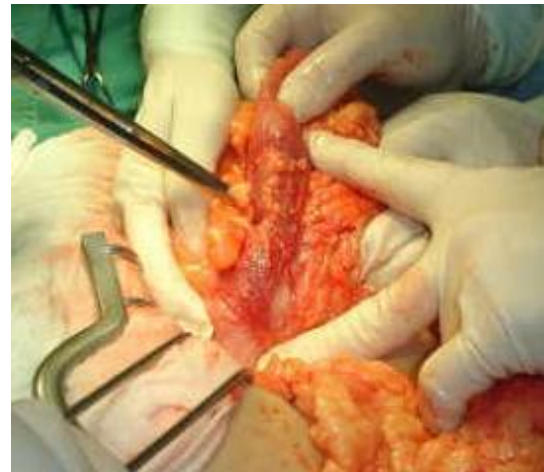

Figure 5: Sigmoid colon stricture site

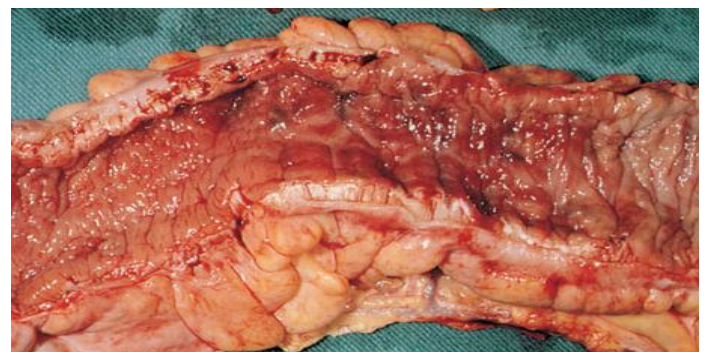


Figure 6: Cut section of the specimen showing the stricture segment

Histopathology report

- The colonic mucosa showed mild increase in number of layers of lining epithelium with edema, pockets of inflammatory cells composed of neutrophils, dispersed lymphocytes, sheets of foamy macrophages, *epitheloid and Langhan's type giant cell granulomata with caseation necrosis*.
- Impression: Tuberculous colitis.

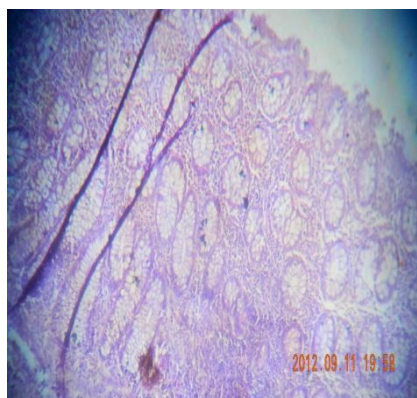
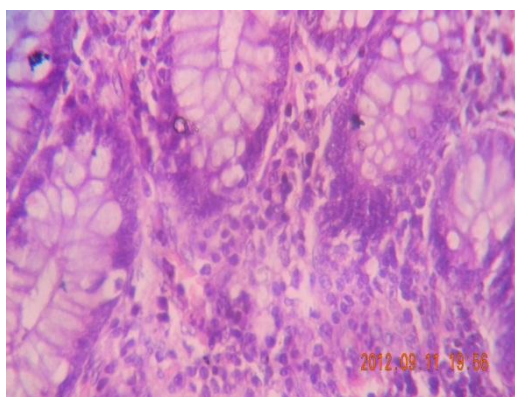


Figure 7: HPE – Giant cell granuloma with Caseation Necrosis

Postop period was uneventful. The patient was started on oral feeds from POD # 3 & increased as tolerated. Suture removal was done on POD # 10. The patient was started on Cat I ATT. Postop urologist review obtained & IVP done: normal study. The patient was on regular follow up & doing well.

DISCUSSION

Tuberculosis (TB) infection is still common and remains an important cause of morbidity and mortality, particularly in developing nations^{[2],[3]}. The gastrointestinal (GI) tract is the sixth commonest extra pulmonary site to be affected after

- lymphatic,
- genitourinary,
- bones and joints,
- miliary and meningeal involvement^{[2][5]}.

Manifestations can be non-specific and mimic many conditions, including malignancies. Intestinal tuberculosis is a diagnostic challenge, especially in the absence of active pulmonary infection. It may mimic many other abdominal diseases.

Tuberculosis of colon forms only 3 to 4% of intestinal tuberculosis^[1].

Tuberculosis of the ileocaecal region is a common entity. The apparent affinity of the tubercle bacillus for lymphoid tissue and areas of physiologic stasis facilitating prolong contact between the bacilli and the mucosa may be the reason for ileum and caecum being the most common sites of the disease. Tuberculosis of the colon tends to be segmental and obstructive symptoms dominate.

The postulated mechanisms^{:[2][3]}

- I. Hematogenous spread from the primary lung focus in childhood, with later reactivation
- II. Ingestion of bacilli in sputum from active pulmonary focus

- III. Direct spread from adjacent organs and
- IV. Through lymphatic channels from infected nodes.

Segmental or isolated colonic tuberculosis refers to involvement of the colon without ileocaecal region.

It commonly involves the sigmoid, ascending and transverse colon. Multifocal involvement is seen in one third (28 to 44%) of patients with colonic tuberculosis. Pain is the predominant symptom in 78-90% of patients and hematochezia occurs in less than one third. The bleeding is frequently minor and massive bleeding is less common. Other manifestations include fever, anorexia, weight loss and change in bowel habits.

GI TB manifests as: the ulcerative form (60%), hypertrophic form (10%) and mass-like lesions (ulcerohypertrophic, 30%) that mimic malignancies^[4].

Ulcerative lesions give rise to fibrous strictures. Cicatricial healing of these circumferential 'girdle ulcers' results in strictures.

Occlusive arterial changes may produce ischaemia and contribute to the development of strictures.

The patient complains of abdominal pain, diarrhoea and intestinal colic, and later on presents with signs of intestinal obstruction.

Paustian stated that one or more of the following four criteria must be fulfilled to diagnose abdominal tuberculosis:^{[2][5]}

- I. Histological evidence of tubercles with caseation necrosis;

- II. a good typical gross description of operative findings with biopsy of mesenteric nodes showing histologic evidence of tuberculosis;
- III. animal inoculation or culture of suspected tissue resulting in growth of *M. tuberculosis*; and
- IV. histological demonstration of acid fast bacilli in a lesion.

The diagnosis of isolated colonic tuberculosis, quite difficult since there are no specific clinical presentations. CT scan and Barium enema: delineates the bowel wall thickening & strictures. Colonoscopic biopsy is a useful diagnostic modality in Colonic tuberculosis.

Newer methods:

- Polymerase Chain Reaction (PCR) may detect mycobacterial DNA in endoscopic biopsy specimens.
- Interferon—gamma release assays (IGRAs), such a Quanti FERON-TB Gold, are now used widely to screen for latent TB.

TREATMENT

Conservative: ATT (cat I, based on Rifampicin, Isoniazid, Pyrazinamide & Ethambutol)

Surgery: Segmental Resection is the treatment of choice (since hyperplastic lesions rarely respond to chemotherapy)^[1].

For isolated tuberculosis of the colon, local colonic resection is adequate, followed by ATT^[5].

CONCLUSION

Primary segmental colonic tuberculosis is a rare condition and poses great difficulty in diagnosis.

High index of suspicion, supported by radiological and colonoscopy may lead to a diagnosis.

However, definite diagnosis is made by laparotomy followed by tissue biopsy.

The standard treatment of choice is Segmental resection with colocolic anastomosis followed by antitubercular therapy (ATT).

REFERENCES

1. Primary Segmental Colonic Tuberculosis: A Case Report M Haque1 et al,The Journal of Teachers Association RMC, Rajshahi.
2. Gastrointestinal tuberculosis : Chong V H, Lim K S Singapore Med Pictorial Essay J 2009
3. Abdominal tuberculosis : M.P. Sharma & Vikram Bhatia,Department of Gastroenterology, All India Institute of Medical Sciences, New Delhi, India.
4. Tuberculosis masquerading as malignancy: a multimodality approach to the correct diagnosis – a case report Shalini Amukotuwa et al.
5. Gastrointestinal: Tuberculosis of the sigmoid colon—a cautionary tale journal of gastroenterology and tuberculosis.