



Case Report

Pathogenesis of EMA negative PR negative Microcystic Meningioma: A Case Report

Authors

**Supriya Mehrotra¹, Bandana Mehrotra², Sanjay Mehrotra³,
Ashok Kumar Kapoor⁴, Neha Gupta⁵, Hari Shyam⁶**

^{1,2,4,5}Pathologist, Department of Pathology, RML Mehrotra Pathology Pvt. Ltd, Nirala Nagar, Lucknow, Uttar Pradesh, India

³Director, RML Mehrotra Pathology Pvt. Ltd, Nirala Nagar, Lucknow, Uttar Pradesh, India

⁶Technologist, Department of Pathology, RML Mehrotra Pathology Pvt. Ltd, Nirala Nagar, Lucknow, Uttar Pradesh, India

Corresponding Author

Dr. Ashok Kumar Kapoor

RML Mehrotra Pathology Pvt. Ltd. B-171, Nirala Nagar, Lucknow- 226020, Uttar Pradesh, India

Abstract

A patient, aged 35 years female complained of headache. CT examination revealed a non-succable tumor at anterolateral aspect of dura. Tumor extended from the right cervicomedullary junction upto C7 level. Tumor was excised and multiple soft tissue pieces, together measuring 1.5×1×1 cm were collected. All the pieces were sectioned. Tumor had a sieve-like and cyst-like appearance. Section showed a circumscribed globular tumor which consisted of proliferated bland spindle cells. Tumor had an edematous stroma and presented a microcystic appearance. The cells had elongated ovoid nuclei and mild eosinophilic cytoplasm. Several thin-walled vascular spaces were also seen in the tumor. Strong positive reaction was obtained with an anti-S100 antibody, suggesting a neural origin of tumor cells. Further, anti-Ki 67 antibody gave mild reaction (Ki67 index was 12%) suggesting benign neoplasm. Anti-CD 34 and anti-D2.40 antibodies gave positive reactions (2+) with small blood vessels of the tumor.

Keywords: Benign cystic neoplasm with similar behavior among various subtypes.

Introduction

During previous 5 years (from 1st Jan 2018 to 31st December 2023), we had 3 cases of microcystic meningioma. Total number of cases of meningioma during this period were forty-two. Other subtypes of meningiomas were as follows. Twenty patients had meningothelial meningioma. Thirteen other cases had Psammomatous meningioma. Two patients each had fibroblastic meningioma, angiomatous meningioma and anaplastic meningioma. Age of our meningioma patients (n=42) ranged from 16 to 77 (median 38

years). Male/female ratio was 1.1:1.0). Exact pathogenesis of microcystic change in meningioma is not known. Tumor cells may secrete myxoid fluid which may accumulate in dilated stromal extracellular spaces. Another possibility may be cytolysis and hydropic degeneration leading to microcyst formation^[1]. Earlier, WHO classified brain tumors in the year 1993. Accordingly, 1.6% of tumors were microcystic meningiomas^[2]. Herewith, we report a case of microcystic meningioma.

Case Report

Present case had a tumor that extended from right corticomedullary junction upto C7 vertebra. Patient had a globular tumor, measuring 1.5×1×1 cm. Hematoxylin eosin sections showed tumor tissue. Tumor comprised of spindle cells. Tumor cells closely resembled with normal cells, suggesting it to be a benign neoplasm. Moreover, tumor showed multiple micro- and macrocysts of variable sizes giving it a sponge-like appearance.

Cysts were filled with myxoid substance. The wall of cysts contained fibrous tissue (figure 1). IHC revealed positivity of tumor cells with anti CD34 and anti-CD2.40 antibodies, (figure 1). Strong (3+) positivity of tumor cells was seen with anti-S100 antibody. Mild positive reaction was seen with anti-Ki67 Antibody (Ki-67 index was 12%), suggesting benign behavior of tumor cells (figure 2).

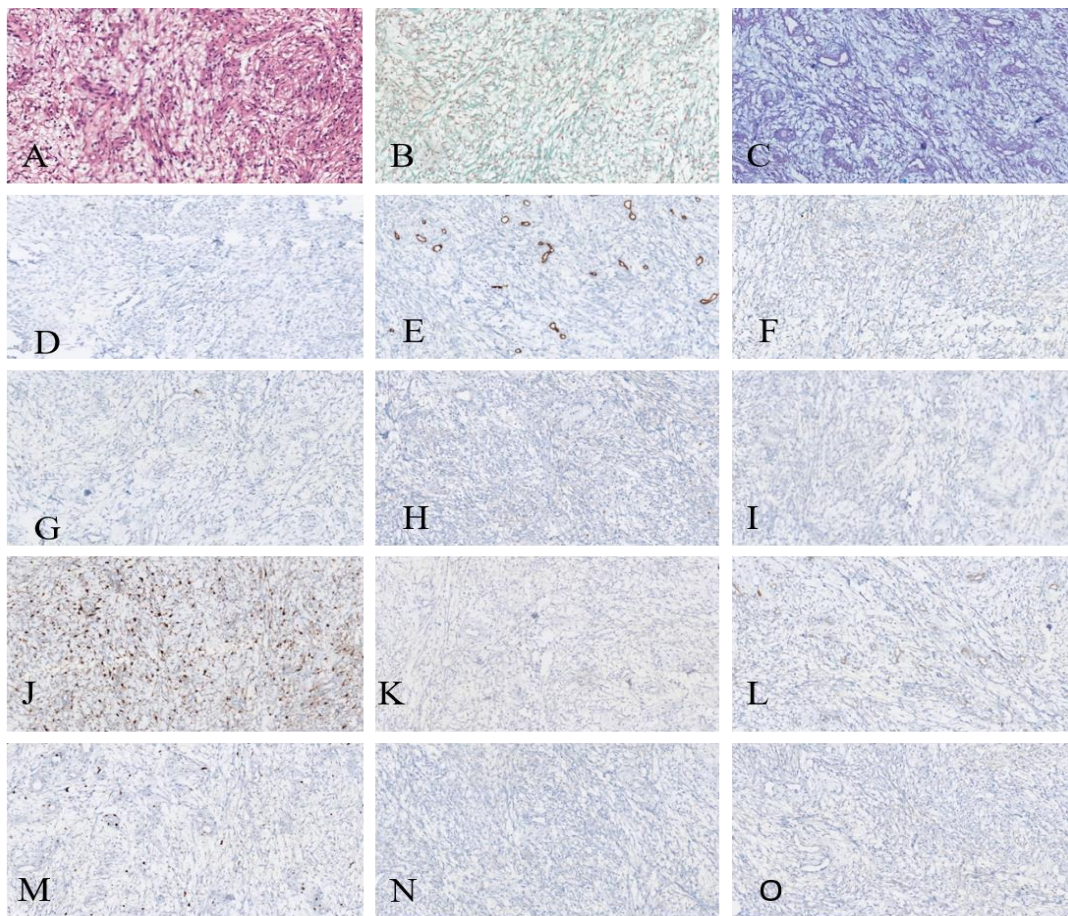


Figure 1: (A) Photomicrograph shows proliferated bland spindle cells in an edematous stroma with micro- and macrocysts of various sizes (HE×400). (B) Photomicrograph shows tumor cells, collagen fibers and cysts(MT×400). (C) Photomicrograph shows staining of tumor cells by PAS-alcian(×400). (D)IHC shows staining of tumor cells using anti-CD56 antibody. Negative reaction was seen (×400). (E) Photomicrograph shows positive (2+) staining of small vessels of tumor cells using anti-CD34 antibody (×400). (F) Anti-CD2.40 gave mild positive reaction with tumor cells (×400). (G) Anti-SOX10 antibody did not react with tumor cells (×400). (H) Anti-Calretinin antibody did not react with tumor cells. (I) Anti-GFAP antibody also did not react with tumor cells. (J)Anti-S100 antibody gave strong positive reaction (3+) with tumor cells (×400). (K) Anti-STAT6 antibody gave negative reaction with tumor cells (×400). (L) Anti-SSTR 2 gave negative reaction with tumor cells (×400). (M) Anti-Ki 67 antibody gave mild positive reaction (Ki 67 index was 12%). (N) Anti-EMA antibody gave negative reaction with tumor cells. (O) Anti-PR antibody also gave negative reaction with tumor cells.

Discussion

Microcystic meningioma is a rare histological subtype of meningioma. It was first described by Masson as being warm and damp^[3]. It is a myxoid tumor^[2]. IHC using anti-CD 34 antibody revealed poor vascularity of the tumor^[4]. Several theories have been proposed to explain microcystic change, e.g. degeneration^[2], proteinous fluidtransudation^[5], vascular permeability changes^[6] and subarachnoid structure^[7]. Further, CT appearance of microcystic meningioma may be similar to cerebral edema^[8]. In addition, biological behavior of microcystic meningioma may be benign, similar to other subtypes of meningiomas. Furthermore, meningiomas with severe positron emission tomography might express increased levels of endothelial permeability factor^[9]. Additionally, meningiomas of the frontal lobe tend to be bigger in size when compared with those located at occipitoparietallobe^[9]. Moreover, radical resection of microcystic meningioma appeared essential for prevention of recurrence^[4]. Strong correlation was found between Ki67 labeling index and progesterone expression^[10]. Furthermore, electron microscopic studies suggested the role of hydropic degeneration leading to cytolysis in development of microcystic meningioma^[11]. In another study, 4 of 6 cases of microcystic meningioma had complex interdigitations of cytoplasmic processes and desmosomes as seen in arachnoid cap cells. On the contrary, 2 other cases formed stellate cells, common with trabecular arachnoid cells^[11]. Morphological classification may not accurately predict the outcome of microcystic meningioma. Five DNA methylation groups have been reported; three among them suggest benign neoplasm (MC ben 1 MC ben 2 and MC ben 3). Another tumor with int A and int B may have a malignant potential while another tumor with MC mal might have a malignant outcome.

Conclusion

A 35-year-old female patient complained of headache. She was operated and a tumor measuring 1.5×1×1cm was excised. IHC revealed mild positive reaction of tumor cells with anti-CD 34 and anti-D2.40 antibodies. Moreover, strong positive (3+) reaction was obtained with anti-S100 antibody, suggesting neural origin of the tumor. In addition, mild positive reaction was obtained with anti-Ki 67 antibody, suggesting a benign neoplasm. Histopathologically, she was diagnosed having a tumor that arose from arachnoid villus. Tumor was finally diagnosed as microcystic meningioma.

References

1. Cuccurullo L, Luongo M, Accardo M. Ultrastructural profile of microcystic meningioma. *Pathologica* 2009;101(3):115-118.
2. Kleihues P, Burger PC, Scheithauer BW: The new classification of brain tumors, *Brain Path* 1993;3:255-268.
3. Michaud J, Gagne F. Microcystic meningioma - Clinicopathological report of eight cases. *Arch Pathol Lab Med* 1983;107:75-80.
4. Kim SH, Kim DG, Kim C-Y, Choe G, Kim C-Y, Choe G et al. Microcystic meningioma: The characteristic neuroradiological findings. *J Korean Neurosurg Soc* 2003; 34:401-406.
5. Harrison JD, Rose PE. Myxoid meningioma: histochemistry and electron microscopy, *ActaNeuropathol (Br)* 1985;31:179-185.
6. Schober R, Himuro H, Wechsler W. Cystic changes and vascular permeability in meningiomas. *ClinNeuropathol* 1998;7:16-21.
7. Eimoto T, Hashimoto K: Vacuolated meningioma : A light and electron microscopic study. *ActaPatholJpn* 1977;27:557-566

8. Bromley PJ, Grymaloski MR, JetlerPJ: CT appearance of microcystic meningioma. J Comput Assist Tumagr 1996;20:570-572.
9. Paek SH, Kim CY, Kim YY, Park IA , Kim MS. Kim DG et al. Correlation of clinical and biological parameters with peritumoral edema in meningioma. J Neuroncol 2002;60:235-245.
10. Mukherjee S, Ghosh SN, Chatterjee IJ, Chatterjee S. Detection of progesterone receptor and the correlation in Ki-67 labelling index in meningioma. Neurology India 2011; 59(6):817-822.
11. NishioS, Takeshita I, Morioka T, Fukui Mi. Microcystic meningioma; clinicopathological features of 6 Cases. Neurolog Res 1994;16: 251-255.