



## Research Article

# Visual Outcome and Complications Following Nd: YAG Laser Capsulotomy in Postoperative Posterior Capsular Opacification- A Prospective Study

Authors

**Dr K.M Suresh<sup>1</sup>, Dr Suyog A.S<sup>2</sup>, Dr Akhil.P<sup>3</sup>, Dr P. Aparna Sharma<sup>4</sup>**

<sup>1</sup>Associate Professor, Department Of Ophthalmology, Rajarajeswari Medical College and Hospital, Mysore Road, Kengeri, Kambipura, Bengaluru, Karnataka – 560074

<sup>2,3,4</sup>Junior Resident, Department of Ophthalmology, Rajarajeswari Medical College and Hospital, Mysore Road, Kengeri, Kambipura, Bengaluru, Karnataka – 560074

\*Corresponding Author

**Dr Akhil P**

Junior Resident, Rajarajeswari Medical College and Hospital, Mysore Road, Kengeri, Kambipura, Bengaluru, Karnataka – 560074

## Abstract

*Aim of the study was to find out the visual outcome and complications following Nd YAG laser capsulotomy in postoperative posterior capsular opacification.*

**Materials and Methods:** *consist of a prospective study including 100 eyes having postoperative Posterior Capsular Opacification (PCO), attending the Ophthalmology outpatient department of a Medical College in Bengaluru during January 2021 to June 2022. A complete physical and ophthalmological examination was carried out. After taking informed consent, patients underwent Nd YAG laser capsulotomy. Post-operative follow-up was done and observed for any complications till 6 weeks.*

**Conclusion:** *Nd YAG laser capsulotomy is an effective, relatively safe and economical in the management of posterior capsular opacity. To minimise the complications, minimum energy combined with precisely focused shots of Nd YAG laser is needed for having a desired opening in the posterior opacified capsule.*

**Keywords:** *Postoperative Posterior Capsular Opacification, Nd YAG Laser capsulotomy.*

## Introduction

Cataract is defined as the opacification of the crystalline lens or its capsule of the eye that

impairs vision. It is by far the most common curable cause of low vision and blindness worldwide. Cataract has been reported to be

responsible for 50-80% of bilaterally blindness in India<sup>[1]</sup>. Cataract extraction is the most frequently performed surgical procedure in patients over 65 years of age.

Posterior capsular opacification (PCO) is one of the most common late postoperative complications<sup>[2]</sup> of Extracapsular Cataract Extraction (ECCE), Small Incision Cataract Surgery (SICS) and Phacoemulsification<sup>[3]</sup>. The incidence of the development of PCO ranges from 25-50%<sup>[4]</sup>. PCO is a major problem in paediatric cataracts where the incidence approaches 100% between two months and 5 years after surgery<sup>[5]</sup>.

Initially, PCO used to be treated surgically, but now Nd YAG laser capsulotomy remains the treatment of choice<sup>[6,7]</sup>. Nd YAG laser is a pulsed instrument which can be used to photo disrupt the opacified posterior capsule. It is a rapid, painless, non-invasive, relatively safe procedure than surgical capsulotomy and does not require hospitalisation of the patients.

Even though the procedure is easy to perform, it carries multiple risks like intraocular lens pitting, cystoid macular oedema, elevation of intraocular pressure, disruption of anterior vitreous face and rarely retinal detachment<sup>[8,9]</sup>. Also using dual beam partial coherence interferometry showed that a small but measurable backward movement of the IOL occurs after Nd-YAG capsulotomy<sup>[10]</sup>. Patients undergoing Nd-YAG laser capsulotomy, therefore require ongoing medical observation to detect and treat these serious complications<sup>[11,12]</sup>.

This study was undertaken to determine the improvement in best corrected visual acuity following ND YAG laser capsulotomy in patients with postoperative PCO and look for complications of the procedure.

### Methodology

Patients consenting for the study and procedure, with evident Posterior capsular opacification following PCIOL implantation are included in the study. Patients with corneal scars, irregularities or oedema, glass IOL, cystoid macular oedema and

active inflammation were excluded. From all patients detailed present history and past history regarding any systemic illness were recorded. Then they were subjected to visual acuity testing and intraocular pressure testing followed by anterior segment examination by slit lamp biomicroscope. Grading of posterior capsular opacification was done according to Sellman and Lindstrom grading<sup>[13]</sup> as follows.

This is followed by a detailed fundus examination with distant direct ophthalmoscopy and slit lamp examination with +90 D lens and examination of the peripheries with indirect ophthalmoscopy with +20 D lens. OCT was done for the required patients. After diagnosing PCO patients were subjected to Nd-YAG capsulotomy in the affected eye. Post-procedure topical steroids or topical Non-Steroidal Anti-Inflammatory Drugs [NSAIDs] were given and anti-glaucoma drugs were advised when needed. Immediate follow-up and one late follow-up (after 4 weeks post-laser up to 3 months post-laser) was done for all the patients. At each follow up they were subjected to visual acuity testing and intraocular pressure testing followed by anterior segment examination by slit lamp biomicroscope. This was followed by a detailed fundus examination with distant direct ophthalmoscopy and slit lamp examination with +90 D lens and examination of the peripheries with indirect ophthalmoscopy with +20 D lens. Patients were examined for iritis, rise in IOP, retinal detachment, cystoid macular oedema, hyphema.

### Result

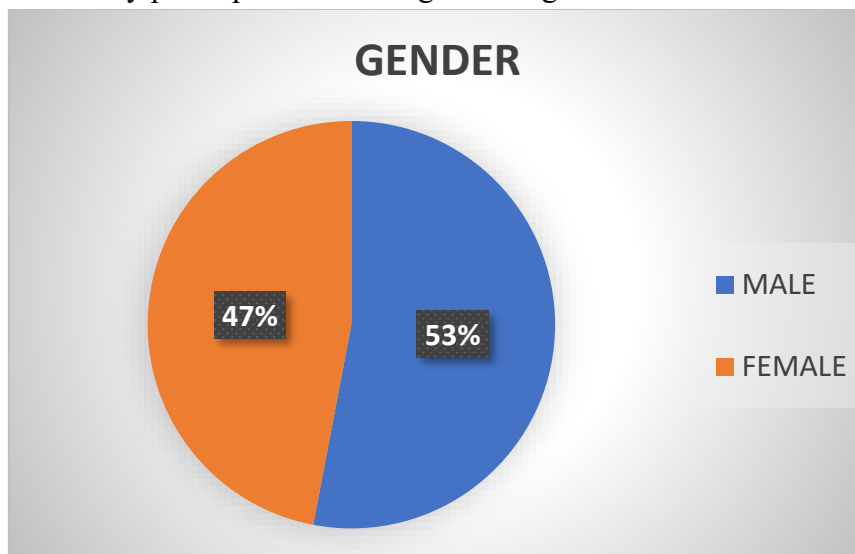
The study population comprised 100 patients, who were diagnosed to have PCO after a detailed evaluation. They were subjected to Nd: YAG laser capsulotomy after taking informed consent. The following observation were made.

**Table 1**-Distribution of study participants according to their age group

AGE	FREQUENCY-N	PERCENTAGE-%
40-50	2	2%
51-60	29	29%
61-70	46	46%
71-80	20	20%
81-90	3	3%
MEAN+/-SD	65.46+/-7.756	

Most of the study participants belonged to the age group 61-70 years (46%) of age. The mean age of the study participants was found to be 65.46+7.756.

**Figure I**– Distribution of study participants according to their gender.



Most of the study participants were males (53%) with females contributing to 47% of the study population.

**Table 2** – Distribution of study participants/ according to their grade of PCO

GRADE OF PCO	FREQUENCY-N	PERCENTAGE-%
1	3	3%
2	37	37%
3	41	41%
4	19	19%

41% of the study participants were having grade 3 of PCO with grade 2 in 37% of the study participants. 19% and 3% of the study participants had grade 4 and grade 1 respectively.

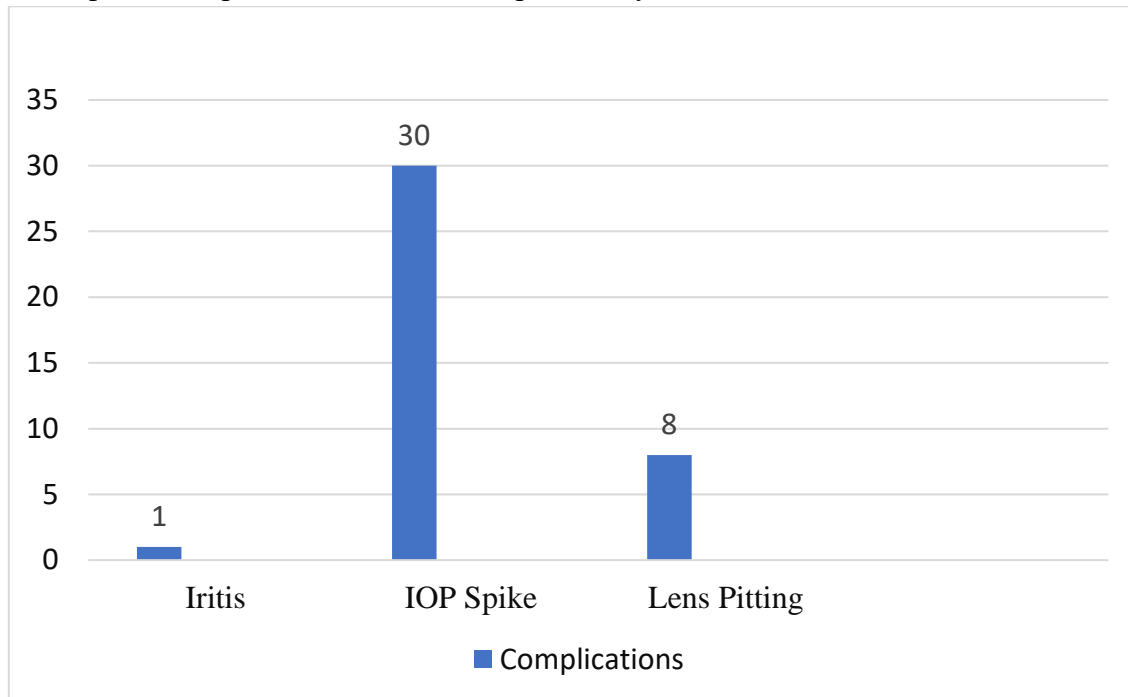
**Table 3** – Energy Used in Nd: YAG capsulotomy.

Energy Used in Nd: YAG Laser capsulotomy	FREQUENCY-N	PERCENTAGE-%
8-10	5	5%
10.1-20	17	17%
20.1-30	23	23%
30.1-40	19	19%
40.1-50	13	13%
50.1-60	17	17%
60.1-70	2	2%
70.1-80	2	2%
80.1-90	2	2%
Mean+/-SD	47.73+/-23.56	

According to the table, the energy used during Nd: YAG laser capsulotomy was in the range of 20.1-30 mJ in 23% of the study participants. The energy required during Nd: YAG laser capsulotomy was in the range of 30.1-40 mJ in 19% of the study participants. The energy required

during Nd: YAG laser capsulotomy was in the range of 50.1-60 mJ and 10.1-20 mJ respectively in 17% of each of the study participants. The mean energy used during Nd: YAG laser capsulotomy was found to be 47.73±23.56

**Figure II - Complications post Nd:YAG Laser capsulotomy**



39% of the study participants developed complications post ND: YAG laser capsulotomy. 30% of the study participants had an IOP spike and 8% of the study participants had Lens pitting.

**Discussion**

In this study, 32% of the study participants had a BCVA of 6/36 and 26% of the study participants had a BCVA of 6/24 pre-laser. 57% and 28% of the study participants had BCVA of 6/6 and 6/9 post-laser, indicating tremendous improvement in visual acuity post-therapy. 80%, 85%, 80.8%, 37.5% and 17.6% of the study participants with Pre-laser BCVA of 6/12, 6/18, 6/24, 6/36 and 6/36 respectively had a Post-laser BCVA of 6/6. 10%, 19.2%, 50% and 29.4% of the study participants with Pre-laser BCVA of 6/18, 6/24, 6/36 and 6/36 respectively had a Post-laser BCVA of 6/9. From the above data, it is inferred that the visual acuity post-laser improves significantly among the study participants. The association was found to be

statistically significant between the pre-laser and post-laser BCVA among the study participants.

In a study done by Jain S et al.<sup>[14]</sup>, Before laser 18% of patients had a VA of ≤ 6/60 and none of the patients had a VA of 6/9 or more. After the laser 32% had a 47 VA of ≥ 6/9 and only 6% of patients had a VA of ≤ 6/60. In a study done by Kumar J et al.<sup>[15]</sup>, the majority of patients 82(73.1%) had VA of 6/36 or less before capsulotomy. Among these 82(73.1%) patients, 52 (46.4%) had VA of less than 6/60 ranging from hand movement to counting of fingers. Visual acuity was improved by one or more Snellen’s lines in 103 (92%) out of 112 eyes after laser capsulotomy. These findings were on par with the findings of the present study.

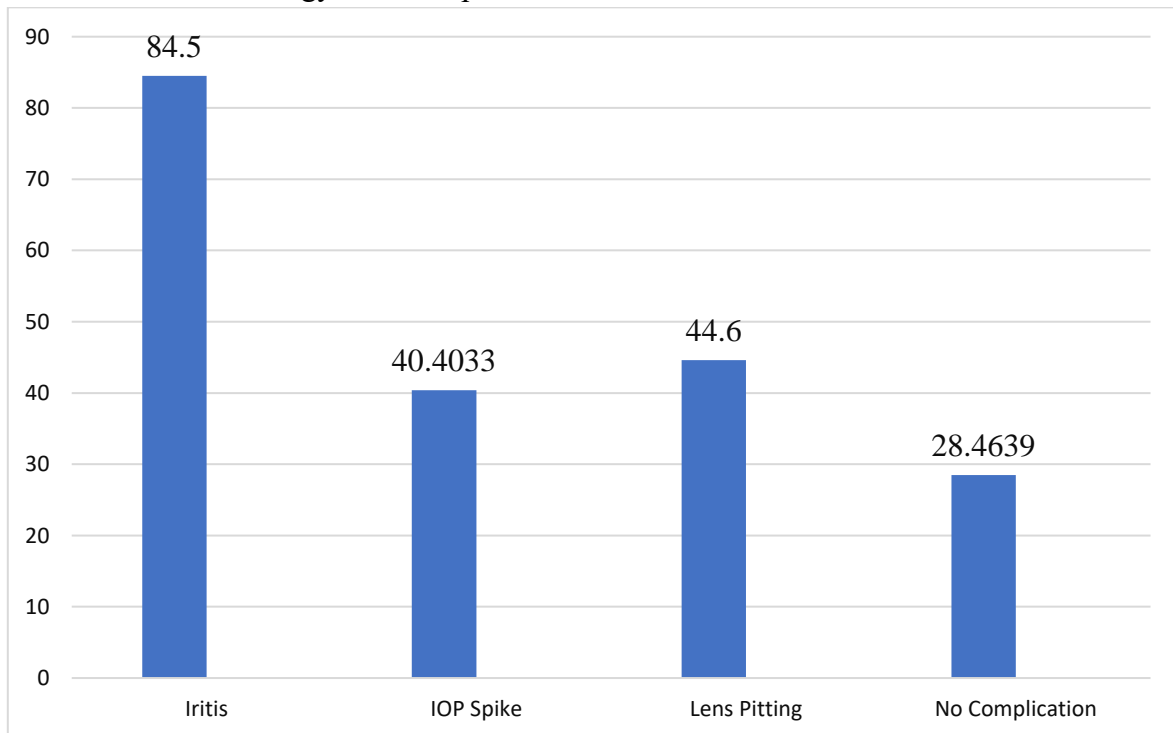
**Table 4:** Association between pre-laser and post-laser BCVA

Pre laser BCVA		Post Laser BCVA					P-value
		6/6	6/9	6/12	6/18	6/24	
6/12	Count	4	0	1	0	0	>0.001
	%	80%	0%	20%	0%	0%	
6/18	Count	17	2	1	0	0	
	%	85%	10%	5%	0%	0%	
6/24	Count	21	5	0	0	0	
	%	80.8%	19.2%	0%	0%	0%	
6/36	Count	12	16	4	0	0	
	%	37.5%	50%	12.5%	0%	0%	
6/60	Count	3	5	5	3	1	
	%	17.6%	29.4%	29.4%	17.6%	5.9%	

In this study, the mean energy used in ND: YAG among study participants with and without complications was found to be 42.39 + 16.27 and 28.46 + 14.40 respectively. Among study participants with complications, the mean energy used among study participants with IOL pitting, IOP spike and lens pitting were found to be 84.50, 40.40+14.14 and 44.60 +18.28 respectively. The association was found to be statistically significant between the energy used in ND: YAG and the complications of the study participants.

In a study done by Kumar J et al.<sup>[15]</sup>, capsulotomy ranged from 12 mJ to 120 mJ. There are comparatively a greater number of cases showing IOP rise in higher energy levels (>50mJ), but there was no significant linear correlation found between energy used and IOP rise after laser capsulotomy (p=0.179). This is in contrast with the findings of the present study. In a study done by G S Gopinath et al.<sup>[16]</sup>, Elevated IOP is recognized as the most common complication following Nd: YAG laser capsulotomy where increased IOP was found in 30% of patients.

**Figure III-** Association of energy with complication



### Conclusion

Nd: YAG laser capsulotomy is an effective, safe, fast and non-invasive technique to improve hindered vision by PCO. To avoid severe complications, it is suggested that energy level should be kept to a minimum level and use with some degree of caution and vigilance. This study has limitations. The sample was small and represents the results at a single Centre only. The results were based on a short-term follow-up period.

Posterior capsular opacification is a common complication after cataract surgery worldwide and it can be managed safely by Nd YAG Laser posterior capsulotomy. Nd: YAG laser capsulotomy is a safe and effective method to treat PCO. It is non-invasive and avoids all the complications associated with surgical capsulotomy and local anaesthesia. There is an excellent improvement in visual acuity in the majority of the patients. However, Nd: YAG laser capsulotomy also carries risks like IOL pitting, CME, IOP spikes, aqueous flare and vitritis, etc. IOP monitoring is mandatory after Nd -YAG laser capsulotomy. In the majority of the patients, the IOP spikes are transient and can be treated with topical medication. By minimising energy and the number of precisely focused shots with proper follow-up, Nd: YAG capsulotomy becomes the management of choice for posterior capsular opacification.

### Reference

1. Thulisiraj R D, Nirmalan P K, Ramakrishnan R. et al Blindness and vision impairment in a rural south Indian population: the Aravind Comprehensive Eye Survey. *Ophthalmology* 2003;110:491–498. [Google Scholar]
2. Vasavada AR, Chauhan H, Shah G. Incidence of posterior capsular plaque in cataract surgery. *J. Cataract Refract Surg.* 1997;23(5):798. [PubMed] [Google Scholar]
3. Chambless WS. Neodymium: YAG laser posterior capsulotomy results and complications. *J Am Intraocular Implant Soc.* 1985 Jan;11(1):31–2. PMID: 3838167. [PubMed] [Google Scholar]
4. Schaumberg DA, Dana MR, Christen WG, Glynn RJ. A systematic overview of the incidence of posterior capsule opacification. *Ophthalmology.* 1998;105:1213–1221. - PubMed
5. Spierer A, Desatnik H, Blumenthal M. Refractive status in children after long-term follow up of cataract surgery with intraocular lens implantation. *J Pediatr Ophthalmol Strabismus.* 1999;36:25–29. [PubMed] [Google Scholar]
6. Evaluation of visual function following neodymium: YAG laser posterior capsulotomy BV Magno, MB Datiles, MSM Lasa, MRQ Fajardo... - *Ophthalmology*, 1997 - Elsevier
7. Correlation between posterior capsule opacification and visual function before and after Neodymium: YAG laser posterior capsulotomy K Hayashi, H Hayashi, F Nakao, F Hayashi - *American journal of ...*, 2003 - Elsevier
8. Ari S, Cingu AK, Sahin A, inar YC, Caca I. The effects of Nd: YAG laser posterior capsulotomy on macular thickness, intraocular pressure, and visual acuity. *Ophthalmic Surg Lasers Imaging.* 2012 Sep-Oct;43(5):395–400. doi: 10.3928/15428877-20120705-03. PMID: 22785102. [PubMed] [Google Scholar]
9. Steinert RF, Puliafito CA, Kumar SR, Dudak SD, Patel S. Cystoid macular edema, retinal detachment, and glaucoma after Nd:YAG laser posterior capsulotomy. *Am J Ophthalmol.* 1991 Oct;112(4):373–80. PMID: 1928237. [PubMed] [Google Scholar]
10. Findl O, Drexler W, Menapace R, et al. Changes in intraocular lens position after



- neodymium:YAG capsulotomy. *J Cataract Refract Surg.* 1999;25(5):659–662. [PubMed] [Google Scholar]
11. Evicman T, Ozkurt Y, Sengor T, Haboglu M, Kurna S, Aki S. Anterior chamber depth changes and complications after Nd:YAG laser treatment for posterior capsule opacification in pseudophakic eyes. *Acta Ophthalmol.* 2007;85(Suppl s240) [Google Scholar]
  12. Wormstone IM, Eldred JA. Experimental models for posterior capsule opacification research. *Exp Eye Res.* 2016;142:2 doi: 10.1016/j.exer.2015.04.021. [PubMed] [CrossRef] [Google Scholar]
  13. Sellman TR, Lindstrom RL. Effect of a plano-convex posterior chamber lens on capsular opacification from Elschnig pearl formation. *J Cataract Refract Surg* 1988;14:68–72. [PubMed] [Google Scholar][14] Jain S, Chandravanshi SL, Jain G, Tirkey E, Jain SC. Effect of ND: YAG laser capsulotomy in pseudophakic eyes with special reference to IOP changes. *Journal of Evolution of Medical and Dental Sciences.* 2014; 3(55):12627-35.
  14. Dr J Kumar, Dr.Punam Tiwari,etal. “A study of visual outcome and complications following Nd: YAG laser posterior capsulotomy in posterior capsule opacification.” *IOSR Journal of Dental and Medical Sciences (IOSR-JDMS),* 19(4), 2020, pp. 36-40.
  15. Gopinath GS, Satish K, Srivastava N, Patil S, Afshan R. Visual Outcome and Complications of YAG Laser Therapy for Posterior Capsular Opacification Following Cataract Surgery. *Int J Sci Stud* 2015;3(3):65-68.