



## Infantile Mucocele in Disguise – A Case Report

Authors

**Danu Dayakar P S<sup>1</sup>, Rita Zarina A<sup>2</sup>, Digesh Balachandran<sup>3</sup>, Yadukrishnan MS<sup>4</sup>**

<sup>1</sup>Junior Resident, Dept. of Pediatric and Preventive Dentistry, Government Dental College, Thiruvananthapuram, Kerala, India

<sup>2</sup>Professor and Head, Dept. of Pediatric and Preventive Dentistry, Government Dental College, Thiruvananthapuram, Kerala, India

<sup>3</sup>Associate Professor, Dept. of Pediatric and Preventive Dentistry, Government Dental College, Thiruvananthapuram, Kerala, India

<sup>4</sup>Junior Resident, Dept. of Pediatric and Preventive Dentistry, Government Dental College, Thiruvananthapuram, Kerala, India

### Abstract

*Mucocele is a common oral lesion that is seen predominantly in children. It usually occurs as a result of trauma, due to habits like lip biting and cheek biting or any factors leading to obstruction of salivary gland ducts. They can occur in various locations inside the oral cavity like the buccal mucosa, ventral surface of the tongue, retromolar region, floor of the mouth, etc., with the lower lip being the most predominant area.<sup>1</sup> They are usually managed by surgical excision, although, newer techniques like laser ablation, laser surgery, cryosurgery, micro-marsupialization, and intralesional injection of sclerosing agents / corticosteroids are also in use.<sup>2</sup> We present here an unusual presentation of mucocele in a 3-month-old child.*

**Keywords-** *Mucocele, infant, surgical excision, unusual mucocele, fibroepithelial polyp transformed into a mucocele, unusual mucocele.*

### Introduction

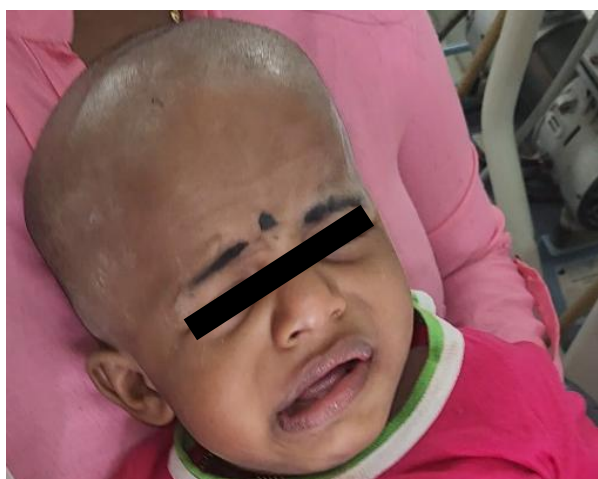Mucoceles are defined as mucous-filled cavities, which can appear in the oral cavity, appendix, gallbladder, paranasal sinuses, and lacrimal sac.<sup>1</sup> It is a swelling like a sac that is due to the distension of a hollow organ or cavity with mucous.<sup>3</sup> Oral mucoceles are formed due to the rupture of a minor salivary gland excretory duct, with subsequent leakage of mucin into the adjacent connective tissues that later may be surrounded in a fibrous

capsule.<sup>4</sup> The term mucocele was derived from two Latin words mucus (meaning mucous) and coele (meaning cavity).<sup>5</sup> Mucocele is a common salivary gland disorder and it is the second most common benign soft tissue tumour in the oral cavity.<sup>6</sup> They are usually well-circumscribed, rounded, fluctuant and bluish-coloured (deeper lesions are of normal colour). There are two types of mucoceles, an extravasation type and a retention type. The extravasation type is the one associated with lip

biting and trauma and the retention type are usually associated with obstruction of the salivary gland duct.<sup>1</sup> Extravasation mucoceles are often referred to as pseudocysts because they lack the epithelial lining, whereas the retention cyst has an epithelial lining.<sup>7</sup> The blue colour is imparted as a result of vascular congestion, cyanosis of the tissue above, and accumulation of the fluid below.<sup>5</sup> Mucoceles are usually asymptomatic, however they can cause difficulty in speech and chewing if their size is large.<sup>8</sup> They are notorious for their recurrence. If left untreated they can invariably increase or decrease in size, may rupture, and then may reappear.<sup>1</sup> The peak age of incidence is between 10 to 20 years. Here we showcase a report of a mucocele in a 3-month-old child with an atypical presentation.

### Case Report

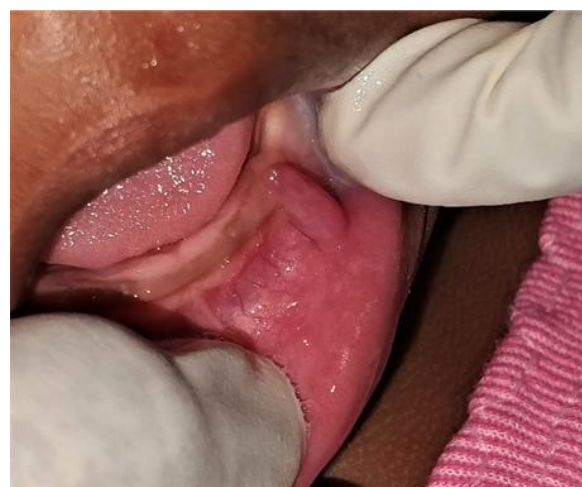A 3-month-old child (Fig: 1) was brought to the OP wing of the Department of Pediatric and Preventive Dentistry, Government Dental College, Thiruvananthapuram, with a chief complaint of swelling on the lower lip of 1 month duration.



**Fig: 1.** A 3-month old boy.

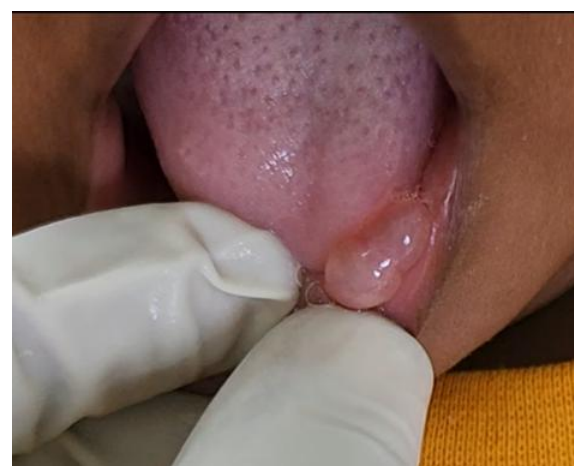
Parents noticed a small swelling on the left lower lip when the child was 2 months of age, which rapidly progressed to the present size within a time span of 1 month. There was no associated difficulty in feeding. Initial examination revealed a pedunculated stalk-like fibrous lesion of size 1.3cm x 0.4cm x 0.4cm (Fig: 2) in the left lower labial mucosa. The

colour of the lesion was similar to that of oral mucosa. An initial provisional diagnosis of a fibroepithelial polyp was made and the child was kept on follow-up.



**Fig: 2.** Initial examination of lesion.

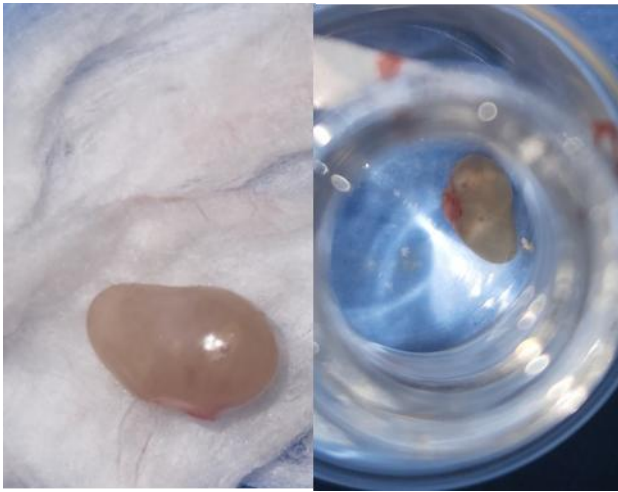
A follow up examination at 6 months of age, revealed, a marked change in the dimensions of the lesion. The pedunculated lesion unexpectedly transformed into a fluctuant, cystic lesion of size 0.6cm x 1.4cm x 0.6cm (Fig: 3). Hence, a decision to excise the lesion was made.



**Fig: 3.** Subsequent examination of lesion at 6 months of age.

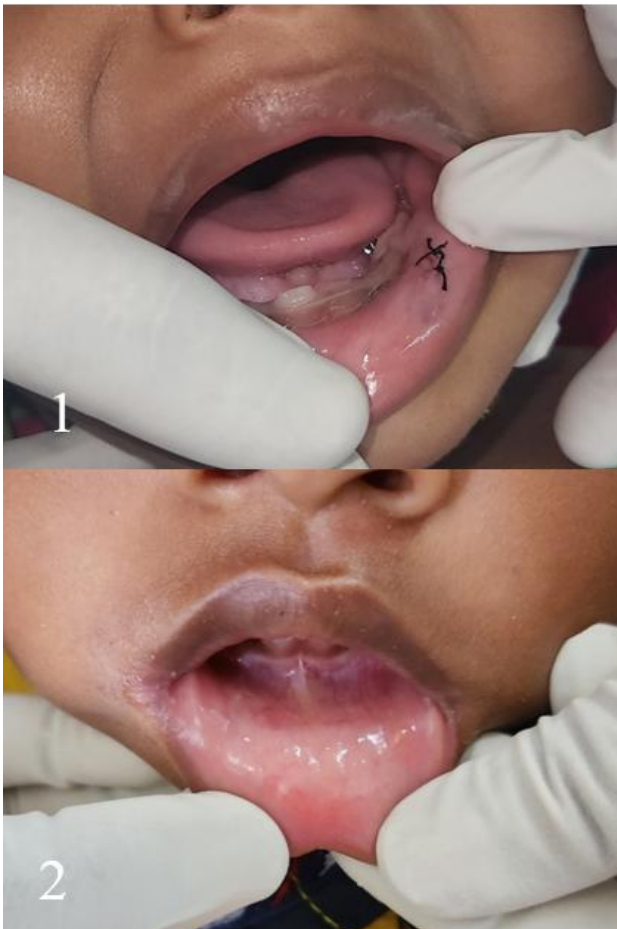The excision of the lesion was done under local anaesthesia. Two releasing incisions were made at the base of the lesion and the tissue was excised using a number 15 Bard Parker blade. The entire lesion was removed till its base without damaging the adjacent glands. The surgical site was sutured

using a 4-0 black braided silk (Fig: 5). The specimen (Fig: 4) was sent for histopathological analysis and a final diagnosis of mucocele was made.



**Fig: 4.** Excised lesion

The suture was removed after a week. Follow-up of the patient after 2 months revealed a resolving lesion (Fig: 5).



**Fig: 5.**(1) Sutured with 4-0 black braided silk, (2) Follow up after 2 months.

## Discussion

Mucocele is a benign cystic lesion of the oral cavity. According to literature, the incidence of mucocele is 2.5 per 1000 patients, frequently occurring in the second decade of life. It is found rarely in children and infants under one year of age.<sup>9</sup> We initially refrained from diagnosing the lesion as a mucocele due to its exceptional presentation and low predilection in infants. Mucoceles have a predilection for the lower lip which is substantiated by the fact that the lower lip is a usual site of trauma in children. Lip biting habit also contributes to the predilection. However, they can be found anywhere in the oral cavity where minor salivary glands are present. Due to the absence of an epithelial lining, mucous extravasation cysts are seen as poorly defined spaces containing eosinophilic mucinous material, condensed fibrous material, granulation tissue, infiltrates of polymorph nuclear leukocytes, macrophages, lymphocytes, and eosinophils. However mucous retention cysts are lined by epithelium.<sup>10</sup>

The appearance of mucoceles is pathognomonic and diagnosis is mainly based on clinical findings, site of the lesion, rapidity in progression, history of trauma, bluish-colour, variations in size, and fluctuance. A thorough examination is mandatory before a final diagnosis. Radiographs are of limited value except for detecting calculi/sialoliths which can help to differentiate retention cysts from extravasation cysts. Histopathological analysis can confirm the diagnosis.

Mucoceleles are found to be self-resolving however the time can vary from days to years. Though mucoceles are asymptomatic they can cause pain, difficulty in speech and chewing/feeding, and can also become a cause of constant irritation. Moreover, the lesion can rupture spill out their contents, and recur.

Surgical excision is the treatment of choice for these lesions. However newer methods like laser ablation, cryosurgery, micro-marsupialization, laser surgery, and intralesional injection of sclerosing agents/corticosteroids are also in use.<sup>2</sup> Surgical excision if not properly done can lead to recurrence.

To prevent this, the lesion should be removed down to the muscle layer, and the surrounding glandular acini must also be removed.<sup>5</sup> Extra care should be made while placing the sutures so that it doesn't traumatize surrounding glands.

### Conclusion

One of the main aetiologies of mucoceles are oral habits hence its essential to spread awareness and intercept these habits in children at the earliest. Recurrent trauma from a sharp cusped tooth can also lead to a mucocele hence it's mandatory to have a dental check at least once every 6 months to mitigate these etiological factors. Surgical excision is the faster method available for the management of the lesion.<sup>1</sup> If done correctly ie removing the entire lesion till its base without damaging adjacent glands, it offers the best results.

### References

1. Nallasivam KU, Sudha BR. Oral mucocele: Review of literature and a case report. *J Pharm Bioallied Sci.* 2015 Aug;7(Suppl 2):S731-3. doi: 10.4103/0975-7406.163516. PMID: 26538955; PMCID: PMC4606697.
2. Gaikwad, Trupti Vijay; Maini, Anuj Paul; Das, Sukanya; Lokhande, Sayali; Patil, Shruti K; Sarma, Arunima. Nonsurgical Management of Oral Mucocele Occurring on a Rare Site. *Contemporary Clinical Dentistry* 13(4):p 389-391, Oct–Dec 2022. | DOI: 10.4103/ccd.ccd\_531\_21.
3. "Mucocele." Merriam-Webster.com Medical Dictionary, Merriam-Webster, <https://www.merriam-webster.com/medical/mucocele>. Accessed 26 Apr. 2023.
4. American Academy of Pediatric Dentistry. Management considerations for pediatric oral surgery and oral pathology. *The Reference Manual of Pediatric Dentistry*. Chicago, Ill.: American Academy of Pediatric Dentistry; 2022:485-94.
5. Chaitanya P, Praveen D, Reddy M. Mucocele on Lower Lip: A Case Series. *Indian Dermatol Online J.* 2017 May-Jun;8(3):205-207. doi: 10.4103/idoj.IDOJ\_151\_16. PMID: 28584760; PMCID: PMC5447343.
6. Laller, Sanjeev, et al. "Case report an appraisal of oral mucous extravasation cyst case with mini review." *Journal of Advanced Medical and Dental Sciences Research* 2.2 (2014).
7. Senthilkumar B, Mahabob MN. Mucocele: An unusual presentation of the minor salivary gland lesion. *J Pharm Bioallied Sci.* 2012 Aug;4(Suppl 2):S180-2. doi: 10.4103/0975-7406.100265. PMID: 23066247; PMCID: PMC3467912.
8. Sinha R, Sarkar S, Khaitan T, Kabiraj A, Maji A. Nonsurgical Management of Oral Mucocele by Intralesional Corticosteroid Therapy. *Int J Dent [Internet]*. 2016 [cited 2023 Apr 26];2016:2896748. Available from: <https://www.ncbi.nlm.nih.gov/pmc/articles/PMC5086369/>
9. Yamasoba T, Tayama N, Syoji M, Fukuta M. Clinicosatistical study of lower lip mucoceles. *Head Neck.* 1990 Jul-Aug;12(4):316-20. doi: 10.1002/hed.2880120407. PMID: 2193904.
10. Jandrajupalli, Suresh. (2018). Mucocele: A Case Report with Literature Review.