



Child with Acute Flaccid Myelitis presenting as Upper Limb Monoparesis

Authors

Dr Gaurav Sharma¹, Dr Richa Sharma², Dr Pallavi Sharma³, Dr Garima Sharma⁴

¹Senior Resident, Department of Paediatrics, Aastha Hospital Shimla

²Senior Resident, Department of Ophthalmology, TNMC and BYL Nair hospital Mumbai

³Senior Resident, Gynaecology Obstetrics, GMCH 32, Chandigarh

⁴Assistant Professor, Microbiology IGMC, Shimla

Corresponding Author

Dr Richa Sharma

Department of ophthalmology TNMC and BYL Nair hospital, Mumbai

Introduction

Acute flaccid myelitis (AFM) is a neurologic illness of sudden onset in children. It presents with localised limb weakness of unknown cause. Enterovirus 68, which as a member of the enterovirus family related to polio, and is a leading candidate for the cause of the condition.

Since August 2014, CDC has been made aware of an increased number of people across the United States with AFM for which no cause could be found. Since then, CDC has been actively investigating this illness. In 2016, a total of 144 people in 37 states across the country were confirmed to have AFM.

Case Report

A 13 year old adolescent male presented with fever and cough for 3 days followed by pain in the neck and shoulder and sudden weakness of right upper limb. The weakness was noticed early morning on the 4th day of illness when the child was not able to move his right limb, he could not button up his clothes and comb his hair with his right hand. All the other limbs were normal. On history the following findings were noted.

Sensations of touch ,pin prick , hot and cold	Normal
gait	Normal
Vertigo	none
Seizures or loss of consciousness	none

On Examination

Higher mental functions	Normal
Cranial nerve functions	Normal

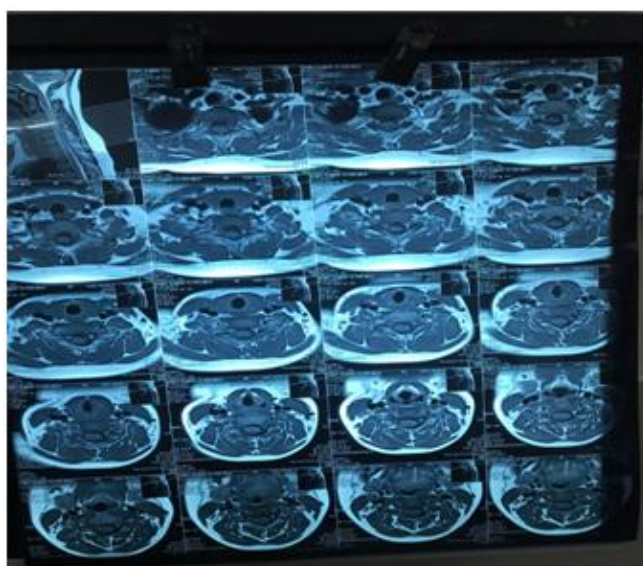
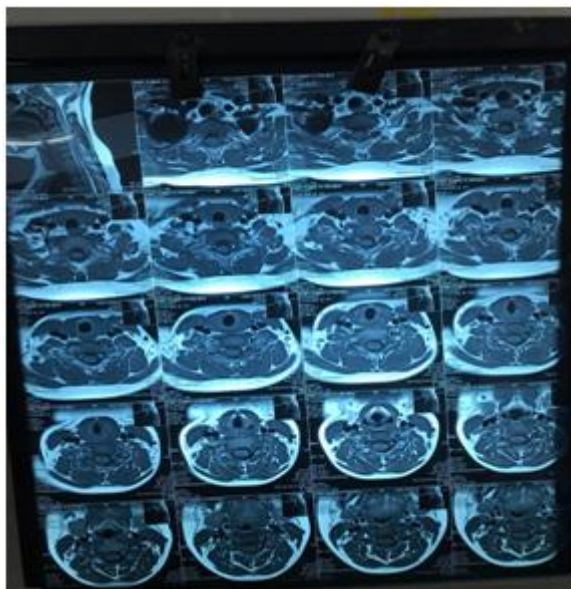Motor examination	Right upper limb	Left upper limb
Bulk	normal	normal
tone	Decreased	normal
power	0_ to 1 in all muscles	Normal
Reflexs	Biceps, triceps and supinator reflex absent	normal

Sensory examination of both upper and lower limbs was normal. No meningeal signs with normal cerebellar functions.

On the basis of history and physical examination the diagnosis of **LMN type pure motor monoplegia** was kept and child investigated.

Investigations

MRI of cervical and upper thoracic spine	myelitis of C3 to C7 spinal cord with only involvement of anterior horn of spinal cord
CSF	pleocytosis with 70 WBCS, all lymphocytes with normal protein and sugar.
CBNAAT of CSF	Negative



MRI depicting Anterior myelitis of c3 to c7 spine

The diagnosis of acute flaccid myelitis was kept and given IV Ig and was kept under follow up. He was discharged and kept under follow-up.

Discussion

In the post-polio vaccination era, acute flaccid paralysis has become associated with a host of

diagnoses, including spinal cord tumours, trauma, transverse myelitis, Guillain–Barr e syndrome and less common conditions such as botulism and porphyria. Infection remains an important cause of acute flaccid paralysis, with flaviviruses, herpesviruses, adenoviruses and enteroviruses (EV) all causing this syndrome in the developed and developing world. Acute flaccid myelitis is typified by weakness and hypotonia in one or more limbs, with sensation and autonomic function being spared (in contrast to transverse myelitis, in which sensory deficits and autonomic dysfunction are common). Weakness may be incomplete. Magnetic resonance imaging (MRI) of the spine demonstrates grey matter involvement with a predilection for the anterior horns, with or without concomitant brainstem involvement.

A polio-like illness of unknown aetiology termed acute flaccid myelitis (AFM) has been reported in the United States, with the Centres for Disease Control and Prevention (CDC) confirming 277 cases from August 2014 through December 2016, with 136 cases in the year 2016 alone^[1]. Similar cases have been reported from Europe and Canada^[2-6]. The condition predominantly affects children and young adults^[7,8]. Characteristic features of this disorder are a febrile or respiratory illness before the onset of neurologic symptoms, and a presentation similar to poliomyelitis with limb weakness, variable cranial nerve involvement (egfacial weakness, ophthalmoplegia, dysarthria, or dysphagia), and MRI evidence of Gray matter involvement in the spinal cord. Recovery is generally limited.

Clinical criteria for a confirmed case of AFM require the acute onset of focal limb weakness and a spinal cord lesion on MRI largely restricted to Gray matter and spanning one or more spinal segments^[9]. Criteria for a probable case of AFM (in patients without MRI) require acute onset of focal limb weakness and cerebrospinal fluid pleocytosis (ie, a white count >5 cells/microL after adjustment by subtraction of 1 white cell for every 500 red cells). The CDC also requests that clinicians collect and submit specimens to the

CDC for testing as early as possible in the course of the illness, to include cerebrospinal fluid, blood, and stool. The CDC requests submission of nasopharyngeal or nasal (mid-turbinate) plus oropharyngeal swab specimens only if the patient tests positive for enterovirus or rhinovirus at an external lab. Specimens submitted to the CDC are not intended for clinical diagnosis; pathogen-specific testing should be performed at hospital or state public health laboratories. Although evidence is limited to clinical experience, immunomodulatory therapies or interventions used to treat acute flaccid myelitis (AFM) have shown no evidence of effectiveness, including glucocorticoids, intravenous immune globulin, plasma exchange, interferon, antivirals, or other immunomodulatory agents^[7,10,11]. Thus, management is supportive.

Conclusion

Acute flaccid myelitis is an uncommon condition in childhood with a high rate of significant long-term morbidity. This condition should be suspected in the setting of acute limb pain associated with a lower motor neuron pattern of weakness.

References

1. AFM in the United States. <https://www.cdc.gov/acute-flaccid-myelitis/afm-surveillance.html> (Accessed on April 06, 2017).
2. Lang M, Mirand A, Savy N, et al. Acute flaccid paralysis following enterovirus D68 associated pneumonia, France, 2014. *Euro Surveill* 2014; 19.
3. Crone M, Tellier R, Wei XC, et al. Polio-Like Illness Associated With Outbreak of Upper Respiratory Tract Infection in Children. *J Child Neurol* 2016; 31:409.
4. Pfeiffer HC, Bragstad K, Skram MK, et al. Two cases of acute severe flaccid myelitis associated with enterovirus D68 infection in children, Norway, autumn 2014. *Euro Surveill* 2015; 20:21062.
5. Williams CJ, Thomas RH, Pickersgill TP, et al. Cluster of atypical adult Guillain-Barré syndrome temporally associated with neurological illness due to EV-D68 in children, South Wales, United Kingdom, October 2015 to January 2016. *Euro Surveill* 2016; 21.
6. Yea C, Bitnun A, Robinson J, et al. Longitudinal Outcomes in the 2014 Acute Flaccid Paralysis Cluster in Canada. *J Child Neurol* 2017; 32:301.
7. Van Haren K, Ayscue P, Waubant E, et al. Acute Flaccid Myelitis of Unknown Etiology in California, 2012-2015. *JAMA* 2015; 314:2663.
8. Messacar K, Schreiner TL, Van Haren K, et al. Acute flaccid myelitis: A clinical review of US cases 2012-2015. *Ann Neurol* 2016; 80:326.
9. Centers for Disease Control and Prevention. Acute flaccid myelitis investigation: For clinicians. www.cdc.gov/ncird/investigation/viral/2014-15/hcp.html (Accessed on January 06, 2016).
10. Centers for Disease Control and Prevention. Acute flaccid myelitis: interim considerations for clinical management. www.cdc.gov/ncird/downloads/acute-flaccid-myelitis.pdf (Accessed on November 21, 2014).
11. Messacar K, Schreiner TL, Maloney JA, et al. A cluster of acute flaccid paralysis and cranial nerve dysfunction temporally associated with an outbreak of enterovirus D68 in children in Colorado, USA. *Lancet* 2015; 385:1662.