



A RARE CASE OF ARTERIOVENOUS MALFORMATION OF THE PINNA AND REVIEW OF LITERATURE

*Dr. Bijendar Kumar Meena, Dr. Sweta Meena, Dr. Abhishek Gupta, Dr. M.L.Meena,
Dr.S.C. Baser*

1. Dr. BIJENDAR KUMAR MEENA:-3rd YEAR RESIDENT IN RADIODIAGNOSIS R.N.T. MEDICAL COLLEGE UDAIPUR

EMAIL ID: -dr.biji2004@gmail.com

2.Dr. SWETA MEENA:-2nd YEAR RESIDENT IN PATHOLOGY R.N.T. MEDICAL COLLEGE UDAIPUR

EMAIL ID:-swetabj@gmail.com

3.Dr.ABHISHEK GUPTA:-2ND YEAR RESIDENT IN RADIODIAGNOSIS R.N.T. MEDICAL COLLEGE UDAIPUR

EMAIL ID:-abhishek2785@gmail.com

4.Dr. M.L.MEENA:-PROFFESOR&HOD RADIODIAGNOSIS R.N.T. MEDICAL COLLEGE UDAIPUR

EMAIL ID:-mlhodrd@gmail.com

5.Dr.S.C. BASER:- PROFFESOR RADIODIAGNOSIS R.N.T. MEDICAL COLLEGE UDAIPUR

EMAIL ID:-sureshbaser@gmail.com

Abstract-

The external ear is the second most common site for extracranial arteriovenous malformation in the head and neck. Arteriovenous malformations are rare in the head and neck region and generally arise from intracranial vessels. We present a case with spontaneous arteriovenous malformation related to the pinna arising from branches of external carotid artery and draining into external jugular vein. The role of colour Doppler sonography and computer tomography in the diagnosis and management of such cases is discussed along with a review of the literature.

History mmanuel, Luschka and Virchow first described arteriovenous malformations in the mid-1800s. Olivecrona performed the first surgical excision of an intracranial AVM in 1932.

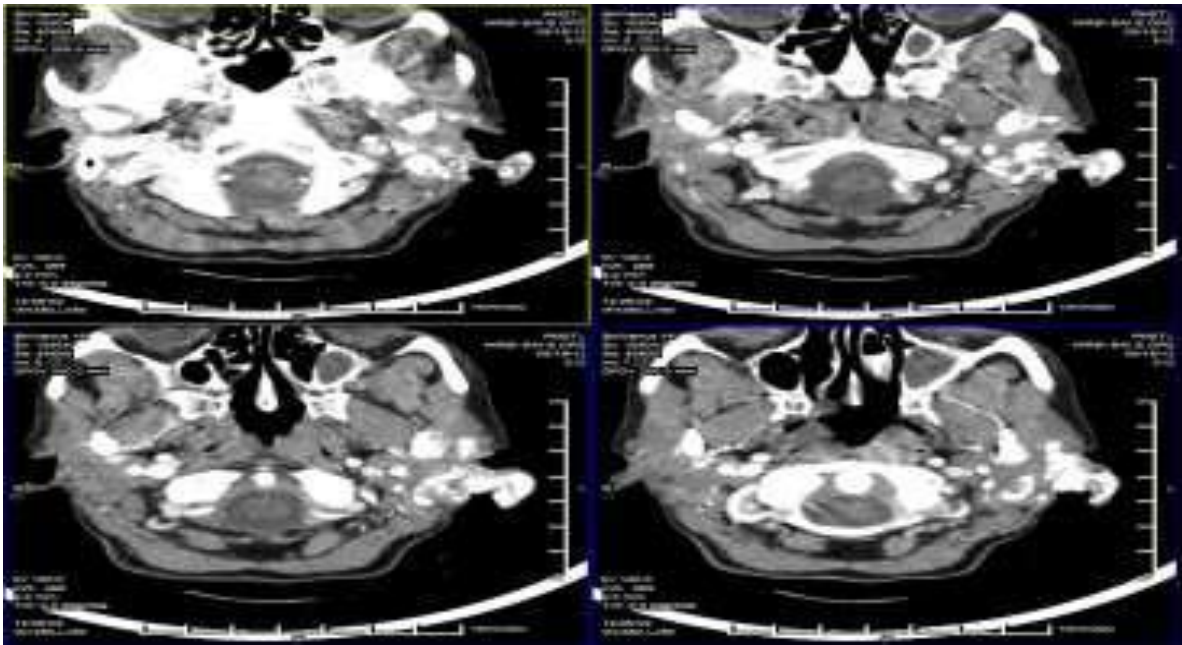
Introduction

Arteriovenous malformation or AVM is an abnormal connection between arteries and veins, bypassing the capillary system. This vascular anomaly is widely known because of its occurrence in the central nervous system, but can appear in any location. Although many AVMs are asymptomatic, they can cause intense pain or bleeding or lead to other serious medical problems. AVMs are usually congenital and belong to the RASopathies. The genetic transmission patterns of AVM, if any, are unknown. AVM is not generally thought to be an inherited disorder, unless in the context of a specific hereditary syndrome. Arteriovenous malformations (AVMs) are lesions related to errors of vascular morphogenesis. These are almost always present at birth, manifest late in life and require treatment. There is no sex predilection. These must be differentiated from haemangiomas, which are neoplastic, affect females more than males, and may regress spontaneously. Histologically, haemangiomas show endothelial proliferation in contrast to AVM, which have none.

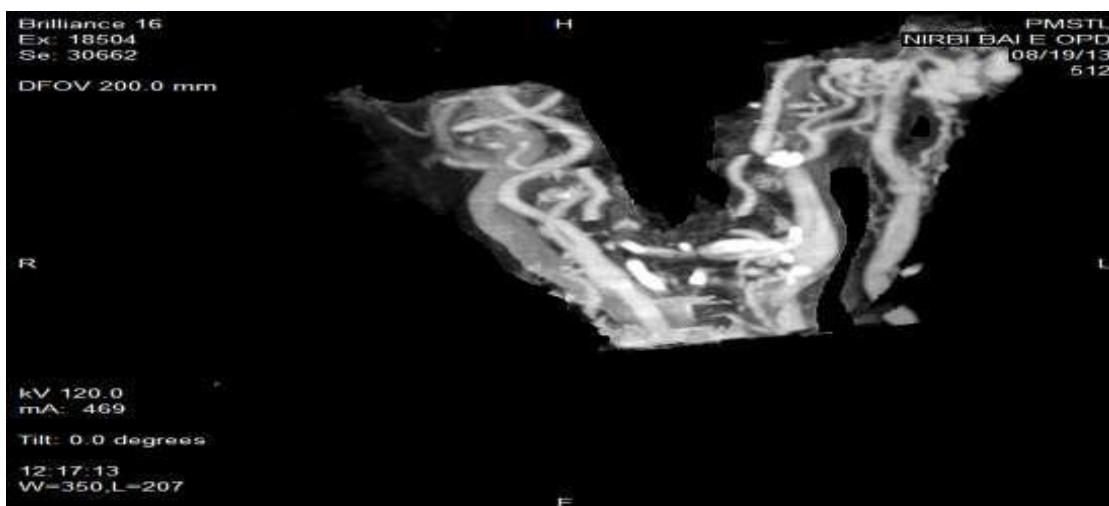Case report

A 21-year-old female presented to the otorhinolaryngology out-patient department OF R.N.T. MEDICAL COLLEGE UDAIPUR with a history of swelling and skin discolouration in the helix of the left pinna with increase in size over the

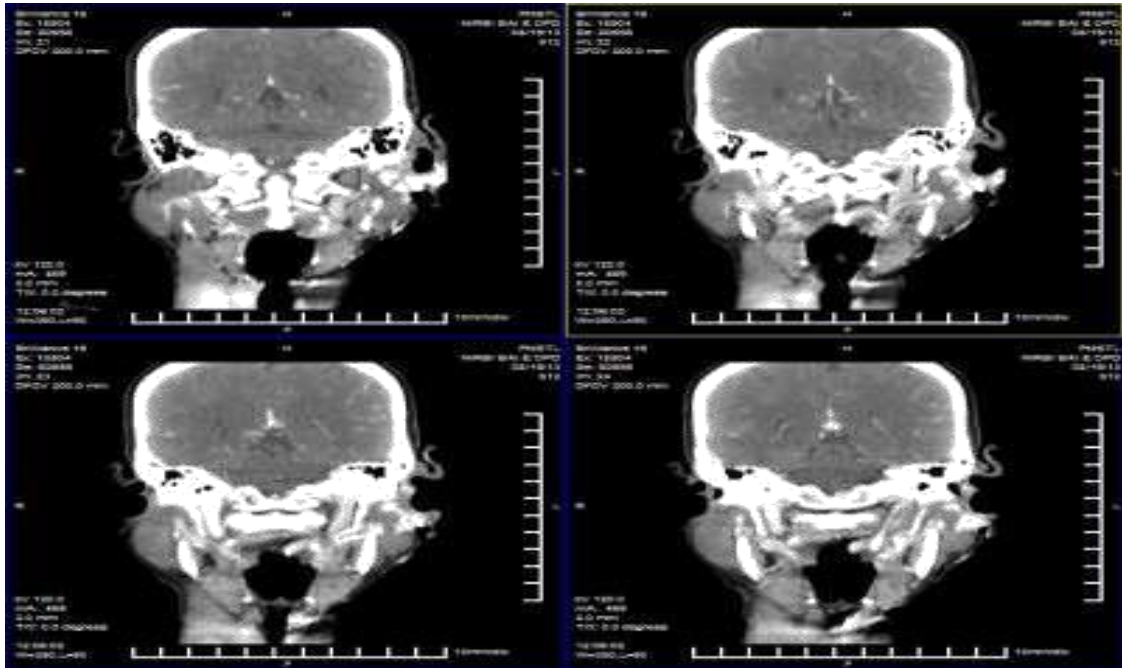
last 1 years, following childbirth. There had been two episodes of bleeding. The patient also complained of disturbing tinnitus of the continuous ‘blowing’ type. There was no history of trauma to the ear or headaches. On physical examination a pulsatile swelling with areas of skin discolouration and necrosis was seen in the left pinna region. On palpation the swelling was soft, non-compressible, spongy, non-tender, and pulsatile with a thrill. A continuous bruit could be heard on auscultation. The ear canal and the tympanic membrane were normal. A clinical diagnosis of AVM was made. Colour Doppler sonography showed multiple dilated anechoic areas in B-mode, while power Doppler & spectral Doppler revealed multiple dilated tortuous vascular channels with formation of nidus. Further a CT angiogram was done which revealed multiple dilated vascular channels in left external ear region with formation of tangle of vessels (nidus). An axial angiogram demonstrated enlarged serpiginous structures showing flow-related enhancement in the left auricular and pinna region {A}. The dilated channels were from posterior auricular artery & auricular branches of superficial temporal artery (the feeding arteries) {B}, which were forming nidus with dilated external jugular vein (The draining vein). The external jugular vein shows early contrast filling in arterial phase {C}. The histology was consistent with an AVM.



(A.CECT AXIAL IMAGE:- enlarged serpiginous structures showing flow-related enhancement in the left auricular and pinna region)



(B. 3D-VOLUMATRIC ANGIOGRAPHIC IMAGE:- showing feeding arteries & draining vein)



(C.CECT CORONAL IMAGES:-SHOWING A-V MALFORMATION IN LEFT PINNA, Opacification of EJV in arterial phase)

Discussion

Arteriovenous malformations are rare in the auricular region but are common intracranially. They can be divided into two categories: fast-flowing and slow-flowing lesions. Fast flowing lesions are predominantly arteriovenous fistulas whereas venous, capillary, and lymphatic lesions produce slow blood flow malformations.¹ The AVM is composed of a central nidus with anomalous arteriovenous shunts and a network of surrounding collateral vessels.² The short circuit or shunting between the high pressure arterial and low pressure venous system accounts for much of the clinical presentation, anatomical changes, and progression of the lesions. Schobinger described a clinical staging system for vascular malformations, that is, stage I (quiescence) – cutaneous blush/warmth;

stage II (expansion) – bruit, audible pulsations, expanding lesions; stage III (destruction) – pain, ulceration, bleeding, infection; and stage IV (decompensation) – cardiac failure.

Arteriovenous malformations are usually present at birth but commonly manifest in Childhood or adolescence.³ Their size can increase rapidly secondary to infection, trauma, ligation, attempted excision or via hormonal influences such as during pregnancy and puberty. ⁴ If the AVM is small and asymptomatic, no treatment is required, especially in children. For a symptomatic AVM, complete excision with prior embolisation is the treatment of choice.⁸ Surgical ligation of proximal feeding vessels should be avoided as it not only aggravates the lesion by establishing new collaterals but also precludes later embolisation.⁹ Proximal embolisation also leads to failure for the same reasons.¹⁰ Embolisation alone can be used for palliation of lesions located in difficult-to-approach areas or very close to vital structures.⁹ In such cases, complications like stroke, cranial nerve palsy, and blindness can occur.¹¹ Total resection which requires a wide-field resection of all the involved tissue is necessary to prevent recurrence, however, cosmetic and functional issues might limit

The extent to which tissue can be removed Partial excision usually leads to rapid recurrence so in these cases the remaining AVM tissue must be obliterated using intravascular embolisation.¹²

Conclision-

Auricular AVMs are rare entities. We emphasize the role of colour Doppler sonography, CT& CT Angiography In the management of such cases. Embolisation followed by a wide excision and repair during the same procedure is the treatment of choice.

References-

1. Pham TH, Wong BJ, Allison G. A large arteriovenous malformation of the external ear in an adult: report of a case and approach to management. *Laryngoscope* 2001 ;111: 1390-4.
2. Seccia A, Salgarello M, Farallo E, Falappa PG. Combined radiological and surgical treatment of arteriovenous malformations of the head and neck. *Ann Plast Surg* 1999 ;43:359-66
3. Boyd JB, Mulliken JB, Kaban LB, Upton J 3rd, Murray JE. Skeletal changes associated with vascular malformations. *Plast Reconstr Surg* 1984;74 :789-97.
4. Svendsen PA, Wikholm G, Fogdestam I, Anniko M, Mendel L. Direct puncture of large arteriovenous malformations in head and neck for embolisation and subsequent reconstructive surgery. *ScandJ Plast Reconstr Surg Head Surg* 1994;28: 131-5.
5. Matsushige T, Kiya K, Sato H, Mizoue T, Kagawa K, Araki H. Arteriovenous malformation of the scalp: case report and review of the literature. *Surg Neurol* 2004;62 :253-9.
6. Demuth RJ, Miller SH, Keller F. Complications of embolization treatment for problem cavernous hemangiomas. *Ann Plast Surg* 1984 ; 13:135-44.
7. Persky MS. Congenital vascular lesions of the head and neck. *Laryngoscope* 1986;96: 1002-15