



Case Report

Rare Case of Mirizzi Syndrome in a Normal Young Adult

Authors

Dr Vinaya K Ambore M.S.General Surgery, Dr Ali Zaid Anwar M.S. General Surgery, Dr Srinivas Ram (M.S.) General Surgery, Dr Pranav Mehrotra (M.S.)General Surgery, Dr Rahul Ashok Mishra (M.S.) General Surgery, Dr Avinash V Gonnade (M.S.) Dr Hemant Muktaram Jawale (M.S.) General Surgery, Dr Akshat Awdhesh Kumar Mishra (M.S.) General Surgery

Department of General Surgery, Grant Government Medical College and JJ Hospital, Mumbai

*Corresponding Author

Srinivas Ram

Email: srinivas1990seena@gmail.com, +918904044583, +919769914006

Mailing address: G.T. Hospital, L.T. Marg, fort Mumbai 400001, Maharashtra, India

Abstract

Mirizzi Syndrome not a cup of tea.

It is defined as common hepatic duct obstruction/common bile duct caused by extrinsic compression from an impacted stone in the cystic duct or infundibulum of the gallbladder or by/or inflammation by impacted gallstone.

Mirizzi syndrome is usually seen in patients of middle age having a range of symptoms from no symptoms to severe cholangitis. As being difficult to diagnose preoperatively, it had lead to damage to the common bile duct intraoperatively during laparoscopic surgery.

Hence to diagnose a patient with mirizzi syndrome has been a challenging task from all times. It is difficult to manage even after having availability of many modalities to diagnose that is Ultrasound, Computed tomography, Magnetic Resonance Cholangio Pancreatography and Endoscopic Retrograde cholangiopancreatography.

The syndrome has been diagnosed many of the times intraoperatively.

Keywords: *Mirizzi syndrome , young adult.*

Introduction

Mirizzi syndrome was first described by Kehr and Ruge in 1905, they published case of biliary obstruction by gall bladder stone. Pablo Mirizzi (1893-1963) a surgeon in Cordoba, Argentina had first described and analysed external compression biliary duct by stone in GB and CBD and leading

operative complication and then this condition was named as Mirizzi Syndrome.

It is a condition in which there is an external compression due to a single or multiple impacted stones in cystic duct or Hartmann's pouch leads to dilatation in proximal duct leading to pressure necrosis of common bile duct resulting in a fistula formation. Mirizzi Syndrome one of rare disorder

ranging from asymptomatic obstruction to obstructive jaundice, fistula, severe cholangitis.

In most of the cases presenting symptoms are most likely similar to cholecystitis but most of them are confused with obstructing conditions such as common bile duct stones and ascending cholangitis due to the presence of jaundice.

Preoperative diagnosis is often difficult and usually most of the time it is missed, however successful pre-operative diagnosis of Mirizzi syndrome requires clinical correlation, high index of suspicion, imaging and endoscopic methods to avoid bile duct injury as the risk of bile duct injury is high if pre-operative diagnosis is not done.

Case Report

A young 19 year old female brought by relatives to tertiary care centre with complaints of intermittent pain in abdomen more in right hypochondrium and epigastric region since 6 months, having general condition of the patient as moderate and vitally stable, with per abdomen findings of tenderness at right hypochondrium and epigastric region. Lab investigation were as follows white blood cells - 12000/cu mm, Total bilirubin -0.5mg%, Serum glutamic oxalacetic transaminase -14U/l, serum glutamic pyruvic transaminase-17U/l, Alkaline Phosphatase 88 u/l.

Ultrasound was suggestive of cholelithiasis without cholecystitis and dilated common bile duct due to some distal biliary obstruction.

Computed tomography suggestive of- Dilated gall bladder and cystic duct with moderate dilatation of central bilateral intrahepatic biliary radical.

Magnetic resonance cholangiopancreatography was done –

(A) Multiple calculi in gall bladder and cystic duct with compression of common hepatic duct by calculus at the medial, low insertion of cystic duct and resultant upstream dilation of common hepatic duct and moderate central intra hepatic biliary radical dilation.

(B) Mildly dilated distal common bile duct (distal to cystic duct and common hepatic confluence) and prominent main pancreatic duct in

its entire course with ampullary narrowing and no obvious mass lesion seen.

Due to dilatation of common hepatic duct, endoscopic retrograde cholangiopancreatography with stenting was done and cholecystectomy was advised. Post endoscopic cholangiopancreatography patient was monitored and the pain had relieved and patient was discharged with follow up after 4 weeks for cholecystectomy.

After 4 weeks ultrasound target gall bladder scan was done suggestive of cholelithiasis without cholecystitis, dilated common bile duct with mild central intra hepatic biliary radical dilation, common bile duct stent in situ.

Patient was posted for Laparoscopic cholecystectomy. Patient was diagnosed as Mirizzi Syndrome intraoperatively. Gall bladder was sent for histopathology, no immediate postoperative complication seen, subhepatic drain removed on day 3, postoperative day 6 patient was discharged and was vitally stable. Postoperative ultrasound suggestive of – Cholecystectomy done, common bile duct stent in situ, common bile duct not dilated, rest abdomen normal. After 2 and half months stent removal was done of common bile duct.

Discussion

Gallstones occur when the substances in the bile reach their maximum limits of solubility. As bile gets concentrated in the gallbladder, it becomes supersaturated with the substances in bile, which in latter time precipitate into small tiny crystals. These crystals gets stuck in the gallbladder mucus, forming into gallbladder sludge. Over the passage of time, those tiny crystals progress in size and form large and/or multiple stones. These gallstones may cause symptoms of cholecystitis, but if they gets stuck/ embedded in a Hartman's pouch, they can cause additional feature of jaundice. As this condition progresses they can develop internal fistulas from the gallbladder into the common bile duct, common hepatic duct and the duodenum.

As described above Mirizzi syndrome is condition in which there is obstruction of CBD/CHD by

external compression by stone in cystic duct or infundibulum of gall bladder. Causing various symptoms ranging from no symptoms to severe cholangitis which is usually seen in middle aged people.

Incidence of Mirizzi syndrome is around 0.7 – 3 % in adult middle age who were diagnosed and had managed surgically

Incidence of Mirizzi syndrome in young adult is very rare.

Grading system has been developed to categorize the various stages of Mirizzi syndrome.

Type I: External compression of the common duct because of a stone impacted at the neck of the gall bladder or at the Hartmann's pouch

Type II: Chole-cysto-biliary fistula involving less than one third of the circumference of the common duct.

Type III: Chole-cysto-biliary fistula that involves up to two thirds of its circumference.

Type IV: Chole-cysto-biliary fistula with complete destruction of the entire wall of the common duct.

In our case a 19 years old young female presented with complaints of pain in abdomen and her ultrasound suggestive of gall bladder calculi with dilated common bile duct. Computed tomography suggestive of dilated gall bladder and cystic duct (with lower common bile duct insertion of cystic duct) with moderate central bilateral intra hepatic biliary radical.

Magnetic resonance cholangiopancreatography suggestive of lower insertion of cystic duct and calculi in cystic duct that compressing common bile duct results in dilatation of common bile duct (figure 1 and 2).

First we managed patient with endoscopic resonance cholangiopancreatography, endoscopic resonance cholangiopancreatography suggestive of dilated common hepatic duct, common bile duct with suspicious narrowing at mid common bile duct then the patient was planned for laparoscopic interval cholecystectomy. After 4 weeks patient posted for laparoscopic cholecystectomy postoperative condition was uneventful and did

postoperative ultrasound suggested normal study and managed successfully.

The use of laparoscopic surgery for the treatment of Mirizzi syndrome is considered to be controversial due to the technical difficulty^[7]. Laparoscopic surgery for mirizzi syndrome is reported to be associated with a high risk of conversion to open surgery (41%), complications (16%) and reoperation (5%)^[6].

However, in recent years, laparoscopic surgery has steadily progressed and advanced techniques have been applied in the pre-operative diagnosis and treatment of various types of disease.

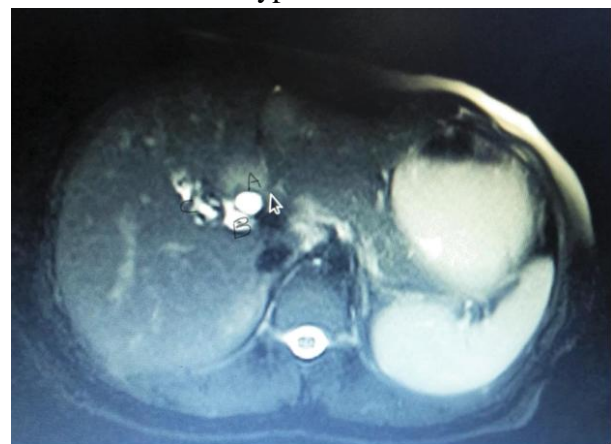


Figure 1 MRCP horizontal view.

A) Dilated proximal common bile duct. B) Cystic duct with stone compressing common bile duct. C) Gall bladder with multiple calculi.

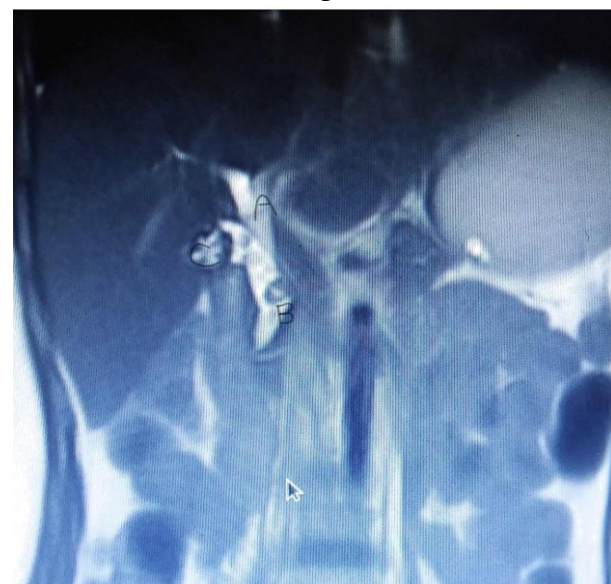

Figure 2 sagittal view .A) common hepatic duct proximal dilated part .B)cystic duct with stone compressing common bile duct .C)gallbladder with multiple stones.

The preferred surgery for mirizzi is laparotomy because good visualization and fast but the thing is more invasive, high morbidity, high complication rate and longer duration hospital stay.

Type I can managed by total cholecystectomy, partial cholecystectomy in case of inflamed gall bladder, if duct injury that can be managed by Roux-en -Y hepaticojejunostomy⁽¹¹⁾, in some cases T -tube insertion to decompress and to prevent bile leakage in doubtful tissue repair.

Type II and selected cases of type III managed by choledochoplasty and choledoch -enteric anastomosis⁽¹²⁻¹⁴⁾.

selected cases of type III and type IV managed by Roux en Y hepaticojejunostomy with laparotomy is safest technique. now advance laparoscopic ,endoscopic or robotic assisted surgery has good outcome in management of mirizzi syndrome.

Conclusion

Mirizzi Syndrome which is considered to be a disease of middle age people presented in a young person with symptoms of acute cholecystitis and dilated common bile duct which didn't resolved even after endoscopic retrograde cholangiopancreatography and Stenting of the common bile duct followed by laparoscopic cholecystectomy, for better outcome of the laparoscopic surgery and to reduce risk of the intra-operative duct injury, high suspicion should be present for pre-operative diagnosis of the mirizzi syndrome should be done.

Reference

1. Kumar A, Senthil G, Prakash A, Behari A, Singh R, Kapoor V, et al. Mirizzi's syndrome: lessons learnt from 169 patients at a single center. *Korean J Hepatobiliary Pancreat Surg* 2016;20:17–22. [PMC free article] [PubMed]
2. Beltran MA. Mirizzi syndrome: history, current knowledge and proposal of a simplified classification. *World J Gastroenterol* 2012;18:4639–50. [PMC free article] [PubMed]
3. Antoniou SA, Antoniou GA, Makridis C. Laparoscopic treatment of Mirizzi syndrome: a systematic review. *Surg Endosc* 2010;24:33–9. [PubMed]
4. Beltran MA, Csendes A, Cruces KS. The relationship of Mirizzi syndrome and cholecystoenteric fistula: validation of a modified classification. *World J Surg* 2008;32:2237–43. [PubMed]
5. Starling JR, Matallana RH. Benign mechanical obstruction of the common hepatic duct (Mirizzi syndrome). *Surgery* 1980;88:737–40. [PubMed]
6. Yonetci N, Kutluana U, Yilmaz M, et al. The incidence of Mirizzi syndrome in patients undergoing endoscopic retrograde cholangiopancreatography. *Hepatobiliary Pancreat Dis Int* 2008;7:520–4. [PubMed]
7. Rust KR, Clancy TV, Warren G, Mertesdorf J, Maxwell JG. Mirizzi's syndrome: a contraindication to coelioscopic cholecystectomy. *J Laparoendosc Surg* 1991;1:133–7. [PubMed]
8. Noshiro H, Yoda Y, Hiraki M, Kono H, Miyake S, Uchiyama A, et al. Survival outcomes of consecutive patients with three-staged thoracoscopic esophagectomy. *Dis Esophagus* 2016;29:1090–9. [PubMed]
9. Piccinni G, Sciusco A, De Luca GM, Gurrado A, Pasculli A, Testini M. Minimally invasive treatment of Mirizzi's syndrome: is there a safe way? Report of a case series. *Ann Hepatol* 2014;13:558–64. [PubMed]
10. Kasuya K, Itoi T, Matsudo T, Kyo B, Endo Y, Ikeda T, et al. Reconsideration of laparoscopic cholecystectomy. *ISRN Surg* 2011;2011:827465. [PMC free article] [PubMed]
11. Kulkarni SS, Hotta M, Sher L, et al. Complicated gallstone disease: diagnosis and management of Mirizzi syndrome. *Surg Endosc* 2017;31:2215–22]
12. Cui Y, Liu Y, Li Z, et al. Appraisal of diagnosis and surgical approach for Mirizzi syndrome. *ANZ J Surg* 2012;82:708–13.[22]

13. Lledó JB, Barber SM, Ibañez JC, et al. Update on the diagnosis and treatment of mirizzi syndrome in laparoscopic era: our experience in 7 years. *Surg Laparosc Endosc Percutan Tech* 2014;24:495–501
14. Piccinni G, Sciusco A, De Luca GM, et al. Minimally invasive treatment of Mirizzi's syndrome: is there a safe way? Report of a case series. *Ann Hepatol* 2014;13:558–64.