



Original Research Article

A Review of Spectrum of Breast Lesions in a Tertiary Care Centre: A Retrospective Study

Authors

Jyoti Sharma¹, Hem Chander Pandey^{2*}

¹MBBS, MD (Pathology), Pathologist, Working in Armed Forces, India

Email: drsharma1212@gmail.com

²MBBS, MS (Surgery), Surgeon, Working in Armed Forces, India

Corresponding Author

Hem Chander Pandey

S-63 A, Pandav Nagar, Near Mother Dairy, Delhi-110092, India

Email: pandeyhc.delhi@gmail.com, Mob; 09599927775

Abstract

Background: Breast lesions comprise a family of heterogeneous entities with variable patterns of presentation, morphology and clinical behaviour. The majority of breast lesions are traditionally classified into benign and malignant conditions and their behaviour can, in the vast majority of cases, be predicted with a reasonable degree of accuracy.

Materials and Methods: In this study, 30 cases of benign breast lesions and 50 cases of carcinoma breast were studied.

Results: Fibroadenoma was the most common benign lesion found, being most common in third decade of life, followed by fibroadenosis. In the carcinoma group, most common histological type was infiltrating duct carcinoma with maximum cases belonging to the age group of 41-60 years. Both benign breast lesions and carcinoma breast were distributed more in left breast than in right breast.

Keywords: Breast, Benign, Carcinoma.

Introduction

Breast lesions comprise a family of heterogeneous entities with variable patterns of presentation, morphology and clinical behaviour. The majority of breast lesions are traditionally classified into benign and malignant conditions and their behaviour can, in the vast majority of cases, be predicted with a reasonable degree of accuracy.¹ Cancer of breast has emerged as the leading site of cancer in most urban populations. It is rapidly

replacing cancer cervix as the most important cancer in women in India.² India faces a potential breast cancer epidemic over the next decade as women adopt western lifestyle by marrying and bearing children later in life.³ The purpose of this study is to document the incidence of various histopathological types of nonmalignant and malignant breast lesions.

Material and Methods

The present study was conducted in Department of Pathology, Pt. B. D. Sharma, University of Health Sciences, Rohtak (Haryana). Thirty lumpectomy specimens of benign mammary disease and 50 modified radical mastectomy specimens of carcinoma breast from females of all age groups, comprised the study material. Benign cases did not include inflammatory lesions of the breasts, such as tuberculosis and acute breast abscess. Cases with breast malignancies other than carcinoma (eg. lymphoma, sarcoma, stromal tumour etc) were excluded from the study. Specimen were fixed and processed by routine histological technique for paraffin embedding. Histopathological diagnosis was established on routine haematoxylin and eosin stained section, special histochemical stains were applied wherever necessary.

Observations

Fibroadenoma was the most common benign breast lesion (43.4% cases). Twelve cases showed fibroadenosis, two (6.7%) showed fibroadenomatoid hyperplasia, one (3.3%) showed intraductal papilloma, one (3.3%) showed tubular adenoma and one (3.3%) showed fibrocystic disease. The majority of benign lesions (n=22; 73.4%) were found in patients upto 40 years of age out of which 53.4% (n=16) were in patients upto 30 years of age. Only 3 cases (10%) were in the age group of 41-50 years, and 5 (16.6%) were found in a female above 50 years of age. (Tab.1) The minimum and maximum ages recorded were 16 and 62 years respectively. The average age at diagnosis was 33.2 years.

Table: 1 Histomorphological Spectrum of Benign Breast Lesions (n=30)

TYPE OF LESION	AGE IN YEARS				
	0-20	21-30	31-40	41-50	>50
	No.(%)	No.(%)	No.(%)	No.(%)	No.(%)
Fibroadenoma (n=13, 43.4%)	7(53.8%)	3(23.1%)	3(23.1%)	0 (0%)	0 (0%)
Tubular adenoma (n=1, 3.3%)	1 (100%)	0 (0%)	0 (0%)	0 (0%)	0 (0%)
Intraductal papilloma (n=1, 3.3%)	0 (0%)	0 (0%)	0 (0%)	0 (0%)	1 (100%)
Adjacent breast tissue showing Fibroadenosis (n=12, 40%)	0 (0%)	2(16.7%)	3 (25%)	3 (25%)	4(33.3%)
Fibroadenomatoid hyperplasia (n=2, 6.7%)	0 (0%)	2 (100%)	0 (0%)	0 (0%)	0 (0%)
Fibrocystic disease (n=1, 3.3%)	0 (0%)	1 (100%)	0 (0%)	0 (0%)	0 (0%)
Total (n=30)	8(26.7%)	8(26.7%)	6 (20%)	3 (10%)	5(16.6%)

Table: 2 Histomorphological Spectrum of Carcinoma Breast (n=50)

TYPE OF LESION	AGE IN YEARS						
	0-20	21-30	31-40	41-50	51-60	61-70	>70
	No.(%)	No.(%)	No.(%)	No.(%)	No.(%)	No.(%)	No.(%)
IDC-NOS (n=48,96%)	0(0%)	3(6.3%)	8(16.7%)	15(31.2%)	15(31.2%)	5(10.4%)	2(4.2%)
Medullary Ca (n=1,2%)	0(0%)	0(0%)	1(100%)	0(0%)	0(0%)	0(0%)	0(0%)
MetaplasticCa (n=1,2%)	0(0%)	0(0%)	0(0%)	1(100%)	0(0%)	0(0%)	0(0%)
Total (n=50)	0(0%)	3(6%)	9(18%)	16(32%)	15(30%)	5(10%)	2(4%)

In the carcinoma group, the youngest patient was 23 years old and the oldest was 78 years of age, with the average age at presentation being 49.5 years (c.f. benign 33.2 years). Out of 50 cases of carcinoma breast, the maximum (n=31; 62%) belonged to the age group of 41-60 years. No case was seen below the age of 20 years. Only three cases (6%) were in the age group of 21-30 years

and two cases (4%) were seen above the age of 70 years. Twelve cases (24%) of breast cancer patients were up to 40 years of age whereas the majority (n=38; 76%) of patients were in the older age group i.e., above 40 years of age. (Tab.2)

All the cases of breast cancer were present in females. Fifty two percent (n=26) cases were seen

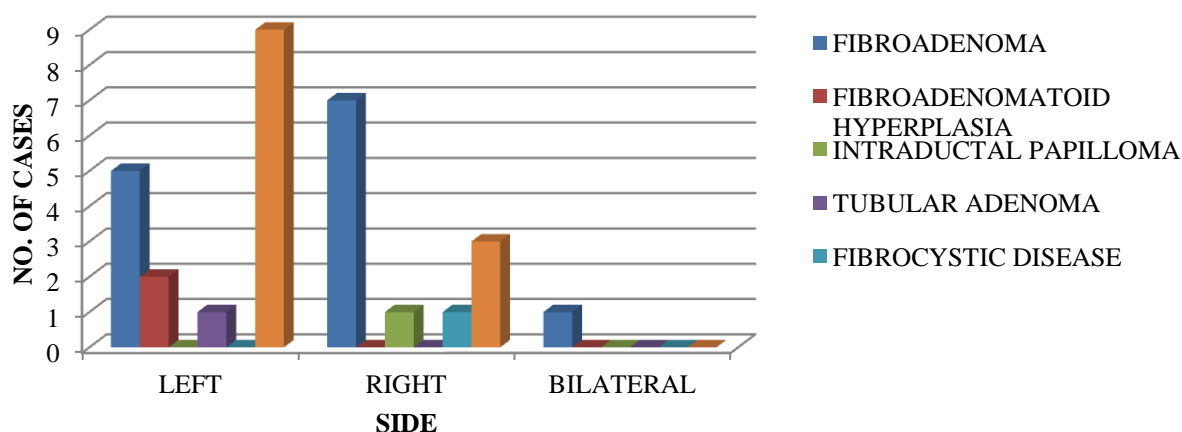
in premenopausal while remaining 48 % (n=24) were seen in postmenopausal patients.

The most common histological type of breast carcinoma was infiltrating duct carcinoma – not otherwise specified (IDC-NOS) constituting 96% cases. The only other types encountered were a one case (4%) each of medullary and metaplastic carcinoma. (Tab.2)

Seventeen cases of benign breast lesions (56.7%) occurred in the left breast, with most of the remainder (40%) occurring in the right breast. Only a single case (3.3%) showed bilateral

distribution of lesions. Fibroadenoma, the most common benign breast lesion, involved the right breast in 53.8% (7 of 13) cases, was bilateral in 7.7% (1 case), and involved the left breast in 38.5% (5 of 13) cases. Fibroadenosis involved the left breast in 75% (9 of 12) cases and right breast in 25% (3 of 12) cases. All cases of fibroadenomatoid hyperplasia and the tubular adenoma involved the left breast only. On the other hand, the only cases of intraductal papilloma and fibrocystic disease involved the right breast only. (Fig.1)

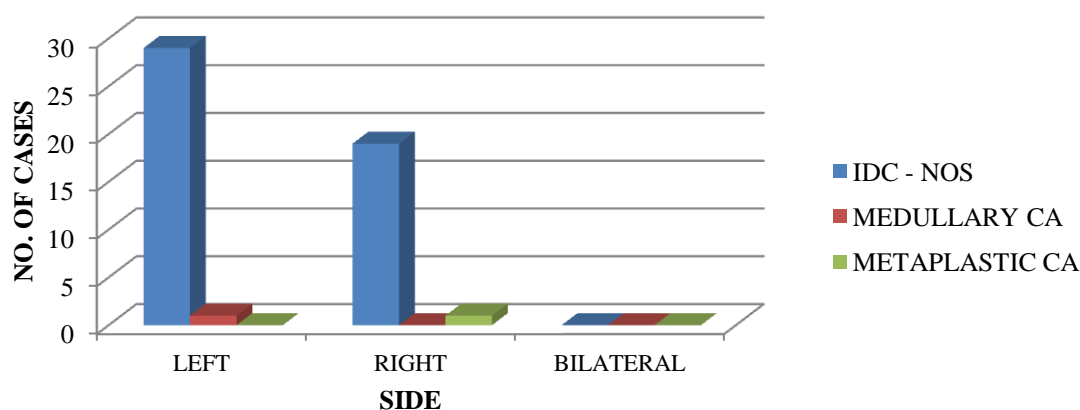
FIGURE 1 : SIDE DISTRIBUTION IN BENIGN BREAST LESIONS



Cases of carcinoma breast were distributed more in left breast (n=30; 60%) than in right breast (n=20; 40%). (Tab. 4 & Fig.4). Infiltrating duct carcinoma, the most common tumor type (n=48; 96%) involved left breast in 60.4% (29 of 48)

cases and the remainder 39.4% (19 of 48) cases with right side distribution. The only case of medullary carcinoma involved left breast and the metaplastic carcinoma (one case) involved right breast only. (Fig.2)

FIGURE 2 : SIDE DISTRIBUTION IN CARCINOMA BREAST



Discussion

Fibroadenomas comprised the most common benign proliferative lesion amongst specimens of benign breast lesions. Fibrocystic and other benign lesions like fibroadenomatoid hyperplasia, fibroadenosis etc. are generally treated medically, respond well to hormonal treatment and less frequently require excision.

The majority of benign lesions were found in patients upto 40 years of age out of which 53.4% were in patients upto 30 years of age. The minimum and maximum ages recorded were 16 and 62 years respectively. The average age at diagnosis was 33.2 years.

In the carcinoma group, most common histological type was infiltrating duct carcinoma. The youngest patient was 23 years old and the oldest was 78 years of age, with the average age at presentation being 49.5 years (c.f. benign 33.2 years).

Out of 50 cases of carcinoma breast, the maximum cases belonged to the age group of 41-60 years. No case was seen below the age of 20 years. Only two cases (4%) were seen above the age of 70 years, probably due to lesser number of patient population in the age groups and ignorance and non seeking of medical advice in the age group might be additional contributory factors. In India, the percentage rate of elderly above 60 years constitutes only 7.7 % of population.⁴ The difference in age distribution of benign breast disease and carcinoma breast is in accordance with literature.⁵

Cases of carcinoma breast were distributed more in left breast than in right breast. This is in agreement to the study by Ekbom et al who reported that the overall incidence of preinvasive and invasive cancer was higher in the left than in the right among both women and men. The risk differential between the left and the right breast has not been explained satisfactorily yet, although it is well established that the left breast is on average slightly larger than the right.⁶

To conclude, the most common type of benign breast tumor found was fibroadenoma, found most common in the third decade of life, followed by fibroadenosis. Benign breast masses and carcinoma breast were more common in the left breast than in the right. In present study the age and side distribution was found in accordance with the literature.

References

1. Rakha EA, Badve S, Eusebi V, Reis-Filho JS, Fox SB, Dabbs DJ et al. Breast lesions of uncertain malignant nature and limited metastatic potential: Proposals to improve their recognition and clinical management. *Histopathology* 2016 ; 68 (1): 45–56.
2. Nandakumar A, Ramnath T, Chaturvedi M. The magnitude of cancer breast in India: a summary. *Indian J SurgOncol* 2009;1:8-9.
3. Bagchi S. Breast cancer rises in India. *CMAJ* 2008;179:26-7.
4. Ingle GK, Nath A. Geriatric Health in India: concerns and solutions. *Indian J Community Med* 2008;33:214-8.
5. P Lipponen. Apoptosis in breast cancer: relationship with other pathological parameters. *EndocrRelat Cancer* 1999;6:13-6.
6. Ekbom A, Adami HO, Trichopoulos D, Lambe M, Hsieh C, Ponten J. *Cancer Cause Control* 1994;5:510-6.