



Retrograde Urethrography In Urethral Stricture – Is It Still Relevant

Authors

Dr. N.L.N. Moorthy¹, Dr. V.Sudhakar², Dr. N. Anil Kumar³, Dr. D.Mahesh Chander⁴

^{1,4}Professor, Department of Radiodiagnosis, Gandhi Hospital, Secunderabad, Telangana, 500003

²Resident, Department of Radiodiagnosis, Gandhi Hospital, Secunderabad, Telangana, 500003

³Assistant Professor, Department of Radiodiagnosis, Gandhi Hospital, Secunderabad, Telangana, 500003

Corresponding Author

Dr.V.Sudhakar

Room No-1, PG Boys Hostel, Gandhi Hospital, Musheerabad, Secunderabad, Telanagana, 500003

Email: vengalasudhambbs@gmail.com. Mobile no. 9676866530

ABSTRACT

Urethral stricture is one of the most frequent health problems affecting the adult population causing repeated urinary tract symptoms. Strictures can be following trauma or infection. Retrograde urethrography is considered as the gold standard for evaluation of stricture urethra. Voiding cystourethrography and Sonourethrography helps in improving the imaging of urethral diseases. In the present study we present the profile of radiological features in 478 cases of stricture urethra based on retrograde urethrography with clinical correlation.

KEY WORDS: *Urethral stricture, Retrogradeurethrography, Trauma*

INTRODUCTION

The male urethra is divided into anterior and posterior portions and the anterior urethra is classified into penile and bulbar urethra and the posterior into prostatic and membranous urethra. The term urethral stricture refers to anterior urethral disease as a scarring process involving spongy erectile tissue of corpus spongiosum^[1]. In comparison with anterior urethral strictures, posterior urethral strictures are not true strictures, but an obliterative process due to distraction by trauma or following surgical procedures. Most of the anterior urethral strictures are due to inflammation (gonococcal urethritis, balanitis xerotica obliterans) and traumatic or after

instrumentation. Posterior urethral strictures are mostly distraction or disruption following trauma or surgery. These patients usually present with obstructive voiding symptoms, urinary tract infection and urinary retention. Evaluation of these patients is to know the length, location, depth and density of the stricture. The various methods used to assess the stricture include retrograde urethrography, sonourethrography and urethroscopy.

In the present study retrograde urethrography was performed in 478 patients with clinical features of stricture and the findings were evaluated in detail and the results discussed.

MATERIALS AND METHODS

In a study period of one year, April 2014 to March 2015, 478 patients with clinical symptoms suggesting stricture urethra were undergone retrograde urethrography in the department, of them 192 cases were normal. In the remaining 286 patients, radiological findings were evaluated in detail. Based on the location, the strictures were divided into bulbar, bulbomembranous, membranous, anterior penile, penobulbar and multiple strictures. The strictures are either complete or partial (fig.1-4). Bulbar segment is the commonest site of stricture in our study (160 out of 286) followed by bulbomembranous segment. Multiple penile strictures were found in 24 patients.(fig.5). In most of the cases the strictures were post traumatic. All the patients have undergone various surgical procedures including visual internal urethrotomy, end to end anastomosis, buccal mucosal augmentation urethroplasty etc.

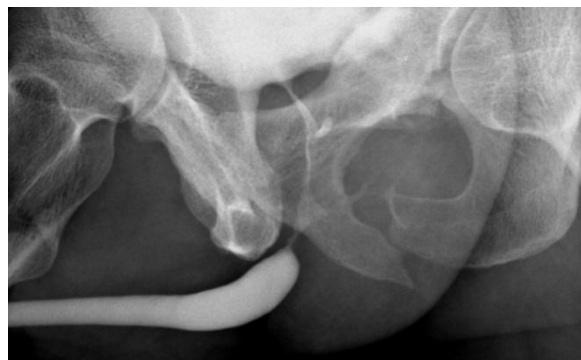

Fig 3.post-traumatic stricture bulbar urethra

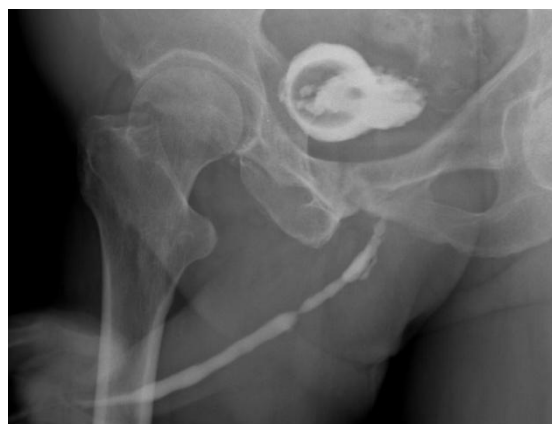

Fig 4.multiple urethral strictures

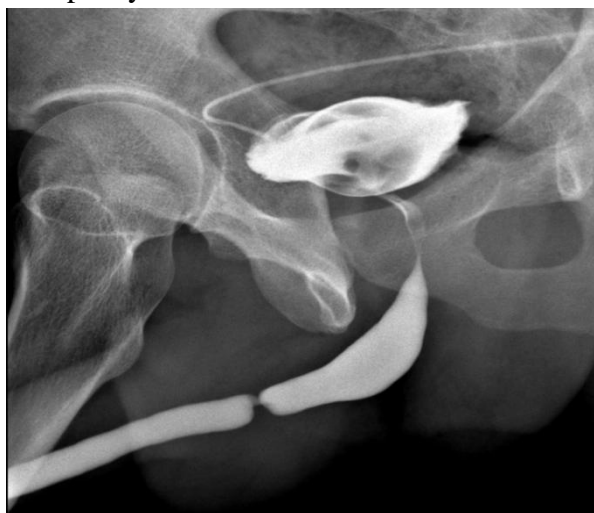

Fig 1.short segment stricture penobulbar urethra

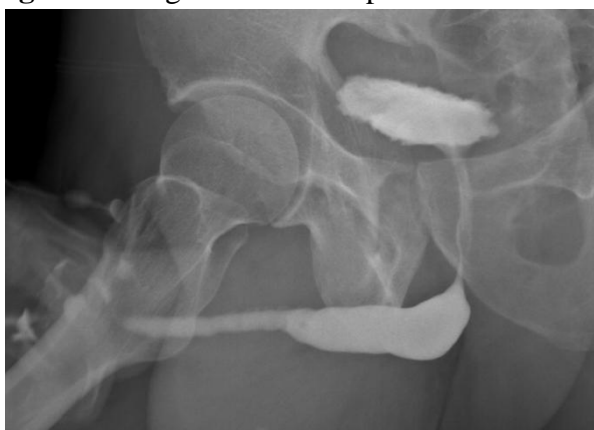

Fig 2. long segment stricture anterior urethra

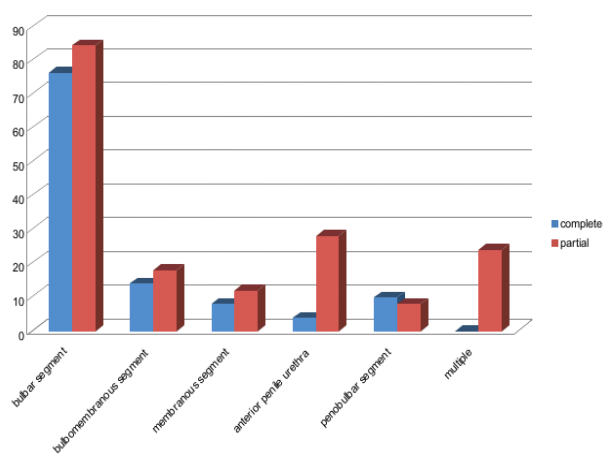


Fig 5.percentage of stricture urethra based on location

DISCUSSION

RGU is considered as the gold standard in the evaluation of urethral stricture. RGU defines the location, length, number and degree of stricture and associated periurethral abnormalities [2].

Sensitivity and specificity of RGU varies between 75-100% and 72-97% respectively [3]. RGU not only provides the direct evidence of stricture, it also indicates the presence of associated fistula

and false passage. In cases of posterior urethral strictures, RGU gives the necessary information about the degree of urethral disruption, measurement of bulbar urethra which is very critical in the management of stricture in trauma. VCUG is a better method in the evaluation of posterior urethra, especially in assessing the bladder neck and prostatic urethra. Sonourethrography is considered as an adjuvant in case of anterior urethral stricture and in assessment of associated spongiofibrosis, as it provides a three dimensional anatomical location of stricture. Sonourethrography is also used in some centers as an intraoperative method in the evaluation of strictures. Comparative evaluation of sonourethrography and RGU in cases of stricture urethra, concluding that sonourethrography has more sensitivity and specificity than RGU and also reported that besides stricture sonourethrography is more superior in detecting mucosal, submucosal, periurethral soft tissue abnormalities and spongiofibrosis^[4,5,6]. Mihir evaluated the clinical profile recurrence rate following surgery in 30 patients based on RGU^[7]. In the present study all patients who have undergone surgery following RGU were followed up for a period of 3 months and the recurrence rate was not significant. We concluded that RGU is the best and easily available investigation in patient with stricture urethra.

CONCLUSION

RGU is still the most sensitive investigation in the diagnosis and management of stricture urethra.

REFERENCES

1. CAMPBELL-WALSH. Surgery of the penis and urethra, in Gerald H.Jordan, Kurt A.McCammon(eds): UROLOGY, volume 1, 10th edition, Philadelphia, Saunders 2012;pp 967-971.
2. Akira Kawashima, Carl M Sandler, Neil F.Wasserman, Andrew F.LeRoy, Bernard F.King, Stanford M.Goldman. Imaging of

Urethral disease : A Pictorial Review. *RadioGraphics* 2004;24:S195-216.

3. Maciejewski C, Rourke K. Imaging of urethral stricture disease. *Trans AndrolUrol* 2015;4(1):2-9.doi:10.3978/j.issn.2223-4683.2015.02.0
4. Sumanta Kumar Mandal et al. Sonourethrography in the evaluation of anterior urethral stricture:correlation with retrograde urethrography in male. *Int J Pharm Biomed Res* 2012; 3(2):77-80.
5. Anand Hatgaonkar. A Comparative Study of Sonourethrography and Retrograde Urethrography in Evaluation of Anterior Male Urethral Strictures. *Int J Sci Stud.* 2014;2(2):5-12.
6. Akshara Gupta, Achal Gupta, Kuber Sharma. Comparative evaluation of sonourethrography and retrograde urethrography in detection of urethral strictures. *J of Evolution of Med and Dent Sci* 2015 march;4(18):3026-3031.doi:10.14260/jemds/2015/440.
7. Dr.Mihir Birnale, Dr.Suhas Taralekar, Dr.Ibrahim Kothawala. Clinical Profile and Management of Urethral Strictures in Adults. *Indian Journal of Applied Research* 2015 march;5(3):459-461.