



Artisan Phakic IOL in Myopia – How Useful Is It?

Authors

**Dr. Vikas Mahatme¹, Dr. Sudha Sutaria², Dr. Atul Borkar³, Dr. Chitra Pande⁴,
Dr. Nikhilesh Wairagade⁵**

¹Founder Medical Director – Dept of Ophthalmology, Mahatme Eye Bank Eye Hospital, Nagpur

²Professor and Senior Consultant –Dept of Ophthalmology, Mahatme Eye Bank Eye Hospital, Nagpur

³Consultant Ophthalmologist, Nagpur (Private Practice)

⁴Senior Consultant –Dept of Ophthalmology, Mahatme Eye Bank Eye Hospital, Nagpur, India

⁵Senior Consultant –Dept of Ophthalmology, Mahatme Eye Bank Eye Hospital, Nagpur, India

Abstract

Artisan Phakic IOL is found to be effective and predictable in treating high myopia. The present study was aimed at determining the efficacy, safety, predictability and visual outcome of Phakic Artisan IOL in high myopia. This retrospective and prospective study was conducted on 22 eyes of 18 patients between October 2004 and January 2006 at Mahatme Eye Bank Eye Hospital, Nagpur, India. All of them underwent implantation of iris claw phakic IOL (Artisan) by the same surgeon. Although it is a difficult procedure to perform, our study showed that in experienced hands, there are minimal intraoperative and postoperative complications. The implantation of Phakic IOLs has been projected as an interesting alternative to corneal surgery for the correction of high refractive error. However further follow up is necessary to confirm its efficacy and to monitor long term complications and safety.

Key words: Artisan lens, Phakic Intra Ocular Lens (PIOL), ICL (Implantable Contact Lens), Anterior chamber IOL, Iris Claw IOL, Myopia, refractive surgery, Lasik, PRK, refraction, spherical equivalent (SE) refraction, BSCVA (Best surgically corrected visual acuity),

Introduction

Phakic IOL means any lens located between the corneal and the anterior surface of crystalline lens, which is left undisturbed inside the eye. Many potential advantages of phakic intra ocular lenses (PIOL) exist over conventional corneal refractive surgery to treat high myopia and hyperopia.

Unlike the case with most corneal refractive procedures and materials, that permanently alter corneal curvature and in some cases can be difficult to modify, phakic IOLs are potentially adjustable (via IOL exchange) and reversible (via removal of IOL), albeit with additional intraocular surgery¹. The surgical technique of phakic IOL

implantation being similar to methods used to insert standard IOLs, is already familiar with most of the ophthalmologists. Therefore there is no learning curve nor does it require additional equipment. The visual rehabilitation is faster since postoperative refraction stabilizes earlier than corneal procedures. Phakic IOLs also preserve patient's accommodative ability. This is an important advantage over clear lens extraction. PRK and LASIK restrict the correction of myopia up to -15 to -18.

However one must not forget that phakic IOL is an intraocular procedure. Design of the phakic IOL also poses new challenges. Phakic IOLs generally correct myopia above -12D to -30 D and hyperopia up to +12 D. Presently three types of phakic IOLs are available.

1. Anterior chamber angle supported phakic IOL – Nuvita MA 20, Phakic 6, Vivarte foldable IOL and Alcon angle supported phakic IOL; the last two have acrylic optic and foot plates.
2. Iris fixated anterior chamber IOLs – Artisan Lens
3. Posterior chamber phakic IOLs – Staar ICL(implantable contact lens) and PRL (phakic refractive lens)

Artisan lens, also called as Worst iris claw lens² is a PMMA nonfoldable lens centered over the pupil with special haptic called 'claws' that imbricate the anterior surface of the midperipheral iris at each side. It was originally designed by Worst and Fechner² in the late 1980s. Like the angle supported IOLs, the depths of the anterior chamber is critical in preoperative evaluation,

more so for negative lenses than convergent ones. Anterior chamber depth of 3.2 mm and endothelial count of greater than 2300/mm² are usually considered safe irrespective of IOLs to be implanted

In the present study we have used Artisan IOL of Alcon, total optic diameter was 5 mm.

Complications of anterior chamber phakic IOLs include endothelial cell loss, decentered IOLs, halos, glare, iris atrophy, pupillary block, cataract, iritis, glaucoma, cystic wounds.

The present study aimed at assessing efficacy, predictability and visual outcomes of Artisan Phakic IOL in high myopia. Figure 1 shows the design of Artisan IOL



Figure 1. Schematic of the Artisan aphakic lens.

Materials and Methods

This retrospective and prospective study was conducted on 22 eyes of 18 patients between October 2004 and January 2006 at Mahatme Eye Bank Eye Hospital, Nagpur, India after approval from ethics committee. All of them underwent implantation of iris claw phakic IOL (Artisan) by the same surgeon. Preoperative refractive error ranged from -14.75 to -29.5 D. Iris claw model IC585 (having 5mm optical diameter, overall diameter 8.5mm) was implanted. IOL power ranged from -12 to -22 D.

Inclusion criteria:

1. Age over 18 years
2. High Myopia > -10 D
3. Myopia with a variation in SE (spherical equivalent) refraction of < -0.5 in 12 months before surgery.
4. BSCVA (Best Spectacle Corrected Visual Acuity) of at least 6/60
5. Central anterior chamber depth of at least 3.00 mm or above
6. Problems with contact lens on wearing spectacles
7. Contraindication for laser in situ keratomileusis (LASIK) on the basis of pachymetric data or other corneal characteristics
8. No Uveitis
9. IOP < 20 mm Hg

Exclusion Criteria:

1. Previous corneal or intraocular surgery
2. Anterior segment pathological condition
3. Glaucoma
4. Pre-existing macular degeneration or retinopathy

Counselling of patients: This has significance as unrealistic expectations are the most common causes of dissatisfaction after refractive surgery. Care was taken to make patient understand that no refractive surgery is perfect and it may not be possible to achieve same quality of vision as with spectacles or contact lenses in all the cases. The risks of the procedure explained.

Preoperative evaluation :consisted of uncorrected visual acuity for both – distance and near; best spectacle corrected visual acuity, manifest and

cycloplegic refraction, slitlamp examination , applanation tonometry, keratometry, scotopic pupillary size, indirect ophthalmoscopy, central anterior chamber depth measurement with A scan biometry. A suspicious lesion was treated with laser or cryotherapy and in those patients surgery was postponed for 8 to 12 weeks.

Calculating power of Phakic IOL to be implanted : Van Der Heijde’s formula can be used.

$$P_{IOL} = \frac{1336}{\text{-----} - \text{ELP}} - \frac{1336}{\text{-----} - \text{ELP}}$$

$$\frac{1336}{K + Refc} - \frac{1336}{K}$$

Refc- refraction at corneal apex

K – averagekeratometry reading

ELP – Effective lens position in meters

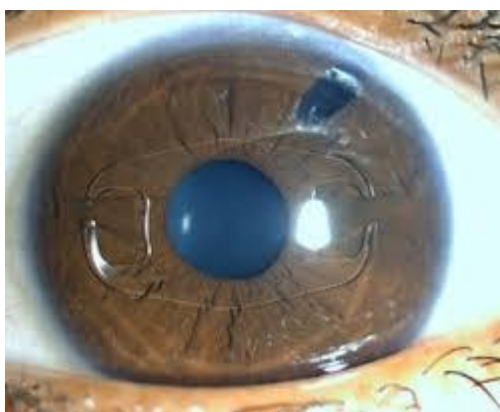ELP in meters is the difference between anterior chamber depth including corneal thickness (ACD) and distance between IOL and crystalline lens (around 0.8mm in Artisan, 0.6 mm in Baikoff ZB5M). However in our study, we didn’t use this formula. The IOL power was calculated from the spectacle refractive correction.For up to -15 D SE, about – 1D was deducted and for more than -15 D SE, about 10 to 15% SE was deducted for IOL power. Availability of required IOL was another problem. For example in one patient having SE refraction of -29.5, we had to use -22.0 D IOL which was the highest available IOL power then.

Surgical Procedure : Surgeries were performed by a single surgeon and the surgical protocol was the same in all cases. Antibiotic drops started 2 days prior to surgery. To achieve stable intraocular miosis, pilocarpine eye drops were instilled twice

1 hour prior to surgery. All procedures performed under peribulbar block.

Primary Surgical Procedure: After making a fornix based conjunctival flap from 10.30 to 1.30 O'clock, scleral tunnel was made at 12 O'clock. Lateral paracentesis in the cornea performed at 3 & 9 O'clock. Anterior chamber washed with acetylcholine and then filled with viscoelastic. The iris claw artisan lens was inserted through tunnel at 12 O'clock and rotated into a horizontal position. The lens haptic enclavated a fold of midperipheral iris stroma using an enclavation needle at 3 and 9 O'clock meridians to achieve perfect centration of the lens. While firmly holding the lens with forceps, first a temporal, midperipheral iris strip was enclaved with special needle or forceps and then a nasal hold of iris was gently pushed and caught by the claw. A peripheral surgical iridectomy was performed at 12 O'clock meridian to prevent pupillary block glaucoma. (see Figure 2.) All viscoelastic washed. Incision closed by suture. Subconjunctival Dexamethasone and gentamycin given.

Figure 2



Follow Up: patients examined on day 2, 15, 1 month, 3, 6, 12 months after surgery. Each postoperative examination included visual acuity, manifest and cycloplegic refraction, tonometry,

slit lamp examination, indirect ophthalmoscopy, visual acuity examination including safety index and efficacy index.

Observations:

The data was analysed by paired 't' test. The probability value of <0.05 was considered as statistically significant.

UCVA (uncorrected Visual Acuity): At 3 months postoperative visit, the mean UCVA was 0.260 ± 0.152 (range 0.05 to 0.66 i.e. 3/60 to 6/9). 3 patients (13.63%) had UCVA of 6/12 or better and 8 patients (36.36%) had UCVA of 6/18 or better.

BCVA (Best corrected visual acuity): The mean postoperative BCVA was 0.46 ± 0.242 (range 0.1 to 1.0 i.e. 6/60 to 6/6). 16 patients (72.72%) had improvement in BCVA; of which 13 (59.09%) had improvement of 2 or more lines in BCVA. 5 eyes (22.72%) maintained preoperative BCVA.

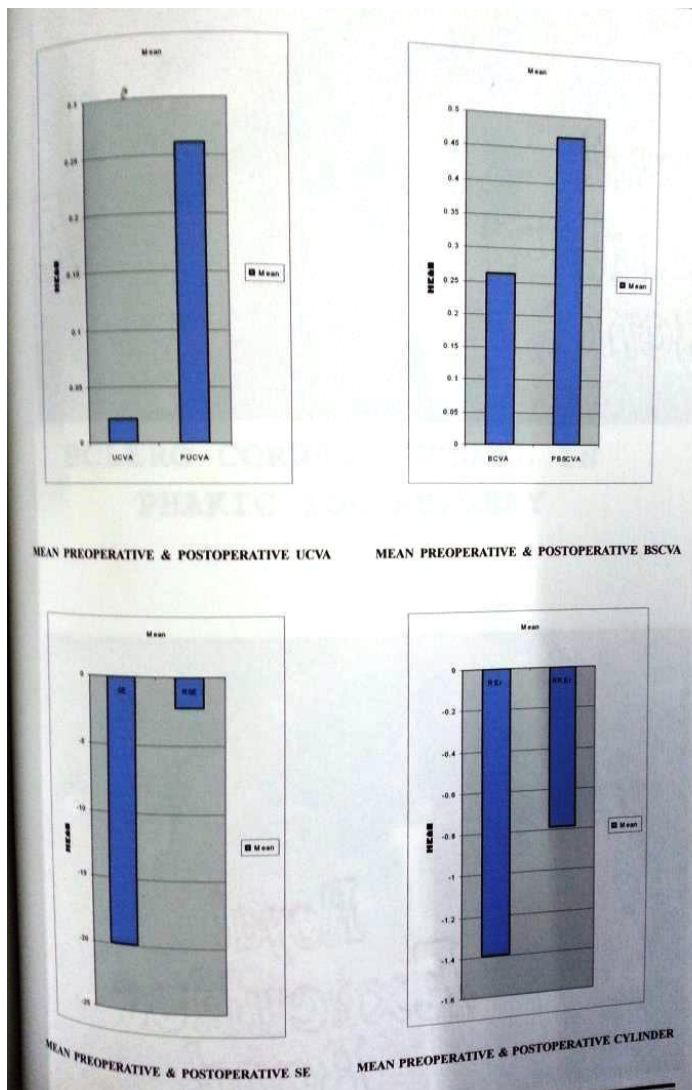
SE (Spherical Equivalent) Refraction: the mean postoperative SE refraction was -2.232 ± 2.418 (range $+0.5$ to 9.0 D); 9 patients (40.9%) had SE within ± 1.0 while 15 patients (68.18%) had SE within ± 2.0 D.

Cylinder: the mean postoperative cylinder was -0.784 ± 1.181 (range -2.5 to $+3.0$; P value not significant).

Safety Index: (ratio of mean postoperative BCVA to mean preoperative BCVA) was 1.786.

Efficacy Index: (ratio of mean postoperative UCVA to mean postoperative BCVA) was 0.992.

Figure 3 shows results.



Intraoperative Complications: Bleeding was observed in 3 eyes (9.09%); Difficulty in IOL centering or enclavation in 4 eyes (18.18%); Iris prolapse in 1 eye (4.5%).

Postoperative Complications: Raised IOP was seen in 6 eyes (27.27%) ; pigment dispersion in 4 eyes (18.18%). In 2 eyes (9.08%) developed a small paracentral anterior capsular opacification, which was detected at 15th postoperative day. It was probably due to IOL touch to anterior lens capsule while centering of IOL. The opacity remained non progressive.

Discussion

The Artisan lens offers advantages of anterior chamber IOLs and can be positioned on pupil center. The Artisan lens can be used for young patients³ having anisometropic amblyopia with restricted treatment options. Our data demonstrated an increase in both UCVA and BCVA after Artisan IOL and show stability of visual acuity and refractive results 1 year after surgery. Beneditti S, Casamenti V.⁴ in their study using artisan PIOL on 93 eyes with 2 year follow up, patients were divided into 2 groups. Group 1 (68eyes) myopia -6.75 to -15.5 D (SE) and group 2 (25eyes) myopia -16.0 to -23.0 D (SE). At 4 months, , 83.8% eyes in group 1 and 68% of eyes in group II achieved UCVA of 6/12 or better. BCVA remained the same or improved in all the patients. 69.1% eyes in group 1 and 52% in group 2 were within +/- 1.0 D of desired correction. The mean refraction was stable from 4 to 24 months, mean endothelial cell loss was 2.8% at 4 months; 3.9% at 12 months and 5.4% at 24 months. Our study compares well with this study except UCVA. This was because only 54.54% of our patients had postoperative BCVA of 6/12 or better.

Several studies concerning Artisan lens implantation reported endothelial cell damage .these include studies by Perez Santonja et al⁵, Landes et al⁶. Although we couldn't measure endothelial cell count, corneal health was good in all eyes of our study group.

Many postoperative complications have been described after iris claw lens implantation. Fechner et al found no evidence of iris atrophy in

fixation area. On the other hand Menezoet al⁷ observed iris atrophy in fixation area. In our study we did not notice iris atrophy during 1 year follow up.

Perez Santonja et al⁵ reported corneal pigment deposition in 18.7 % eyes; in our study the incidence was 18.18%.

Maloney et al⁸ described the development of non progressive lens opacities in 3.1 % eyes as a result of surgical trauma. In our series this was noticed in 2 (9.08%) cases .

Some potential advantages include optical improvement, preservation of accommodation and potential reversibility. Some disadvantages that may restrict the use of Artisan are long term complications to corneal endothelium and anterior chamber structures specially for angle supported lenses and possible cataract development for posterior chamber PCIOLs.

Conclusion

Although it is difficult procedure⁹, our study showed that in experienced hands, there are minimal intraoperative and postoperative complications. The implantation of Phakic IOLs has been projected as an interesting alternative to corneal surgery for the correction of high refractive error. However further follow up is necessary to confirm its efficacy and to monitor long term complications and safety.

References

1. History of Artisan and Artiflexlenses :
Ophtec BV: www.ophtec.com

2. Fechner PU¹, Haubitz I, Wichmann W, Wulff K: Worst -Fechner biconcave minus power phakic iris-claw lens: J Refractive surgery:1999 Mar-Apr;15(2):93-105
3. Lifshitz T, Levy J.: Secondary Artisan Phakic IOL for correction of Progressive high Myopia in a pseudophakic child: J of AAPOS: 2005: 497-498
4. Beneditti S., Casamenti V., Brongionio, Assetto V: Correction of myopia of 7 to 24 D with Artisan Phakic IOL – 2 year follow up: J. Refractive Surg 2005:21: 46-126
5. Perez Santonja J et al: Endothelial changes in Phakic eyes with anterior chamber IOL to correct high myopia: J. Cat. Ref. Surgery:1996:22;1017-1022
6. Landes M, Worst A, et al:Correction of high myopia with Worst claw IOL: J. Ref. Surg. :1995: 11:16-25
7. Menezo J.L. ,Cisneros A L et al: Iris claw phakic lens –Intermediate And long term corneal endothelial changes: European J. of implant Ref. Surg:1994:6:195-199
8. Maloney et al: Management of complications in ophthalmic surgery by Lihtec Wu: Page 24
9. De Silva SR¹, Arun K, Anandan M, Glover N, Patel CK, Rosen P.: Iris claw intraocular lenses to correct aphakia in the absence of capsule support: J. Cataract Refract Surg 2011 Sep : 37(9): 1667-72