



Comparative Study of Functional Outcome of Compression Plating and Interlocking Nailing For Fracture Shaft Humerus in Adults

Authors

Dr. Akshay H. Shah¹, Dr. Amit B. Dhond², Dr. Mishil S. Parikh³

Prof. R. G. Khedekar⁴, Prof. Sunil H. Shetty⁵

¹Junior Resident, Department of Orthopaedics, D Y Patil University's School of Medicine, Navi Mumbai
Email: Aki1986@gmail.com

²Asst. Professor, Department of Orthopaedics, D Y Patil University's School of Medicine, Navi Mumbai
Email: Dr.amitdhond@gmail.com

³Senior Resident, Department of Orthopaedics, D Y Patil University's School of Medicine, Navi Mumbai
Email: Mishil7@gmail.com

⁴Professor, Department of Orthopaedics, D Y Patil University's School of Medicine, Navi Mumbai
Email: rgkhedekar@gmail.com

⁵Professor & HOD, Department of Orthopaedics, D Y Patil University's School of Medicine, Navi Mumbai
Email: Dr_sunilshetty@yahoo.co.in

Corresponding Author

Dr. Mishil S. Parikh

Senior Resident, Department of Orthopaedics, D Y Patil University's School of Medicine, Navi Mumbai
Email: Mishil7@gmail.com

ABSTRACT

Aim: The aim of our study is to find the difference between the functional outcome between the dynamic compression plating (DCP) and the intramedullary interlocking nailing in diaphyseal fractures of the humerus in adults, as measured by the DASH questionnaire, the mean duration of union and associated complications.

Materials and Methods: From November 2012 to November 2014, 38 patients with diaphyseal fractures of the humerus were treated with compression plating using dynamic compression plate or with intramedullary interlocking nail after randomizing with the help of computer generated list. Postoperatively both groups received same type of physiotherapy (mobilization). They were followed up regularly every two weeks until radiological union. The time taken for radiological union in the two groups was compared. After satisfactory radiological union, the functional outcome was assessed by the "Disabilities of Hand, Shoulder and Elbow (DASH)" Questionnaire.

Results: Primary radial nerve palsy was seen in 3 patients, out of which 2 patients recovered completely. Associated injuries were seen in 20 patients. The functional outcome was better in DCP group compared to interlocking nailing group which was statistically significant ($P= 0.024$). A marginal difference was noted

in the time taken for union. The average time taken for union in the DCP group was 16.06 weeks and in the interlocking group it was 14.05 weeks. The average time for union in all the 34 patients was 15.05 weeks. Two fractures treated with DCP remained un-united. The complication associated with interlocking group was more than the DCP group.

Conclusion: We are of the opinion that when surgery is opted as a choice of treatment, both the modalities of treatment i.e. dynamic compression plating and interlocking nailing are good as far as union of the fracture is concerned, but considering the number of complications and functional outcome, we opine that dynamic compression plating offers better result than antegrade interlocking nailing with respect to pain and function of the shoulder joint. We therefore conclude that in cases where both dynamic compression plating and antegrade interlocking nailing can be done, we would prefer to use dynamic compression plating, as the results are better than antegrade interlocking nailing.

Keywords: Diaphyseal Humerus Fracture, Dynamic Compression Plate, Interlocking Nail, DASH Score.

INTRODUCTION

Fractures of the humeral shaft are common and accounts for 2% of all fractures^[1] Fractures of humeral shaft have traditionally been treated with conservative methods, using either a hanging arm cast or a functional brace. However, the humerus is difficult to immobilize rigidly, because of its articulation with scapula, as scapulohumeral joint is the most mobile of joints.^[2]

Constant contraction of the surrounding muscles and the pull of gravity tend to distract the fracture fragments. Other disadvantages of conservative treatment include joint stiffness, oedema, muscle. Operative treatment for humerus fractures has usually been reserved for the treatment of non-union, associated with fractures of forearm, for poly trauma patients, and for those with neuro-vascular complications. The advantages of operative management are early mobilization and patient comfort. Most of the studies have used fracture union as the major determinant of the outcome and very few studies have examined the functions at the shoulder and elbow.^[3]

The optimal method of humeral shaft fracture fixation remains in debate. Two techniques

under study include intramedullary nailing and dynamic compression plate fixation.

Plating provides satisfactory results but requires extensive dissection, and meticulous radial nerve protection.^{[4][5]}

With the dynamic success of intramedullary fixation of fractures of the femur and tibia, there was speculation that intramedullary nailing might be more appropriate for humeral shaft fractures than dynamic compression plating.

The theoretical advantage of intramedullary nailing included less invasive surgery, an undisturbed fracture hematoma and use of a load sharing device support.^{[6][7]}

However, the phenomenon success of interlocking nailing in long bones like femur and tibia is not seen in humerus. According to recent studies there is not much difference in the outcomes of both methods of fixation of humeral fractures.

The purpose of this study is to compare the outcomes of each method of fixation (dynamic compression plating and interlocking nailing) for the fracture shaft of humerus and to analyse

statistically significant difference in the results of these two methods.

MATERIALS AND METHODS

Between November 2012 and November 2014, 27 males and 11 females aged between 22 to 70 years with fresh humeral shaft fractures with or without neurological deficits were selected for the study. They underwent either dynamic compression plating (n=18) or antegrade interlocking nailing (n=20). Patients with pathological fractures, malunited fractures or grade IIIb and IIIc compound fractures were excluded.

Bone quality and fracture characteristics played an important role in determining the fixation options. 27 patients had suffered fractures in motor vehicle accidents, 3 were domestic injuries 7 were fall from height and 1 was sports injury. The right arm was involved in 23 patients and left arm in 15 patients.

The indication for surgery in 19 patients were concomitant injuries requiring early mobilization, which, included lower limb fractures in 12 patients, which were fracture shaft femur in 3, sub trochanteric fracture in 1, fracture neck femur in 2, fracture acetabulum with dislocation in 1, posterior dislocation in 1, fracture shaft tibia in 1 patient, tibial plateau fracture in 1 patient, Patellar fracture in 2 patients. There were 2 patients with upper limb fractures, which included fracture lower end radius in 1, and fracture both bones forearm in 1 patient, 1 patient had rib fracture and 1 had clavicle fracture. 1 patient had head injury. 2 patients had abdominal injury 1 patient had paraplegia due to fracture dislocation of spine. In

19 patients failure to attain good reduction by closed means was an indication for surgery. 3 patients had pre-operative radial nerve palsy, out of which 2 patients recovered completely. The duration from injury to treatment varied from 1 to 11 days (average being 3.92 days).

All open wounds were thoroughly debrided, and intravenous antibiotics were started and continued postoperatively.

For the plating group, the patient was placed in a prone position for the posterior approach and a supine position for the anterolateral approach with the arm on a sideboard. Disturbance of blood supply to the bone was avoided by minimal soft-tissue and periosteal stripping. The fractured ends were scooped and the medullary canal was opened. Anatomic reduction was achieved, and a dynamic compression plate of adequate size was fixed with at least 5 to 6 cortical holds on each side.

For the nailing group, 7 to 8 mm diameter nails were used with an apex medial bend with length ranging from 18 to 26 cm. A longitudinal skin incision was made from the most lateral point of the acromion, centering over the tip of the greater tuberosity. The entry portal was made at a point just medial to the tip of greater tuberosity and 0.5 cm posterior to the bicipital groove using a small curved bone awl. Its position in the centre of the canal was confirmed using an image intensifier. The nail was then fixed with proximal and distal locking.

Active and active-assisted range of motion exercises of the elbow and pendulum exercises of the

shoulder were started as early as possible. Usually by 4-7 days mobilization was started. Patients were followed up every second week till 16 weeks and monthly thereafter. Lifting of weights and heavy work was not allowed before fracture healing.

Functional outcome of the upper limb was assessed using the “Disabilities of Arm, Shoulder and Hand” (DASH) Questionnaire at nine months or at full recovery which ever was earlier. Results of the 2 groups were compared using unpaired t test and Chi squared test as appropriate. A ‘p’ value of <0.05 was considered statistically significant.

RESULTS

Respectively in the plating and nailing groups, mean patient ages were 37.28 (range, 22–60) and 35.05 (range, 23–70) years ($p=0.549$, Table 1), mean follow-up periods were 12 and 10 months ($p=0.344$), mean times to union were 16.06 and 14.05 weeks ($p=0.065$, Fig. 1), mean DASH scores were 24.1 and 43.1 ($p=0.024$, Table 2), Intraoperative complication rates were 11% (2/18) and 20% (4/20) [$p=0.365$], non-union rates were 11% (2/18) and 0% (0/20) [$p=0.625$], and Post-operative complications like Impingement, delayed union, infection etc were 33% (6/18) and 65% (13/20) [$p=0.009$]. Two fractures treated with DCP remained un-united.

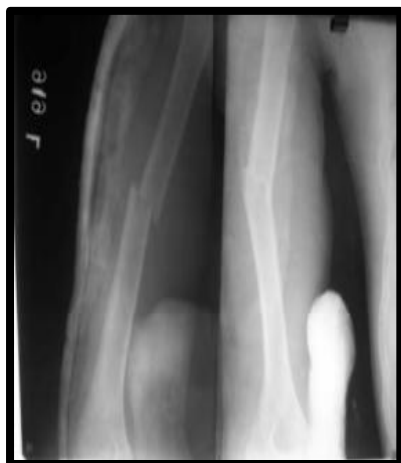Pre-operative radial nerve palsy was present in 3 patients. All the 3 of them were in the DCP group of which 2 recovered completely.

Table 1: Distribution of patients by age

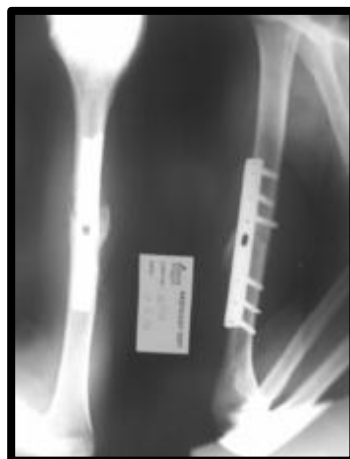
Group	Mean Age
Dynamic Compression Plating	37.28
Intramedullary Interlocking Nailing	35.05

Table 2: Comparison of DASH scores

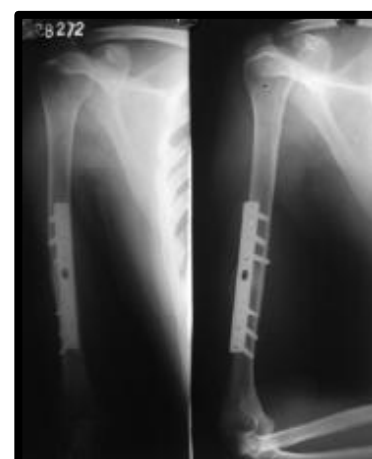Results	Group		Total
	ILN	DCP	
Excellent	2	8	10
Good	6	6	12
Fair	8	2	10
Poor	4	2	6
Total	20	18	38



Pre- Operative

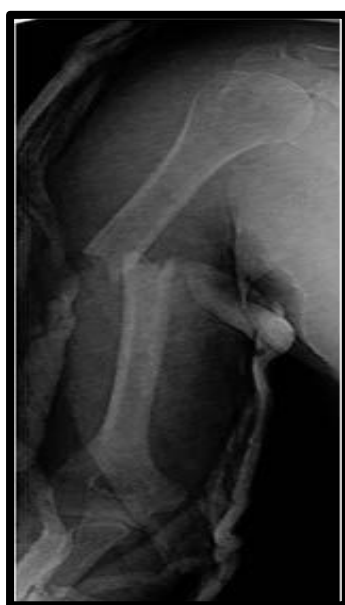

4 Weeks post-op

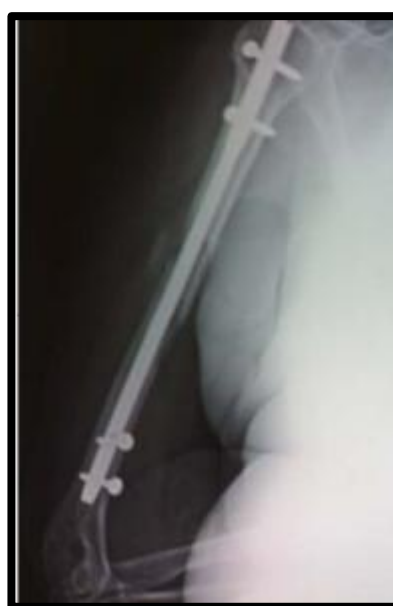

Union at 14 weeks

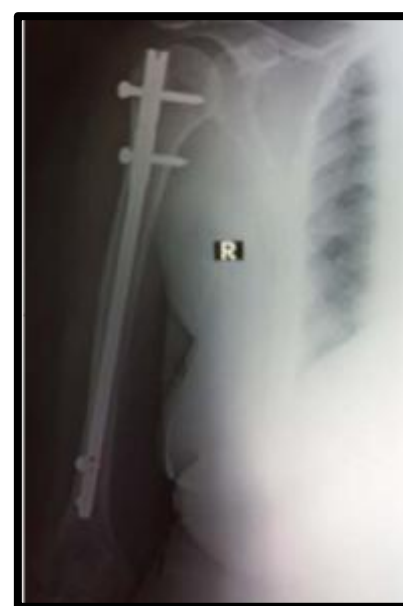Fig No. 1(a): Use Of DCP



Pre-op



6 weeks post-op



Union at 16 weeks

Fig No. 1(b): Use Of Intrrlocking Nail

DISCUSSION

Most surgeons agree that intramedullary nailing is the best internal fixation for femoral and tibial shaft fractures, but there is no agreement about the ideal procedure for fractures of the humeral shaft. Plate osteosynthesis requires extensive soft tissue dissection with the risk of radial nerve damage [8]. The indications for open reduction and internal fixation of acute fractures of the humeral shaft have been described as: fractures

in patients with multiple injuries, open fractures, fractures associated with vascular or neural injuries or with lesions of the shoulder, elbow or forearm in the same limb; bilateral upper extremity injuries, fractures for which closed methods of treatment have failed and pathological fractures [9] [10]. In several reported series, the presence of associated multiple injuries was the most frequent indication for

internal fixation of the humeral shaft^[11]. In our study failed closed reduction and associated injuries were the most common indications. This study is having a short term follow up of minimum of 6 months and maximum of 17 months (mean 11.44months) and therefore discussion is essentially a preliminary assessment. In previous reports the incidence of non-union after plating has ranged from 2% to 4%^[12]. In our DCP group the incidence of non-union is 11.11%. Retrospective studies of locked intramedullary nail fixation quote incidences of non-union ranging from 0% to 8%^[13]. In our series the incidence of non-union in the interlocking nail group is 0%.

The incidence of radial nerve palsy with fracture shaft humerus varies from 6% to 15%. In our series the incidence was 7.9%. Out of the 3cases, 2 cases recovered (66.6%), which tallied with Seddon's and Pollock's series of 70% and 68% respectively. In the DCP group the incidence of post-operative radial nerve palsy is 2% to 5%^[14], but there were no such cases in our study. Which was same in the case of the interlocking group. The incidence of post-operative radial nerve palsy in various studies varies from 2.6% to 14.3%^{[6][7]} in the interlocking group. There was no problem with infection in our patients with only 1 patient having superficial infection (2.63%) among 38 patients, which responded well to debridement and intravenous antibiotics for 3 weeks. The failure of fixation in a case of DCP was due to poor technique due to inadequate hold. When this fracture was replated with the addition of 2 extra holes and bone graft,

the fracture united at 6 months without complications. The patient with implant failure in interlocking group went on to unite uneventfully despite the screw breakage at one of the two distal interlocking sites. The rate of intra operative communiton during interlocking nail insertion with various studies varied from 7.7% to 10%^{[12][13]}. In our series there were 2 (10%) intra operative communitons out of 20 patients treated with interlocking nailing. One occurred at fracture site due to hoop stress and the other at the greater tuberosity during nail insertion. Persistent pain after antegrade nailing is common Habernek and Orthner in 1991 reported good results with Seidel's interlocking nail but later withdrew their support in 1998, as they had not assessed the shoulder functions of their patients properly. The cause of pain could be disruption of the rotator cuff in its avascular zone within 1 cm of its insertion to the greater tuberosity that may lead to poor healing^[15]. 3 patients had developed shoulder pain/stiffness and 11 of our 20 patients in the interlocking nailing group reported some or the other shoulder pain. Our study confirms that antegrade insertion of nail can lead to problems with shoulder function and range of movement probably because of damage to the rotator cuff. The sample size of our study is small with only 38 patients included in the final study. The union rates are comparable in both the groups with the results in excellent and good category are similar (p value insignificant). There were more fair and poor results in the interlocking nailing group compared to DCP group. The complications were

more in the interlocking nailing group with most of them pertaining to poor shoulder function or pain and this difference in the complications was statistically significant. Though interlocking intramedullary nailing is good for specific conditions like pathological fractures, segmental fractures or with associated lower limb fractures which require early weight bearing with crutch walking, we still consider DCP fixation is better than interlocking nailing in treating fractures of the diaphysis of the humerus.

CONCLUSION

Fractures of the shaft humerus are one of the common fractures affecting present generation and treatment modality has to be decided carefully. We are of the opinion that the operative treatment of the humerus fractures should be done in patients with polytrauma and in patients with failed conservative treatment. Both the modalities of treatment i.e. dynamic compression plating and interlocking nailing are good as far as union of the fracture is concerned, but considering the functional outcome and rate of complications, we are of the opinion that dynamic compression plating offers better result than interlocking nailing with respect to pain and function of the shoulder joint. We therefore conclude that in cases where both dynamic compression plating and interlocking nailing can be done, we would prefer to use dynamic compression plating, as the results are better than interlocking nailing. The fallacies in our study are, the sample size is small and we have not taken retrograde interlocking nailing in to consideration.

REFERENCES

1. Bucholz RW, Heckman JD, Court-Brown CM, Tornetta P. Rockwood and Green's fractures in adults. Vol. 1. Philadelphia: Lipincott Williams & Wilkins; 2010:999.
2. Holm CL. Management of humeral shaft fractures. Fundamental nonoperative technics. Clin Orthop Relat Res 1970;71:132–9.
3. Naver L, Aalberg JR, Humeral shaft fractures treated with ready-made fracture brace. Arch Orthop Trauma Surg 1986;106:20–2.
4. Allgower M, Perren S, Matter P. A new plate for internal fixation—the dynamic compression plate (DCP). Injury 1970;2:40–7.
5. Muller ME, Allgower M, Schneider R, Welleneger H. Manual of internal fixation. 3rd ed. Springer-Verbg.
6. McCormack RG, Brien D, Buckley RE, McKee MD, Powell J, Schemitsch EH. Fixation of fractures of the shaft of the humerus by dynamic compression plate or intramedullary nail. A prospective, randomised trial. J Bone Joint Surg Br 2000;82:336–9.
7. Watanabe RS. Intramedullary fixation of complicated fractures of humeral shaft. Clin Orthop Relat Res 1993;292:255–63
8. Ruedi T, Moshfegh A, Pfeiffer KM, Allgower M. Fresh fractures of the shaft of the humerus—conservative or operative treatment? Reconstr Surg Traumatol 1974;14:65–74.

9. Foster RJ, Dixon GL, Bach AW, Appleyard RW, Green TM. Internal Fixation of Fractures and Non-Unions of the Humeral Shaft. JBJS; vol 67-A; No 6; July 1985; 857-64.
10. Bell M.J, Beauchamp, Kellam JK and McMurtry. The Results of Plating Humeral Shaft Fractures in Patients with Multiple Injuries, the Sunny Brook Experience. JBJS Am 1985; Vol – 67; 293-296.
11. Chapman JR, Henley MB, Agel J, Benca PJ. Randomised prospective study of humeral shaft fracture fixation: intramedullary nails versus plates. J orthop Trauma 2000; 31(9): 683-5.
12. Heim D, Herkert F, Hess P, Regazzoni P. surgical treatment of humeral shaft fractures: the Basel experience. J Trauma: 1993; 35:226-232
13. Crolla RMPH, deVries LS, Clevers CJ. Locked intramedullary nailing of humeral fractures. Injury 1993;24: 403-455.1,48,49,75,95
14. Dabezies EJ, Banta CJ, Murphy CP, d'Ambrosia RD. Plate fixation of the humeral shaft for acute fractures with or without radial nerve injuries. J Orthop Trauma: 1992;6:10-13
15. Robinson CM, Bell KM, Court-Brown CM, McQueen MM. Locked nailing of humeral shaft fractures. JBJS-(A): 1992: 74-A: 558-562