

Immediate Overdenture - A Treatment Option for Bone Preservation

Authors

Khurshid A Mattoo¹, Lakshya Yadav², Shuja U Rahman³

¹Assistant Professor, Department of Prosthodontics College of Dentistry, Jazan University, (KSA)

²Lecturer, King George medical college, K.G.M.C University, Lucknow (India)

³Postgraduate student, Department of Prosthodontics, Subharti Dental College, Subharti University, Meerut, (India)

Corresponding Author

Dr Khurshid A Mattoo

Assistant Professor, College of Dental Sciences, Jazan University

Email: drkamattoo@rediffmail.com

Work Attributed to Subharti Dental College and Hospital, Subharti University, Meerut

ABSTRACT

Between very few preventive prosthodontic options, immediate overdenture has not used as frequently as expected and there are few studies indicating their performance. Losing a natural tooth to a convenient treatment plan is one of the major causes for immediate overdenture been scarcely used. With dual advantages the prosthesis offers a delay of edentulous state and/or delay in deterioration of residual alveolar ridges by the amount of time that it will serve in the oral cavity. This article in the form of a clinical case report explores the clinical issues associated with such prosthesis.

Keywords- *extraction, template, surgery, prosthodontics, residual alveolar ridge*

INTRODUCTION

Among innumerable partial edentulous situations, there are certainly few situations where one feels that the treatment offered could or should have been more conservative. Like for example, in spite of many natural teeth present in the oral cavity, one has to recommend an immediate denture even if few

teeth were less mobile. In any profession, convenience should never be sought. Whenever one does it in Prosthodontics, he loses a chance to provide the patient a better care. These have both ethical and legal issues besides one's morals. With advances in single stage endodontic procedures these situations can be managed more conservatively thereby providing most of the

advantages of retaining natural tooth to the patient. Immediate overdenture is a hybrid between immediate denture and overdenture,^{1,2} wherein complete denture prosthesis is inserted into the patient after removing most of the remaining natural teeth but more importantly leaving some of the healthy natural teeth in place to serve as abutments for one or both of the dentures. These remaining natural teeth may fall in the realm between grade 1 and grade 2 mobility; however, when they are reduced to the level of the gingiva the mobility of the tooth becomes less obvious and less harmful.

Prescribing immediate overdenture to a patient needs to fulfill criteria for both immediate and an overdenture.³ Diagnosis is more related to factors for an overdenture whereas the procedure for fabrication follows procedures more as that for immediate denture.⁴ Among specific requirements for this prosthesis, one needs to establish that the overdenture abutments are not indicated for copings thus limiting this prosthesis to situations where minor modifications of natural teeth are indicated.

CLINICAL CASE REPORT

A 53 year old male patient reported to the department of Prosthodontics with chief complaint of dissatisfaction with his existing facial aesthetics and impaired phonetics. Medical, social, drug and other relevant history were non-contributory. Extra oral examination presented an ovoid face with convex profile (**Fig 1A**). Temporomandibular joint and other facial features were within normal range. Intra oral examination presented a Kennedy class 1 partial edentulous situation in both arches with modification two in the maxillary arch. Associated

dental problems included generalized mobility of all mandibular and maxillary teeth (Grade 3) with exception of four teeth on the left and one tooth on the right side of the maxillary arch (**Fig 1B**). Maxillary anterior teeth showed extreme supraeruption with severe malpositioning of the occlusal plane. After thorough radiographic investigations and diagnostic mounting a treatment plan was presented to the patient that included immediate denture for mandibular arch and a non-coping immediate overdenture for maxillary arch. Endodontic treatment was done as part of preliminary treatment in relation to maxillary selected teeth. For both maxillary and mandibular prosthesis functional impressions were recorded as final impressions (**Fig 1 C and D**). Functional impressions were made using a combination of irreversible hydrocolloid (Thixotropic, Zhermach, Italy) and zinc oxide eugenol impression materials (DPI, India).

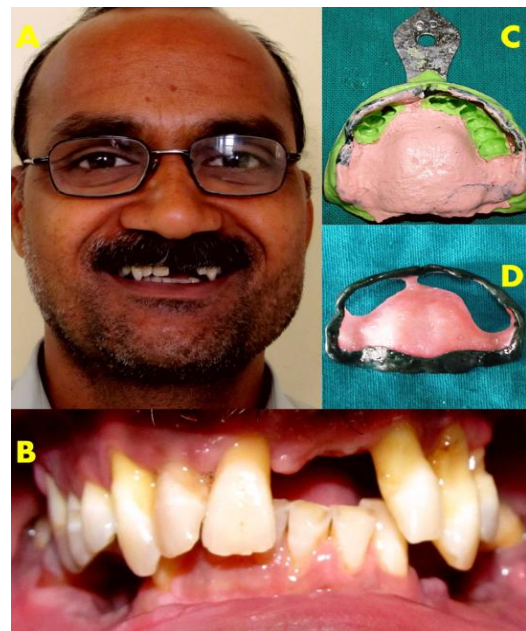

Figure 1: (A) Extra oral view showing visible aesthetic problem (B) intra oral view showing a severe problem of occlusal plane (C) maxillary

functional impression along with (D) the special tray designed

The hydrocolloid was carried on a stock tray whereas the zinc oxide eugenol impression was made on a special tray. Tentative centric relations were recorded to mount maxillary and mandibular casts similar to the method used for a Kennedy class I partial edentulous situation. After verifying tentative jaw relations teeth were arranged on a semi adjustable articulator Hanau Widevue (Waterpik, Ft Collins, USA) by modifying the secondary cast (**Fig 2 A**). Meanwhile, for maxillary arch the teeth that were to be retained to act as overdenture non coping abutment were prepared for the level of 1 mm above gingiva and silver amalgam was filled over them (**Fig 2B**). The rest of the clinical and laboratory procedure followed that for the immediate denture where in a surgical template was made and the denture was processed as for conventional complete denture. At the next clinical appointment maxillary teeth that were not a part of overdenture were extracted following which sutures were placed and the maxillary overdenture was inserted (**Fig 2 C and D**). For the mandibular arch regular extractions were done followed by suture placement and complete denture insertion. The patient was followed up as per the protocol for immediate denture. After a period of 3 months the mandibular and maxillary dentures were relined as per the protocol for immediate dentures.

DISCUSSION

Immediate overdenture as a treatment option has been largely related to dental implants in the literature. There are very few cases that have

reported patients having been treated with such options in a conventional situation. The benefits of such treatment option depends on the existing edentulous state, the needs of the patient, effective diagnosis, treatment plan and design of the prosthesis.⁵⁻⁸ Selection of abutment should place natural teeth on either side of the arch preferably two on either side. The success of such decision depends how long a prosthodontist can utilize the remaining abutment. As it is known that immediate denture requires relining after a period of three to six months, but in this case one needs to understand that any delay in relining would otherwise cause stresses on the overdenture abutment as a result of immediate resorption.^{9, 10}

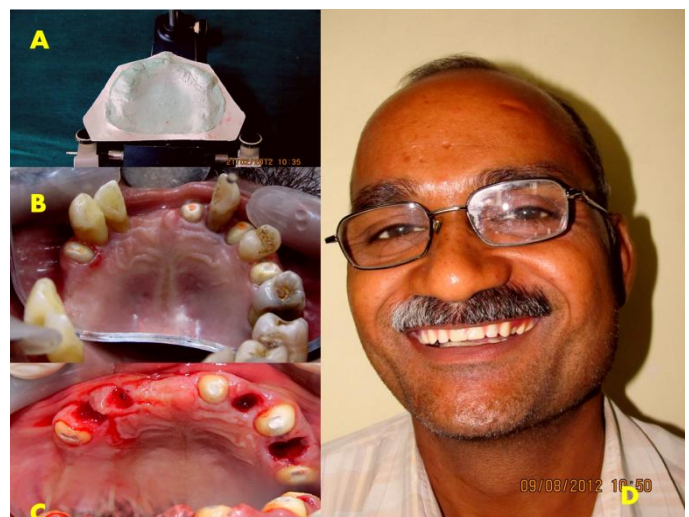


Figure 2: (A) modified cast for immediate overdenture over which surgical template is fabricated (B) preparation of teeth that would serve as abutments for overdenture (C) extraction of remaining natural teeth (D) the final prosthesis worn by the patient

This in turn would cause irreversible damage to the abutments resulting in failure. Therefore clinically evaluation of immediate overdenture at follow up visits should be preceded with certain objectives

one of them is that how much resorption has taken place after extraction of natural teeth. It is often better to delay the amalgam plugging of root canals for this period as abutments may need a further reduction at a later date if sufficient resorption has taken place.

The amount of bone and soft tissue reduction that would be undertaken at the time of extraction is also significant in designing such prosthesis. The discrepancy between the amount of bone removed under the denture and the provision for it during modification of the cast would also result in undue immediate stresses to the abutment. Although there is no such method to measure the two, it is important that the oral surgeon removes only the necessary bone as guided by the surgical splint.

CONCLUSIONS

Before opting for immediate denture as a treatment option for a particular patient one should probe the possibility of an immediate overdenture in such cases. Because the success of such cases depends on clinically related factors, proper diagnosis and treatment plan are essential.

ACKNOWLEDGEMENT

The authors would like to thank the staff of the department of oral surgery who paid needed attention to the requirements of this case.

REFERENCES

1. Brewer AA and Morrow RM. Overdentures made easy, 2nd Ed, The C. V. Mosby Co, St. Louis, 1980

2. Preiskel. Overdentures Made Easy. Chapter 2 Chapter 3, pp. 21-43, pp.45-65.
3. Renner RP and Levy M: Preventive prosthodontics- Overdenture service. NY State Dent J, 1977; 43:17.
4. Morrow R, Feldman E, Rudd K and Trovillion H. Tooth supported complete dentures: An approach to preventive prosthodontics. J Prosthet Dent, 1969; 21:512
5. Rantantanen T, Makila E, Yli-Uspo A and Siirila H. Investigations of the therapeutic success with dentures retained by precision attachments. Suom Hammasl Zik Toim, 67:356
6. Tamura T, Sunozaki M and Miki K. The overdenture using a permanent magnet. Nippon Dental Review, 1978; 433:67
7. Mitani H and Mushimoto E. Overdenture and sensations induced by its supporting roots. Int J Dent Med, 1977;6:209
8. Rissin L, House JE, Manly RS and Kapur KK. Clinical comparison of masticatory performance and electromyographic activity of patients with complete dentures, overdentures, and natural teeth. J Prosthet Dent, 1978; 39:506
9. Crum R and Rooney G. Alveolar bone loss in overdentures. J Prosthet Dent 1978;40:610
10. Loisel RJ, Crum RJ, Rooney GE and Stuever CH. The physiologic basis for overlay dentures. J Prosthet Dent, 1972; 28:4,