



Uterine Myxoid Leiomyosarcoma with Paraneoplastic Syndrome- A Rare Combination

Author

Dr. Shubhadeep Bhattacharjee

MBBS,MS (O&G), Silchar Medical College, Silchar

Corresponding Author

Dr. Shubhadeep Bhattacharjee

C/O Mr. Partha Pratim Bhattacharjee, Giri Bhawan, Durgapally Road, Ghungoor,
Silchar-788014, District –Cachar, State-Assam, Country- India

Email: shubhadeep96bhattacharjee@gmail.com

Abstract

Myxoid leiomyosarcoma of uterus is a very rare malignancy with only 36 cases documented worldwide and no cases reported in the Indian subcontinent. The present case is of uterine myxoid leiomyosarcoma with associated pancytopenia that has not been described previously in the south-east asia and only one such case reported in world literature. A 32 year old woman who is a known case of uterine fibromyoma discovered in her previous pregnancy , presented to the opd with heavy bleeding per vagina. On examination, she had a large abdominal mass. Her hemoglobin was 6.3 g/dl and platelet count was 80,000/cu.mm and also developed leucopenia(4500/cu.mm).She had received five units of blood transfusion, but her haemoglobin and platelet counts remained low. Her bone marrow biopsy report came out to be inconclusive. She underwent laparotomy followed by total hysterectomy with bilateral salphingo-oophorectomy, omentectomy and appendicectomy. Histopathology reports showed uterine myxoid leiomyosarcoma (FIGO stage IIIA). Her haematological profile improved considerably following the surgery and recurred with the recurrence of the disease. Hence, this is considered to be a case of pancytopenia due to paraneoplastic syndrome as a result of the myxoid leiomyosarcoma of the uterus.

Keywords: leiomyosarcoma, paraneoplastic syndrome

Background

Uterine myxoid leiomyosarcoma is a very rare disease and being associated with a paraneoplastic

syndrome, which has not been documented in India or south-east Asia.

Case Presentation

A 32 year old woman, para 3 with three living issues in the postpartum period of her last child, which was delivered by caesarean section due to a fibromyoma of the uterus presented to the opd of department of obstetrics and gynaecology, silchar medical college and hospital, silchar on 20th may 2014, with abdominal pain and discomfort of increasing severity and duration. There was no significant past medical or surgical history. She underwent emergency caesarean section due to prolonged labor with fetal distress due to the fibromyoma in the last pregnancy.

She was offered elective hysterectomy in the postpartum period, but she wished to have more children and so, she opted for elective myomectomy and hysteroscopy. She was given injection GnRH analogue prior to the surgery. During hysteroscopy, a polyp shaped, necrosed mass was found projecting through the internal os . There were lacy fronds of tissue and gelatinous material filling the uterine cavity. Biopsy specimen were taken and myomectomy was abandoned. The histopathology report revealed myxoid degeneration of a submucosal fibroid with necrosis. There were no malignant cells. After this report, the patient changed her mind and opted for hysterectomy. A suitable date was fixed for hysterectomy. Just two days prior to the surgery, she presented with heavy bleeding per vagina.

Investigation

1. Ultrasonography-It revealed a small hypoechoic area at the fundus of the uterus extending to the right adnexa with

complex right adnexal mass of 8*6*8.5 cm.

2. CT scan-It showed the presence of right ovarian mass, a fibromyoma on the right side and adherence to thye right ovary.
3. Blood values- she had a haemoglobin level of 6.3 g/dl and platelet count of 80,000/cu.mm, which were normal at the first visit.

She received five units of compatible blood transfusion, but even after this, her hemoglobin was 7.3 g/dl and platelet count was 97,000/cu.mm. in addition, a new finding of leucopenia (count-4500/cu.mm.) developed. Thus, she was scheduled for a bone marrow biopsy to evaluate her pancytopenia. The bone marrow biopsy results were inconclusive.

Treatment

She underwent laparotomy followed by total hystectomy and bilateral salphingo-ophorectomy (**picture1**). She later on had three cycles of chemotherapy with doxorubicin, gemcitabine and docetaxel.

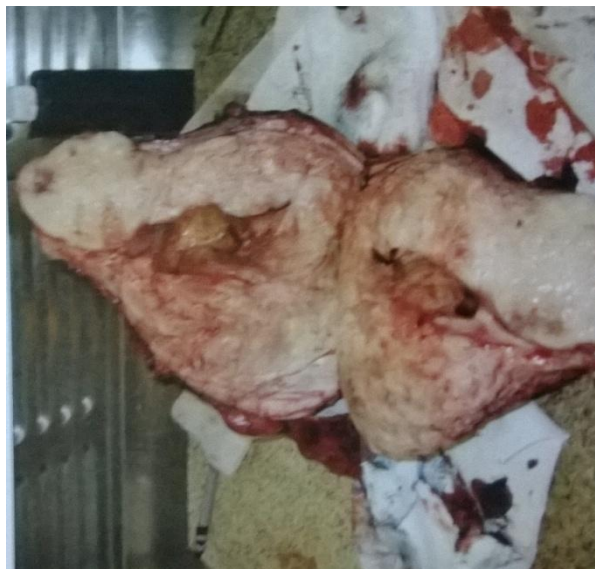Follow-up

Histopathology reports showed a malignant growth of mesenchymal tissue with predominant myxoid stroma (**picture 2**). The cellular morphology was large, pleomorphic with multinucleated cells with abundant mitotic activity. She was diagnosed as a case of uterine myxoid leiomyosarcoma. According to the FIGO classification, she was given a stage of IIIA. Postoperatively, after 10 days, her haemoglobin

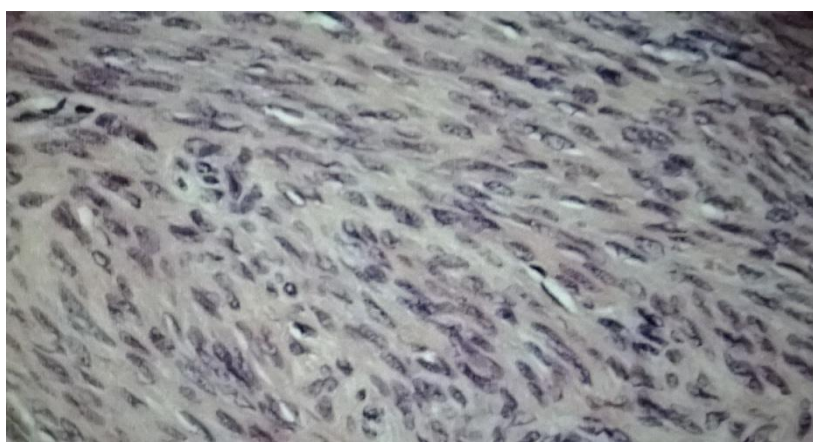
was 11.5 g/dl and platelets 2,50,000. She was eventually discharged.

Her follow-up was done with CT- scan of abdomen and pelvis. Her chest CT showed

multiple pulmonary nodules in both lungs which was suggestive of metastases. She is currently on chemotherapy with doxorubicin.



Picture 1: post operative specimen of the present case



Picture 2: histopathology slide of the present case

Discussion

Uterine sarcomas are rare malignancy of the uterus and account for 2.5-3% of all uterine malignancies. They can be either leiomyosarcomas, carcinosarcomas or mixed forms. leiomyosarcomas are most common¹.

Their classical presentation is with irregular vaginal bleeding, abdominal mass and abdominal pain. Histopathologically, the leiomyosarcomas are differentiated from the benign neoplasms with the findings of hypercellularity, mitotic figures and atypia¹

Myxoid leiomyosarcoma is a rare tumour of uterus with no case yet being reported in Indian subcontinent. It is also a diagnostic challenge, both due to rarity of the disease and the lack of facilities in developing countries.²

The first case of leiomyosarcoma of uterus was reported by King et al³ in 1982, when they reported a series of six cases, aged 47-68, all presenting with vaginal bleeding and pelvic mass. Till now, in world literature only 36 cases of uterine myxoid leiomyosarcomas have been documented. Our patient fitted the classical symptoms of leiomyosarcomas in many ways. She was aged 32, which was within the age range of 20-75 yrs^{4,5}. During her first visit, she had complained of abnormal vaginal bleeding and abdominal lump⁶ as notified in previous literatures. The lump was about 25 cm in greatest diameter, well within the range of 5-45 cm as documented in previous literatures^{2,3}. Also, she underwent total abdominal hysterectomy and salphingo-oophorectomy, which was the treatment of most of the patients previously documented.

In this patient, the only problem that was unusual was her pancytopenia in addition to the usual features of bleeding and abdominal mass. This has been recorded only once in medical literature⁷. The main challenge was to explain the relationship between altered haematological findings and the leiomyosarcomas. I, suggest the following theories which could possibly explain these findings-

It could have been a paraneoplastic syndrome which is associated with a highly malignant growth like leiomyoisarcoma⁸. This is because the

haematological findings improved after surgery and reappeared during the progression of the disease in follow-up. Such paraneoplastic syndromes causing poancytopenia been reported previously in carcinoma of lung but not in gynaecological malignancies⁹. Pancytopenia in patients with malignancies but without obvious bone marrow metastases is very rare. Uterine leiomyosarcomas have never been documented to have been associated with pancytopenia and hypocellular bone marrow in the Indian subcontinent.

Other theory that explain these findings is that she may have developed DIC, owing to her thrombocytopenia but she had a normal PT and aPTT, which rule out clotting disorders. Also, it could be argued that she had developed metastases to the lungs, which had caused the paraneoplastic syndrome as it is commonly seen in carcinoma of lung. But her pre-operative chest findings were normal, so this theory can be ruled out as well. Thus, the paraneoplastic syndrome, associated with uterine leiomyosarcomas explains the unusual haematological findings in this case.

Thus, it can be concluded that this case is a rare form of uterine malignancy with aggressive growth and unusual haematological findings most probably due to associated paraneoplastic syndrome.

Conflicts of interests: none

Consent of patient: obtained

Ethical clearance; obtained.

References

1. Papadopoulos AJ, Kenny A. Solid malignant uterine tumors. *Curr Obstet Gynaecol* 2001;2:296-301
2. Vigone A, Giana M, Surico D et al. Massive myxoid leiomyosarcoma of the uterus. *Int J Gynaecol Cancer* 2005;15:564-
3. King ME, Dickersin GR, Scully RE. Myxoid leiomyosarcoma of uterus. A report of six cases. *Am J Surg Pathol* 1982;6:589-98
4. Kagami S, Kashimura M, Toki N et al. myxoid leiomyosarcoma of uterus with subsequent pregnancy and delivery. *Gynaecol oncol* 2002;85:538-42
5. Ng WK, Lui PC, Ma L. Peritoneal washing cytology findings of disseminated myxoid leiomyosarcoma of uterus: report of case with emphasis on possible differential diagnosis. *Diagn Cytopathol* 2002;27:47-52.
6. Kunzel KE, Millsw NZ, Muderspach LI, et al. Myxoid leiomyosarcoma of the uterus. *Gynaecol Oncol* 1993;48:277-80.
7. Ritchie J, Kumari U. A case report of uterine leiomyosarcoma. *British Med J* 2011;2:46-
8. A shour AA, Verschraegen CF, Kudelka AP, et al. Paraneoplastic syndromes of gynaecologic neoplasms. *J Clin Oncol* 1997;15:1272-82
9. Raz I, Shinar E, Pollack A. Pancytopenia with hypercellular bone marrow-a possible paraneoplastic syndrome in carcinoma of the lung; a report of three cases: *Am J Haematol*;1994;16:403-8.