

www.jmscr.igmpublication.org

Impact Factor 3.79

ISSN (e)-2347-176x



Journal Of Medical Science And Clinical Research

An Official Publication Of IGM Publication

## Case of an Epiphrenic Esophageal Diverticulum: A Rare Cause of Dysphagia

Authors

**Dr. Renuka S Melkundi<sup>1</sup>, Dr. Santosh S. Garag<sup>2</sup>, Dr. Vijay G Bidkar<sup>3</sup>  
Dr. Roshan Jalisatgi<sup>4</sup>, Dr. Ravi Udgir<sup>5</sup>**

<sup>1</sup>MS, DLO, Assistant Professor Department of ENT SDMCMS& H, Dharwad, INDIA

<sup>2</sup>MS, Assistant Professor Department of ENT SDMCMS& H, Dharwad, INDIA

<sup>3</sup>MS, Assistant Professor Department of ENT SDMCMS& H, Dharwad, INDIA

<sup>5</sup>MS, DLO, Senior Resident Department of ENT BIMS, Bidar, INDIA

Corresponding Author

**Dr. Renuka S Melkundi**

MS, DLO

Assistant Professor Department of ENT SDM College of Medical Sciences & Hospital Dharwad 580009

Karnataka, INDIA

Email: [renusat1234@rediffmail.com](mailto:renusat1234@rediffmail.com)

### ABSTRACT

**Introduction:** *Epiphrenic oesophageal diverticulum is one of the rare causes for dysphagia. Most of the patients remain asymptomatic only about one-third of diverticuli produces symptoms severe enough to seek medical attention or surgical intervention.*

**Case Report:** *An elderly 72 years old female patient has come to ENT opd with a history of foreign body ingestion 10 days back following which patient developed dysphagia for both solids and liquids. Patient has been evaluated for dysphagia wherein it revealed an incidental finding of epiphrenic esophageal diverticulum, but there is no any evidence of foreign body has been detected.*

**Conclusion:** *Our case report illustrates that epiphrenic diverticulum may be an underlying cause for dysphagia. Wherein rigid esophagoscopy has been done to rule out the foreign body but it has left with an incidental finding of Esophageal epiphrenic diverticulum which is a rare cause of dysphagia.*

**Keywords:** *Dysphagia, Esophageal epiphrenic diverticulum, foreign body*

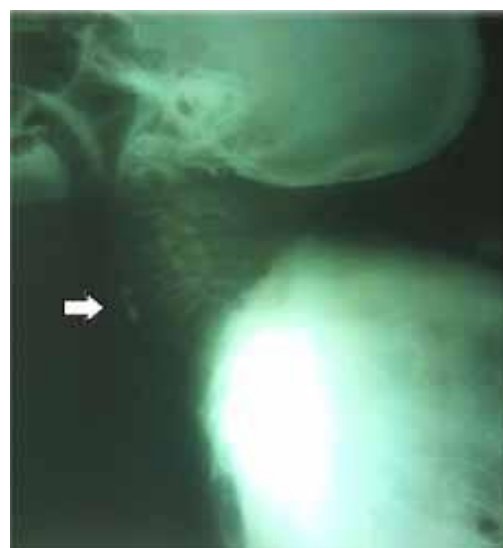## INTRODUCTION

Epiphrenic oesophageal diverticulum is rare and usually is a pulsion type pseudo diverticulum that occurs in association with motility disorders of the oesophagus. Esophageal diverticulum is an out pouching or sac of the epithelial lined tissue of the esophagus<sup>1</sup>. It may be true diverticulum involving all layer of esophagus or a false diverticulum involving only mucosa and submucosal layer of esophagus that have herniated through the muscular wall<sup>2</sup>. Oesophageal diverticula are categorized into **a)** Upper (Zenker's), **b)** middle and **c)** lower (epiphrenic)<sup>3</sup>. Epiphrenic diverticula typically occurs within 10 cm. of the esophago-gastric junction<sup>4</sup>. Most diverticula are asymptomatic, but occasionally chest pain or regurgitation can be the prominent symptoms<sup>7,10</sup>. Treatment consists of managing the underlying motility disorders and for symptomatic diverticula, diverticulotomy with or without myotomy is advocated.

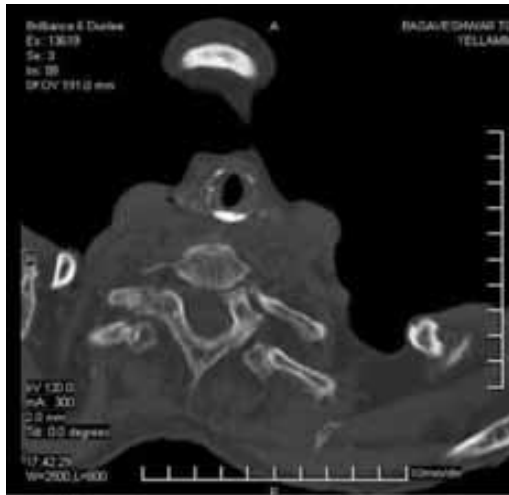
## CASE REPORT

We report a case of 72 yrs old female patient who presented to our ENT opd with a history of foreign body ingestion (piece of mutton) ten days back following which she developed dysphagia. Initially it was for solid foods later progressed to the liquids and also associated with odynophagia. Patient was investigated with routine blood tests, ECG & plain radiograph of neck lateral view taken. Routine blood investigations were within normal limits. Plain radiograph of neck lateral view revealed a radiopaque shadow at the level of C-6 (Fig-1). Provisional diagnosis of suspected

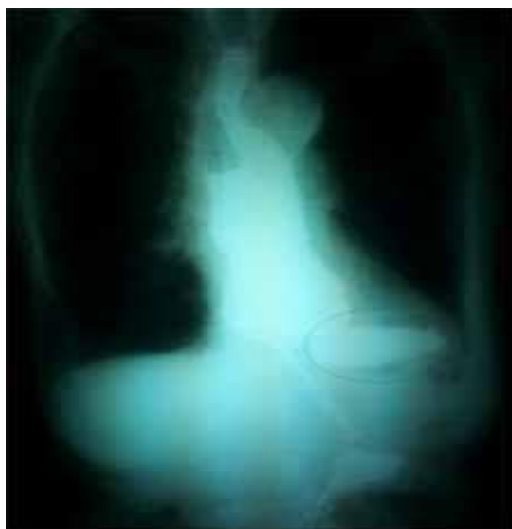foreign body at the level of C-6 was done. Patient was taken for rigid esophagoscopy under general anaesthesia. No evidence of foreign body could be traced but double lumen of esophagus was seen at 30cms from the upper incisor teeth. At the level of double lumen in the esophagus the mucosa was congested and oedematous. However the second opening of the blind ended pouch was seen on left side of the main lumen of the esophagus. Patient has been further investigated with CT-scan of the neck to rule out radiopaque shadow which was seen in plain radiograph, confirmed by CT-scan as calcified cricoid cartilage (Fig.2). Later barium swallow x-ray (Fig.3) and flexible upper GI endoscopy was done, which confirmed the diagnosis of an epiphrenic diverticulum (Fig.4). Due respect to her age, general condition & minimum symptomatology patient has been deferred diverticulectomy and given a trial of conservative line of treatment. Patient responded well and follow up for 1 yr has been done. No dysphagia or any complications noted during this follow up period.



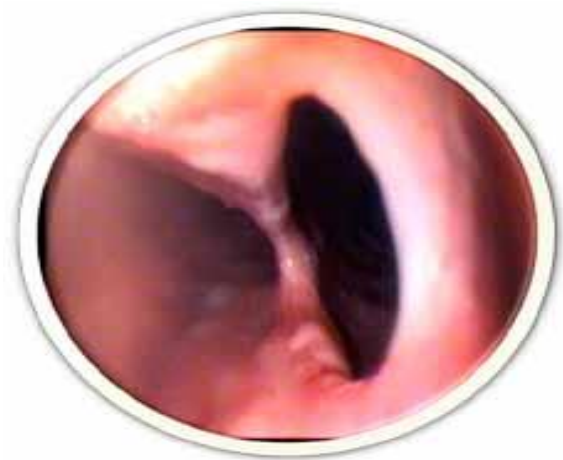**Fig.1-** x- ray lateral view neck showing radiopaque shadow mimicking foreign body.



**Fig.2** - CT- scan neck showing calcified cricoid cartilage.



**Fig.3** - Barium swallow x-ray showing epiphrenic diverticulum



**Fig.4** - Flexible upper GI endoscopy showing diverticulum

## DISCUSSION

The wide spectrum of symptoms caused by epiphrenic oesophageal diverticulum mimics common conditions like heartburn, dysphagia, odynophagia, chest pain, regurgitation or weight loss<sup>5,6</sup>. These diverticula are often the result of a motility disorder, such as achalasia or diffuse esophageal spasm<sup>7,10</sup>.

However in as many as 40% of patients the diverticulum will be asymptomatic<sup>7</sup>. Barium swallows x-ray and flexible upper gastro intestinal endoscopy acts as diagnostic tools in confirming the diagnosis. Patients with undiagnosed epiphrenic diverticula are also at increased risk for cancer<sup>3</sup> which occurs at a frequency of 0.3 to 3% for patients with this condition<sup>5</sup>. Unfortunately in cases of epiphrenic diverticulum, carcinoma is often advanced at the time of diagnosis<sup>8</sup>.

Asymptomatic and minimally symptomatic epiphrenic esophageal diverticula do not require treatment. The standard treatment of these diverticula is surgical. However the presence of diverticulum is not an indication for the surgery. There is almost a consensus that surgery should be preserved for symptomatic patients. Patients with minimal symptoms should be managed conservatively<sup>7,8</sup>. The traditional surgical treatment for an epiphrenic diverticulum consists of esophageal myotomy diverticulectomy or diverticulopexy and minimally invasive laparoscopic techniques.

## CONCLUSION

Our case report illustrates that epiphrenic diverticulum may be an underlying cause for

dysphagia. In this case rigid esophagoscopy has been done to rule out the foreign body, but it has left us with an incidental finding of epiphrenic diverticulum which is a rare cause for dysphagia. Hence it has been concluded that epiphrenic diverticulum is one of the rare cause for dysphagia in an elderly patients and also should be kept in mind that it can be detected during a routine rigid esophagoscopy as it happened in our case where the epiphrenic diverticulum turned out to be the underlying cause for dysphagia but not the foreign body.

### SUMMARY

Epiphrenic esophageal diverticulum is one of the rare cause of dysphagia in an elderly patient Only one third of patient seek medical or surgical intervention As rigid esophagoscopy is routine procedure in ENT this condition should be kept in mind

### ACKNOWLEDGEMENT

We acknowledge Dr. Arunkumar JS and Dr. Ashok Naik for their guidance and support.

### REFERENCES

1. Jeremy H.conklin, DO,MPH,MBA; Deepak Singh,MD; Mark R Katlic, epiphrenic esophageal diverticula; Spectrum of symptoms and consequences, JAM Osteopathic association oct 2009m ;10,543-545
2. Evander A,LittleAG, Ferguson MK, Skinner DB. Diverticula of the mid and lower esophagus: Pathogenesis and surgical management. World J Surg 1986; 10: 820-828.
3. Matthews BD, Nelms CD, Lohr CE, Harold KL, Kercher KW, Heniford BT. Minimally invasive management of epiphrenic esophageal diverticula. Am Surg.2003;69:465-470.
4. Klaus A, Hinder RA, Swain J, Achem SR. Management of epiphrenic diverticula. J Gastrointest Surg. 2003;7:906 -911.
5. Honda H, Kume K, Tashiro M, Sugihara Y, Yamasaki T, Narita R, et al. Early stage esophageal carcinoma in an epiphrenic diverticulum. Gastrointest Endosc.2003;57:980-982.
6. Fasano NC, Levine MS, Rubesin SE, Redfern RO, Laufer I. Epiphrenic diverticulum: clinical and radiographic findings in 27 patients. Dysphagia.2003;18:9-15.
7. Benacci JC, Deschamps C, Trastek VF, Allen MS, Daly RC, Pairolero PC. Epiphrenic diverticulum: results of surgical treatment. Ann Thorac Surg.1993;55:1109-1113.
8. Song YC, Zhang YD, Wang QZ, Yan JS, Du XQ, Zhang MG, et al. Carcinoma in the esophageal diverticulum. Chin Med J (Engl). 1985;98:895-898.
9. Fernando HC,Luketich JD, SamphireJ,et al. Minimally invasive operation for esophageal diverticula. Ann ThoracSurg; 80: 2076-2080.
10. D'ugo D, Cardilla G,Granone P,etal: Esophageal Diverticula; physiopathologic

basis of surgical management, Eur J  
cardiothoracic surg 1992;6: 330-334.