



## Primary Splenic Hydatid Cyst- A Rare Case

Authors

**Dr Rajkamal Kanojiya<sup>1</sup>, Dr Abhinav Mittal<sup>2</sup>, Dr Raghav Tantia<sup>3</sup>, Dr Shameer Deen<sup>4</sup>  
Dr S C Dutt<sup>5</sup>**

<sup>1</sup>Assistant Professor, Department of Surgery, PG Resident Department of General Surgery

<sup>2,3</sup>PG Resident Department of Surgery,

<sup>4</sup>PG Resident Department of Surgery,

<sup>5</sup>Professor Unit Head Department of Surgery

Mahatma Gandhi Medical College & Hospital Sitapura Jaipur (Rajasthan) India 302022

Email: [drrajkamalkanojiya@gmail.com](mailto:drrajkamalkanojiya@gmail.com)

### INTRODUCTION

Primary extrahepatic hydatid cysts are a very rare presentation, Splenic hydatid cysts are usually secondary to either intra-operative spillage of daughter cysts or post operative hydatidosis. Primary splenic hydatid cysts constitute 2% to 3.5% of all hydatid cysts. The most common site of disease is the liver, followed by the lungs, kidney, bones and brain. Other sites such as the heart, spleen, pancreas and muscles are very rarely involved. We are reporting a case of a primary isolated splenic hydatid cyst.

### CASE PRESENTATION

We report a case of 25-year-old female, presented with painless lump in upper abdomen since 10

years. On examination, the lump was occupying left hypochondriac region crossing the midline and extending up to umbilicus. It was well moving with respiration with limited side to side mobility. Patient complained of malaise with nausea, and gradual weight loss since last one year. There was intermittent fever every fifteen days since last two months. She had no history of jaundice, cough, respiratory distress or abdominal trauma and her past medical history was unremarkable. She underwent needle aspiration from the swelling few months back at some rural nursing home and where 2.5 liter of clear fluid was drained. Sonography whole abdomen and contrast computed tomography revealed a cystic lesion arising from the spleen. Abdominal

ultrasonography showed round, well defined, cystic lesion of approx., size 23 × 16 cm compressing the left kidney. Plain radiograph of the abdomen revealed well-defined, rounded soft-tissue opacity with calcified margins in the left hypochondrium. Chest radiograph was normal. Abdominal CT scan shows large cystic lesion measuring 25 × 18 × 14 cm originating from the spleen parenchyma. It also shows curvilinear hyperdense structure suggestive of membranes within the lesion. The lesion was found to compress and displace left kidney and left adrenal posteriorly, pancreas towards the right side and stomach along with left lobe of liver anteriorly suggestive of hydatid cyst arising from the spleen. On exploratory laparotomy, the spleen along with the cyst was removed. Postoperative course was uneventful and patient was discharged on 3<sup>RD</sup> day on albendazole. Stitches were removed on 10<sup>th</sup> day. Histopathologic examination revealed a hydatid cyst. Follow up CT scan after four weeks showed no recurrence and recovery was uneventful.

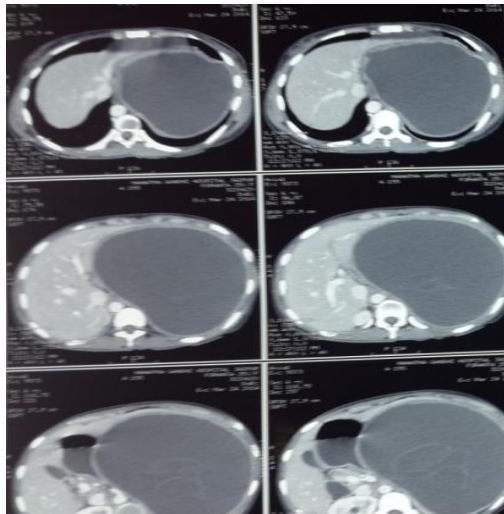
## DISCUSSION

Hydatid cysts represent nearly two-thirds of cystic lesions of the spleen [1-3]. However, splenic hydatid cysts account for only 0.5% to 8% of all hydatidosis [4] and are generally asymptomatic. Hydatid disease is a zoonosis caused by ingesting eggs of the parasite *Echinococcus granulosus* in rural sheep farming regions. After ingestion, the eggs hatch and oncospheres penetrate through intestinal mucosa and enter the circulation. The

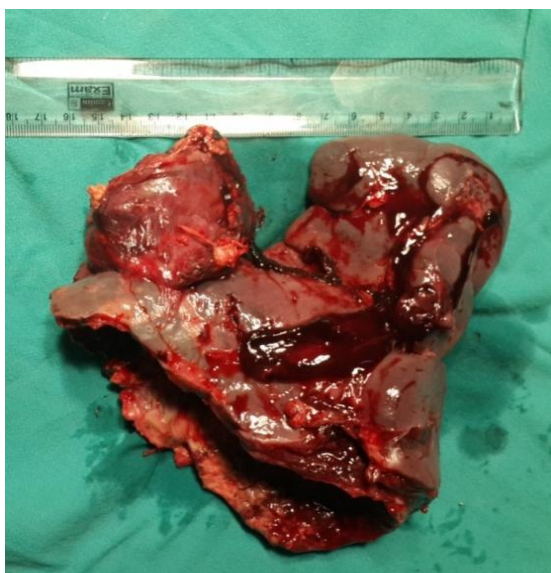
embryos then reach the liver are carried to the liver and get trapped in the sinusoidal capillaries. Some of the embryos may pass through the hepatic capillaries, enter the pulmonary circulation and filter out in the lungs. Wherever the embryo settles, it forms a hydatid cyst. Human echinococcosis is caused by the tapeworm of the genus *Echinococcus*. Of the four known species of *Echinococcus*, three are of medical importance in humans. These are *Echinococcus granulosus*, causing cystic echinococcosis (CE); *Echinococcus multilocularis*, causing alveolar echinococcosis (AE); and *Echinococcus vogeli* [5] causing polycystic echinococcosis (PE). The cyst grows slowly at a rate of 0.3-1 cm per year and sometimes it may take 5-20 years to grow into size to cause symptoms of abdominal discomfort [6]. Berlott (1790) was the first to describe splenic hydatidosis as an autopsy finding [7]. Diagnosis is usually established incidentally during investigation of unrelated symptoms. When the cyst reaches an advanced size, the patient presents with a painless mass in the left hypochondrium. Some patients may present with complications such as infection of the cyst, rupture of the cyst into the peritoneal cavity, fistula formation into hollow viscera like colon or stomach [8]. The treatment is principally surgical. Splenectomy has been the treatment of choice for splenic hydatid cysts since it is easy, rapid and effective. Pre and postoperative administration of albendazole is used to sterilize the cyst, reduce the risk of anaphylaxis, decrease the tension in the cyst wall and to reduce the postoperative

recurrence rate<sup>[9]</sup>. Intra-operatively hypertonic saline or 0.5% silvernitrate is instilled into the cyst before opening it. This tendsto kill the daughter cysts, thereby preventing further spread and anaphylactic reaction<sup>[9]</sup>.Careful aggressive splenectomy without spillage is the gold standard treatment of patients with hydatid cysts

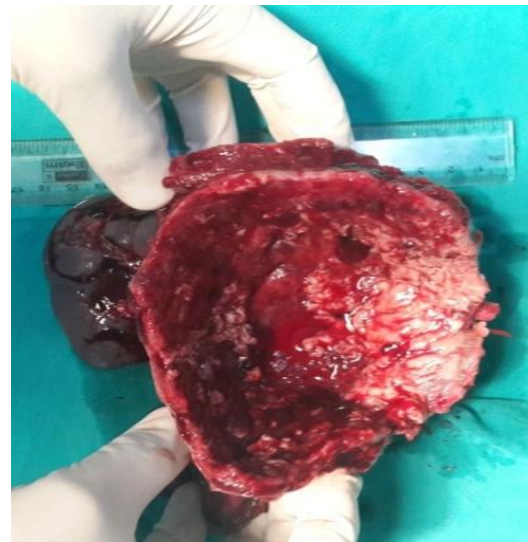Keywords: Hydatidosis, Spleen, Echinococcus.  
Splenectomy



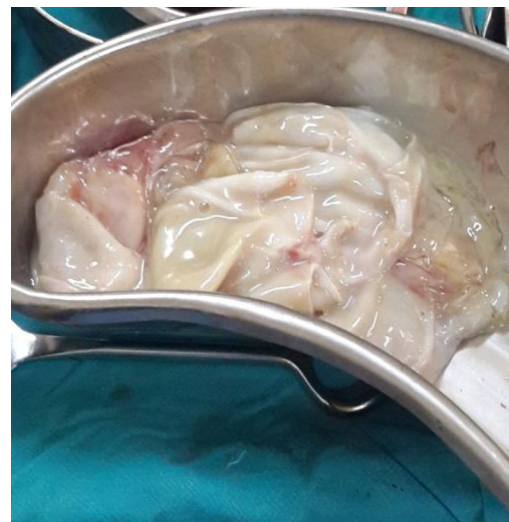**Fig. 1.** Figure one CT scan picture shows large hydatid cyst in spleen.



**Fig. 2.** Gross picture of splenic hydatid cyst 25x18x15 cm.



a



b

**Fig. 3.** Shows cut section of splenic hydatid cyst in centre there is (a)pericystic reaction of hydatid cyst.(b)The hydatid cyst in the cavity

**CONCLUSION**

Hydatid cyst spleen is a rare but important diagnosis. Hydatid disease should be considered in the differential diagnosis of all cystic masses in the spleen/(abdomen), especially in the geographical regions where the disease is endemic. An early diagnosis and treatment had an almost complete cure from the disease. Surgical

excision is the mainstay of the treatment, but all preparatory measures must be undertaken to treat possible anaphylactic reaction.

## REFERENCES

1. Wani RA, Malik AA, Chowdri NA, Wani KA, Naqash SH. Primary extrahepatic abdominal hydatidosis. *Int J Surg.* 2005;3:125–7.
2. Amr SS, Amr ZS, Jitawi S, Annab H. Hydatidosis in Jordan: an epidemiological study of 306 cases. *Ann Trop Med Parasitol.* 1994;88:623–7.
3. Kune GA, Morris DL. Hydatid disease. In: Schwartz SI, Ellis H, editors. *Maingots abdominal operations*. London: Appleton and Lange; 1990. p. 1225–40.
4. Ammann RW, Eckert J. Cestodes. *Echinococcus*. *Gastroenterol Clin North Am.* 1996;25:655–89.
5. Kir. A, Baran. E, Simultaneous operation for hydatid cyst of right lung and liver. *Thorac cardiovasc Surgeon.* 1995;43:62-4
6. Wani NA, Tak S, Shah ND, Bashir A, Arif SM. Bullet injury causing rupture of spleen with hydrated cyst. *JK Prac* 1998;5:55-56.
7. Muro J et al. demonstration angiographica del quisite hidatidico de bazo. *Rev Clin Esp* 1969;115:433-438.
8. Bitton M, Kleiner-Baumgarten A, Peiser J, Barki Y, Sukenik S. Anaphylactic shock after traumatic rupture of a splenic echinococcal cyst [Article in Hebrew]. *Harefuah.* 1992;122:226–8.
9. Kune GA, Morris DL. Hydatid disease. In: Schwartz SI, Ellis H, editors. *Maingots abdominal operations*. London: Appleton and Lange; 1990. p. 1225–40.