

www.jmscr.igmpublication.org Impact Factor 1.1147

ISSN (e)-2347-176x



Journal Of Medical Science And Clinical Research

An Official Publication Of IGM Publication

Differential Diagnosis of Alzheimer's Disease and Other Types of Dementia with Development of Neuroimaging Techniques (PET, SPECT, and MRI)

Authors

Mwahib Sid Ahmed Mohammed Osman Aldosh

Ph. D, Assistant Professor, Co-ordinator of Radiological Sciences Department

Applied Medical College - Najran University- Kingdom of Saudi Arabia,

Email-mwahibaldosh@yahoo.com

ABSTRACT

Number of neurodegenerative diseases that cause dementia, such as Alzheimer's disease, dementia with Lewy bodies, and front temporal dementia. In medical diagnosis many people's cannot differentiate between Dementia and Alzheimer's disease, neuroimaging has played a variety of roles in the study of Dementia and Alzheimer disease (AD) over the past four decades. Initially, computed tomography (CT) and then magnetic resonance imaging (MRI) were used diagnostically to rule out other causes of dementia. recent study have shown the value of neuroimaging techniques including Structural MRI (Magnetic resonance imaging) and functional imaging by SPECT (Single Photon Emission Computerized Tomography) as well as 18FFDG PET (Positron Emission Tomography) which are widely used in the diagnosis of Alzheimer's disease to delineate the differential diagnosis with other types of Dementia . These modalities and their particular utilities are discussed in this review The aim of the study is to evaluate functional differences that might reflect differences in the distribution of their respective pathologies. These evaluation is very important because extensive neuropath logical damage occurs before clinical diagnosis, so preclinical discrimination between people who will and will not ultimately develop AD is critical for treatment of the disease in its earliest stages.

Key Words: *Alzheimer's disease; Dementia ; SPECT; PET; MRI; differential diagnosis*

INTRODUCTION

Early diagnosis of Alzheimer's disease (AD) by neuroimaging:

Alzheimer's disease (AD) is a progressive neurodegenerative disorder characterized behaviorally by gradual and eventually devastating memory loss, and cellularly by neuron loss, neuritic plaques and neurofibrillary tangles. Before AD is diagnosed, its hallmark behavioral symptom is a gradual decline in declarative memory—conscious long-term memory for everyday experiences. This memory impairment is thought to result from a slowly progressing neuropathology that occurs first in medial temporal lobe structures critical for declarative memory, and later in frontal, lateral temporal and parietal cortices(1).

The significance of memory complaints in subjects who do not yet match the criteria for AD but who are at high risk of developing a full-blown dementia syndrome in the next few years has recently attracted attention. This at-risk state is commonly referred to as mild cognitive impairment (MCI) (2). It has been recognized that the concept of MCI may be heterogeneous, although the most common subtype, that is, amnesic MCI, likely progresses to AD and fulfills the following criteria: memory concern, usually by the patient but preferably corroborated by an informant; objective memory impairment for age; were prevalence of AD is below 1% in people aged 60–64 y but shows an almost exponential increase with age, so that in people aged 85 y or older, the prevalence is between 24%

and 33% in Western countries (3). Thus, aging is the most obvious risk factor for AD. Moreover, the female-to-male prevalence of AD is 70% and is likely related to the increased life expectancy of women. In order to clarify whether AD represents a disease rather than exaggerated aging, the relationship between normal aging and neuroimaging findings should be investigated. Recent advances in instruments have facilitated investigations of functional and structural alterations in fine structures of not only cortical but also subcortical areas with a high spatial resolution.

SPECT(Figure1) and MRI have been used for the imaging diagnosis of AD. and ^{18}F -FDG PET(Figure2) for early AD because of its higher sensitivity and higher spatial resolution. SPECT offers the advantages of lower cost and ease of access, which could lead to a large increase in the number of cases being studied with this technique. Few studies have directly compared brain perfusion SPECT and PET in differential AD from other types of Dementia.(3)

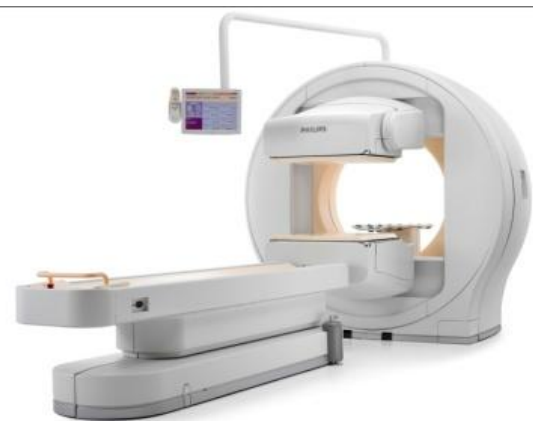

Figure 1- SPET Scanner

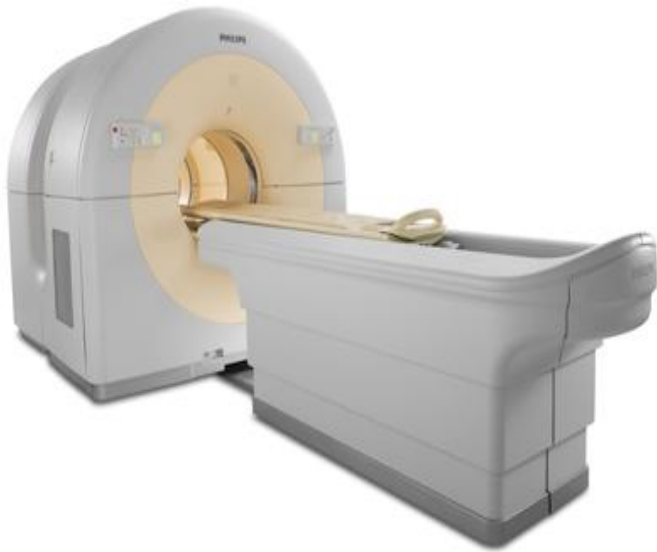

Figure 2-PET Scanner

DEMENTIA WITH LEWY BODIES (DLB):

DLB is the second most common form of degenerative dementia, accounting for up to 20% of cases in older people in Europe and the United States. It has also been increasingly diagnosed with the development of neuroimaging techniques PET, SPECT, and MRI . It is characterized by the clinical triad of fluctuating cognitive impairment, spontaneous parkinsonism, and recurrent visual hallucinations. Consensus clinical criteria have been published (4) and have been shown to have high specificity but may still lack sensitivity. Pathologically, DLB may be classified as a Lewy body disorder or as a-synucleinopathy. Although both DLB and AD show reductions in presynaptic cholinergic transmission from the basal forebrain, in DLB there are also deficits in cholinergic transmission from brain stem nuclei. Postsynaptic cortical muscarinic receptors are more functionally intact

in DLB, suggesting a potential responsiveness to cholinergic enhancement. An accurate diagnosis of DLB is clinically important, as the management of psychosis and behavioral disturbances is complicated by sensitivity to neuroleptic medications.

There is accumulating evidence to suggest that DLB may be particularly amenable to cholinergic enhancers. Neuroimaging findings indicated a relative preservation of medial temporal lobe structures and rCBF(Relative cerebral Blood flow)in DLB (5,6). Significant reductions in dopamine transporter levels were found in the caudate and putamen in subjects with DLB relative to subjects with AD (7). Several studies also indicated subtle differences in perfusion patterns on SPECT or 18F-FDG PET, with a greater degree of occipital hypoperfusion or hypometabolism in DLB than in AD (Fig. 3)

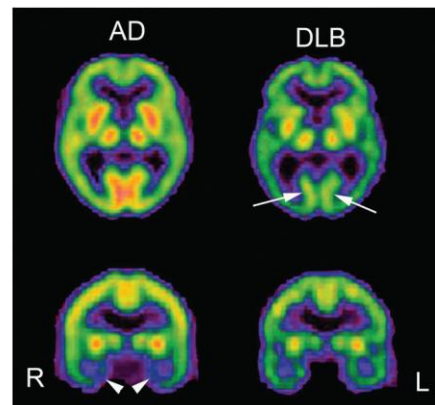


Figure 3. Comparison of brain perfusion SPECT images for moderate AD and moderate DLB.

DLB showed lower perfusion in occipital cortex than AD (arrows). In contrast, AD showed lower perfusion in medial temporal areas (arrowheads).

(8,9). Minoshima et al. (8) reported a high sensitivity (90%) and a high specificity (80%) for the accuracy of discriminating AD from DLB on the basis of the finding of hypometabolism in the occipital cortex. Recently, an alternative method (cardiac uptake of ^{123}I -metaiodobenzylguanidine) for differentiating AD from DLB was reported (10).

Markedly decreased cardiac uptake was observed in DLB because of cardiac sympathetic denervation. Frontotemporal Dementia (FTD) FTD is a heterogeneous clinicopathologic syndrome caused by progressive degeneration of the frontal lobes, anterior temporal lobes, or both. In contrast to other types of dementia, FTD involves the relative preservation of memory and visuospatial skills but early alterations in behavior and personality. In the absence of a biologic marker for this disorder, clinicians diagnose FTD on the basis of these criteria and use neuroimaging and other test results as corroborative features. PET(Figure3) and SPECT(Figure4) studies revealed the preferential involvement of the frontotemporal regions in FTD. Jeong et al. (11) demonstrated a decrease in glucose metabolism in extensive cortical regions, such as the frontal and anterior temporal areas, cingulate gyri, uncus, and insula, and subcortical areas, including the basal ganglia and medial thalamic regions; this metabolic feature may help to differentiate FTD from AD or other causes of dementia. Bonte et al. (12) emphasized the presence of a decrease in rCBF in the posterior cingulate gyrus (posterior cingulate sign) for differentiating AD from FTD.

Sixteen of 20 AD patients showed the posterior cingulate sign. In contrast, only 1 of 20 FTD patients showed this sign. In addition to the cortical changes that occur in AD, subcortical neuronal losses occur in the nucleus basalis of Meynert, resulting in decreases in the cortical levels of cholinergic markers (13). Pharmacologic, biochemical, and functional imaging observations have implicated a cholinergic defect underlying many behavioral abnormalities in AD. Donepezil hydrochloride is a piperidine-based acetylcholinesterase inhibitor that is clinically used for the symptomatic treatment of mild to moderate AD. Donepezil has been shown to significantly improve cognition and to maintain global function compared with placebo and also to be well tolerated. The results of 24-wk studies have indicated that the well-established benefits of donepezil for cognition may extend to an improvement in the ability to perform complex activities of daily living (14). Although donepezil has been approved in many countries for the treatment of mild to moderate AD, its effect on cerebral blood flow or metabolism has not been fully investigated yet. Using $^{99\text{m}}\text{Tc}$ hexamethylpropyleneamine oxime SPECT with SPM analysis, Mega et al. (15) found that the presence of lower lateral orbital frontal and dorsolateral frontal perfusion suggested a good response to donepezil and was significantly related to behaviors of irritability, disinhibition, and euphoria. Nobili et al. (16) compared the longitudinal SPECT findings over 15 mo, on average, between stabilized and nonstabilized

subjects receiving donepezil treatment. No significant difference was found between the baseline and repeat SPECT data in the stabilized subjects. In contrast, in the nonstabilized subjects, a significant reduction in rCBF was found in the frontal, temporal, and parietal superficial cortices and in the occipital precuneus in the right hemisphere and in the frontal and mesial temporal cortices in the left hemisphere. On repeat SPECT, rCBF was found to be significantly lower in the left frontal region in the nonstabilized subjects than in the stabilized subjects. Ceravolo et al. (17) reported that SPM analysis revealed significant increases in rCBF in the right anterior cingulate, dorsolateralprefrontal, and bilateral temporoparietal areas after shortterm (4-mo) acetylcholinesterase inhibitor therapy with respect to the baseline. These data suggest that cognitive or behavioral benefits after cholinesterase inhibitor therapy are related to clear increases in rCBF in crucial areas specifically involved in the attention and limbic networks. The longitudinal study of Nakano et al. (18) showed that, before and 1 y after the administration of donepezil, the adjusted rCBF was significantly preserved in the right and left anterior cingulate gyri, right middle temporal gyrus, right inferior parietal lobule, and prefrontal cortex in 15 donepezil-treated AD patients compared with 20 placebo-treated AD patients. Treatment with donepezil appeared to reduce the decline in rCBF, suggesting a preservation of functional brain activity.(18)

CONCLUSION:

PET, SPECT, and MRI (Figure4)have played very important rolesin diagnosing early Alzheimer at the mild cognitive impairment(MCI)stage, and differentiating it from other types of dementia. This study demonstrates the practical feasibility of cognitive PET, SPECT, and MRI data in patients with DLB and provides preliminary evidence of activation and deactivation patterns that differentiate such patients from those with Alzheimer’s disease. The challenge for the future will be to combine imaging biomarkers to most efficiently facilitate diagnosis.

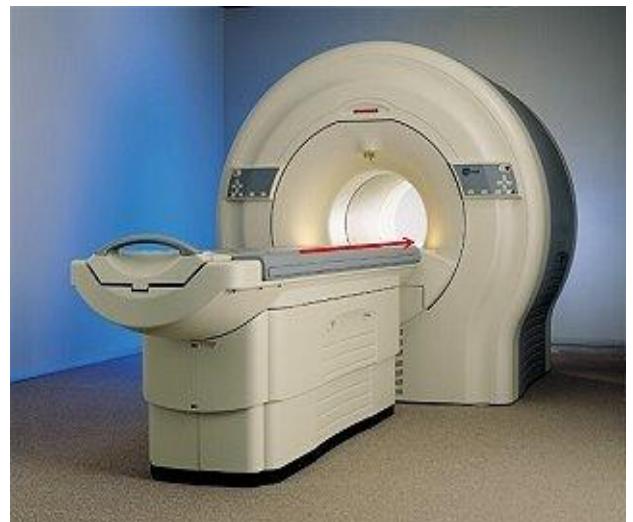


Figure 4 -MRI Scanner

ACKNOWLEDGEMENT:

I would like to give my grateful thanks to prof . Jumaa Tamboul who contributed to the project and for his correction , support and great help. The researcher also gratefully acknowledges the Dean ship and staff of the College of Medical Radiological Sciences, Najran University . Firstly and finally, my thanks to my Allah, the most gracious and most merciful.

REFERENCES:

1. Terry RD, Masliah E, Salmon DP, et al. Physical basis of cognitive alterations in Alzheimer's disease: synapse loss is the major correlate of cognitive impairment. *Ann Neurol.* 1991;30:572–580.
2. Wallin AK, Andreasen N, Eriksson S, et al. Donepezil in Alzheimer's disease: what to expect after 3 years of treatment in a routine clinical setting. *Dement Geriatr Cogn Disord.* 2007;23:150–160.
3. Petersen RC, Doody R, Kurz A, et al. Current concepts in mild cognitive impairment. *Arch Neurol.* 2001;58:1985–1992.
4. Blennow K, de Leon MJ, Zetterberg H. Alzheimer's disease. *Lancet.* 2006;368:387–403.
5. McKeith IG, Dickson DW, Lowe J, et al. Diagnosis and management of dementia with Lewy bodies: third report of the DLB Consortium. *Neurology.* 2005;65:1863–1872.
6. Barber R, Ballard C, McKeith IG, Gholkar A, O'Brien JT. MRI volumetric study of dementia with Lewy bodies: a comparison with AD and vascular dementia. *Neurology.* 2000;54:1304–1309.
7. Colloby SJ, Fenwick JD, Williams ED, et al. A comparison of (99m)Tc-HMPAO SPET changes in dementia with Lewy bodies and Alzheimer's disease using statistical parametric mapping. *Eur J Nucl Med Mol Imaging.* 2002;29:615–622.
8. O'Brien JT, Colloby S, Fenwick J, et al. Dopamine transporter loss visualized with FP-CIT SPECT in the differential diagnosis of dementia with Lewy bodies. *Arch Neurol.* 2004;61:919–925.
9. Minoshima S, Foster NL, Sima AA, Frey KA, Albin RL, Kuhl DE. Alzheimer's disease versus dementia with Lewy bodies: cerebral metabolic distinction with autopsy confirmation. *Ann Neurol.* 2001;50:358–365.
10. Pasquier J, Michel BF, Brenot-Rossi I, Hassan-Sebbag N, Sauvan R, Gastaut JL. Value of (99m)Tc-ECD SPET for the diagnosis of dementia with Lewy bodies. *Eur J Nucl Med Mol Imaging.* 2002;29:1342–1348.
11. Yoshita M, Taki J, Yokoyama K, et al. Value of 123I-MIBG radioactivity in the differential diagnosis of DLB from AD. *Neurology.* 2006;66:1850–1854.
12. Jeong Y, Cho SS, Park JM, et al. 18F-FDG PET findings in frontotemporal dementia: an SPM analysis of 29 patients. *J Nucl Med.* 2005;46:233–239.
13. Bonte FJ, Harris TS, Roney CA, Hynan LS. Differential diagnosis between Alzheimer's and frontotemporal disease by the posterior cingulate sign. *J Nucl Med.* 2004;45:771–774.
14. Whitehouse PJ, Price DL, Struble RG, Clark AW, Coyle JT, Delon MR. Alzheimer's disease and senile dementia:

loss of neurons in the basal forebrain.
Science. 1982;215:1237–1239.

15. Rogers SL, Farlow MR, Doody RS, et al.
A 24-week, double-blind, placebocontrolled trial of donepezil in patients with Alzheimer's disease. Neurology. 1998;50:136–145.
16. Mega MS, Dinov ID, Lee L, et al. Orbital and dorsolateral frontal perfusion defect associated with behavioral response to cholinesterase inhibitor therapy in Alzheimer's disease. J Neuropsychiatry ClinNeurosci. 2000;12:209–218.
17. Nobili F, Koulibaly M, Vitali P, et al. Brain perfusion follow-up in Alzheimer's patients during treatment with acetylcholinesterase inhibitors. J Nucl Med. 2002; 43:983–990.
18. Ceravolo R, Volterrani D, Tognoni G, et al. Cerebral perfusional effects of cholinesterase inhibitors in Alzheimer disease. ClinNeuropharmacol. 2004;27: 166–170.