



A Rare and Fatal Complication of Diabetes Mellitus

Authors

Dr. Vishal Sopan Yesankar¹, Dr. Nalini R Humaney², Dr. Ramesh P Mundle³

¹Department of Medicine, NKPSIMS, Nagpur
Email: *drvishalyesankar@gmail.com*

²Department of Medicine, NKPSIMS, Nagpur
Email: *nrhumaney@rediffmail.com*

³Department of Medicine, NKPSIMS, Nagpur
Email: *rpmundle@gmail.com*

Corresponding Author

Dr. Vishal Sopan Yesankar

Department of Medicine

NKPSIMS, Nagpur

Email: *drvishalyesankar@gmail.com*

Abstract

Emphysematous pyelonephritis (EPN) is an acute suppurative infection of the kidney. It is an uncommon infection, occurs mostly in patients with diabetes and a predilection for females. It has a high fatality rate; therefore, aggressive medical, early intervention or surgical approach is recommended. We present a case with a classical presentation with more than two risk factors and who required nephrectomy.

Keywords: pyelonephritis; diabetes mellitus; nephrectomy

INTRODUCTION

EPN is a severe necrotizing infection of the kidney and its surroundings. The first case was described in 1898 by Kelly and Maccullum (1). Most of the cases are reported in diabetics or with obstructive uropathy. Patients are usually critically ill, with a high mortality. (2). E.coli is the most common causative pathogen isolated on urine or pus culture in nearly 70% of the reported cases(3).

CASE REPORT

A 50 year old female patient known case of diabetes mellitus type 2 was admitted with complaints of abdominal pain since 6 days, high grade fever since 5 days, vomiting since 3 days. She was a known case of diabetes mellitus type 2 since 6 years on Inj. Actrapid 15 units before breakfast and before dinner. Patient was also a known case of alcoholic liver disease.

On examination patient was conscious, oriented. She was febrile, pulse= 110/ min, B.P.= 90/50 mm of Hg, pallor was present. On abdominal system examination diffuse tenderness was present all over abdomen more in left lumbar region with renal angle tenderness, left kidney was ballotable. Rest of the examination findings were within normal limits.

On investigations, her Haemoglobin= 8.8 mg/dl ,TLC= 16000/ cumm ,platelet count= 1.02 lacs/cumm. Urine examination was suggestive of 20-25 pus cells/cumm , urine culture and sensitivity was suggestive of E.coli that was sensitive to amikacin and meropenem, urea= 79.2 ,creatinine= 2.8 , HbA1c =12.3 .Blood culture revealed no growth. Plain x ray abdomen standing (figure 1) was suggestive of gas within the left kidney. Ultrasonography of abdomen was suggestive of emphysematous pyelonephritis affecting the left kidney with obstructing calculus in left pelvi-ureteric junction.

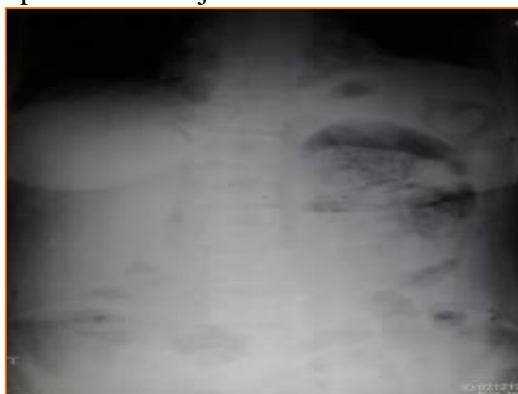


Fig.1- X-ray abdomen showing features suggestive of gas within the left kidney parenchyma.

Urosurgery opinion taken and urgent nephrectomy was done. The left subcostal incision was given. There were large number of pus flakes over the left kidney and in surrounding area with release of air from kidney after excision. Dissection was done, renal artery and vein ligated and divided. Kidney mobilised, ureter ligated and divided. Left nephrectomy was done, hemostasis was achieved. Histopathology of the removed kidney showed features of acute pyelonephritis with extensive patchy areas of suppurative inflammation and necrosis (figure 2), also glomeruli showed diffuse increase in mesangial matrix with thickened capillary walls, and a nodule (kimmelstiel-wilson lesion) of diabetic glomerulosclerosis (figure 3)



Fig 2.- The histopathology of the removed kidney showed features of acute pyelonephritis with extensive patchy areas of suppurative inflammation and necrosis with adjacent renal tissue displaying intratubular and interstitial inflammatory cells including neutrophilic infiltrates (H&E stain,10x magnification)

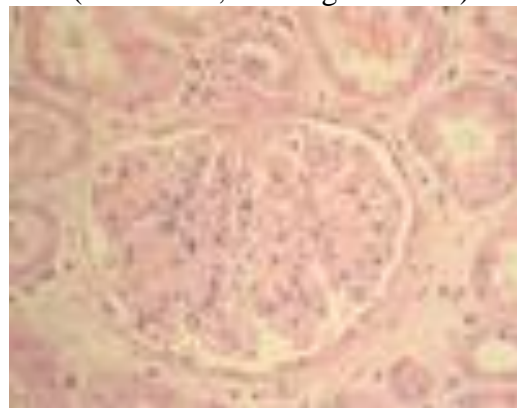

Fig 3.- The histopathology of the glomeruli showing diffuse increase in mesangial matrix with thickened capillary walls and a nodule (kimmelstiel-wilson lesion) of diabetic glomerulosclerosis (H&E stain, 40x magnification)

Post operatively patient was started on higher antibiotics. Injection meropenem, and injection metrogl were started according to patients creatinine clearance. Patient was in hypotension and hence was put on inotropic support. Post-operative urea was 53.7 and serum creatinine was 2.8. Total leucocyte counts were 24000/cumm. The patient's condition progressively worsened and took a rapid downhill course, despite aggressive hemodynamic and inotropic support. Finally, the patient developed an intractable septicemic shock and died on 4 th post operative day. .

DISCUSSION

EPN is necrotizing infection of the renal parenchyma and its surrounding areas that results in the presence of gas in the renal parenchyma, collecting system, or perinephric tissue(4-10). It occurs exclusively in patients with diabetes mellitus (DM), occasionally in patients without DM along with obstruction of the corresponding renoureteral unit(11-13). *E coli* or *K pneumoniae* in patients with diabetes mellitus and/or urinary tract obstruction is the main culprit. Mixed acid fermentation of glucose by enterobacteriaceae is the major pathway of gas formation.

Patients present with :

Fever, abdominal pain ,nausea and vomiting ,dyspnea , acute renal impairment , altered sensorium, shock, crepitus. Comorbidities include alcoholism, malnourishment, renal calculi, and diabetic ketoacidosis.

Laboratory findings include:

Leukocytosis, pyuria , thrombocytopenia, an elevated creatinine level, positive blood culture results.

Plain x-ray abdomen can be more specific than sonography in detecting air in the renal collecting system but both have series limitations because of superimposition of gas from the bowel or retroperitonium. Computed tomography (CT) scanning is the definitive imaging test for EPN. Several patterns have been described as CT findings including streaky, streaky and mottled, and streaky and bubbly. Gas can extend into perinephric area, renal vein or inferior vena cava (4). Perinephric abscess may lead to significant gas accumulation in the perinephric space. A stone may be seen in the collecting system. Kidneys, ureter, and bladder imaging often reveals gas distribution over the region of the kidneys.

A system proposed by Michaeli et al and modified by Huang and Tseng is as follows(1,4) :

Class 1: Gas confined to the collecting system

Class 2: Gas confined to the renal parenchyma alone

Class 3a: Perinephric extension of gas or abscess

Class 3b: Extension of gas beyond the Gerota's fascia

Class 4: Bilateral EPN or EPN in a solitary kidney.

Conservative treatment is indicated in:

Patients with severely compromised renal function, early cases associated with gas in the collecting system alone, and patient is in otherwise stable condition. It consists of prompt hydration, systemic antibiotics, relief of obstruction with percutaneous drainage or stent placement, rapid control of diabetes.

Nephrectomy is indicated if there is no access to percutaneous drainage or internal stenting (after patient is stabilized) ,gas in the renal parenchyma or "dry-type" EPN, possibly bilateral nephrectomy in patients with bilateral EPN, class 3 and class 4 EPN or in the presence of more than 2 risk factors (eg, thrombocytopenia, elevated serum creatinine, altered sensorium, shock).

Mortality is 70% in patients managed medically and 30% in those managed surgically. EPN should be suspected in patients who have multiple comorbidities and present with severe sepsis.

REFERENCES

1. Tang HJ, Li CM, Yen MY, Chen YS, Wann SR, Lin HH, et al. Clinical characteristics of emphysematous pyelonephritis. *J Microbiol Immunol Infect.* 2001;34(2):125-30. [PubMed]
2. Flores G, Nellen H, Magaña F, Calleja J. Acute bilateral emphysematous pyelonephritis successfully managed by medical therapy alone: A case report and review of the literature. *BMC nephrol.* 2002;3(1):4.
3. Ubee SS, McGlynn L, Fordham M. Emphysematous pyelonephritis. *BJU Int.* 2011;107(9):1474-8. [DOI] [PubMed]
4. Huang JJ, Tseng CC. Emphysematous pyelonephritis: clinicoradiological classification, management, prognosis, and pathogenesis. *Arch Intern Med.* 2000;160(6):797-805. [PubMed]
5. Michaeli JMogle PPerlberg SHemiman SCaine M Emphysematous pyelonephritis. *J Urol.* 1984;131:203- 208
6. Wan YLLee TYBullard MJTsai CC Acute gas-producing bacterial renal infection: correlation between imaging findings and clinical outcome. *Radiology.* 1996;198:433- 438
7. Godec CJ Cass AS Berkseth R Emphysematous pyelonephritis in a solitary kidney. *J Urol.* 1980;124:119- 121
8. DePauw APRoss G Jr Emphysematous pyelonephritis in a solitary kidney. *J Urol.* 1981;125:734- 746

- 9.Hudson MAWeyman PJvan der Vliet
AHCatalona WJ Emphysematous pyelonephritis:
successful management by percutaneous
drainage. *J Urol.* 1986;136884- 886
- 10.Paivansalo MHellstrom PSiniluoto
TLeinonen A Emphysematous pyelonephritis:
radiologic and clinical findings in six cases. *Acta
Radiol.* 1989;30311- 315
- 11.Gold RPMcClennan BL Acute infection of
the renal parenchyma. Pollack HM*Clinical
Urography.* Philadelphia, Pa WB Saunders
Co1990;799- 821
- 12.Ahlering TEBoyd SDHamilton CL et
al. Emphysematous pyelonephritis: a 5-year
experience with 13 patients. *J
Urol.* 1985;1341086- 1088
- 13.Pontin ARBarnes RDJoffe JKahn
D Emphysematous pyelonephritis in diabetic
patients. *Br J Urol.* 1995;7571- 74
- 14.Shokeir AAEl-Azab MMohsen TEI-Diasty
T Emphysematous pyelonephritis: a 15-year
experience with 20 cases. *Urology.* 1997;49343-
346