



Supernumerary Axillary Breasts: A Case Report

Authors:

Dr. Achala Sahai*, Dr. Jyoti Bindal**

*M.S., M.I.C.O.G.

Assistant Professor,

Dept. of Obst. & Gyn.

G.R. Medical College, Kamla Raja Hospital Gwalior

Gwalior 474001 (M.P.)

**M.S., FACS, FICS, FICOG

LLB, PGDHM.,

Professor

Dept. of Obst. & Gyn., G.R. Medical College

J.A. Group of Hospitals, Gwalior 474001 (M.P.)

Abstract : Polymastia the presence of supernumerary breast tissue is rare and may be found in 2-6% of woman. Axillary breast tissue is a common variant of supernumerary breast tissue and is commonly bilateral and often associated with a distinct areola and nipple. This tissue tends to become symptomatic and noticeable during pregnancy due to hormonal stimulation. Here we report a case of axillary breast tissue, that became symptomatic in a post caesarian case due to engorgement and responded well to conservative treatment.

Keywords: supernumerary breast tissue, axillary ectopic breast tissue.

INTRODUCTION

Polymastia the presence of supernumerary breast tissue is rare and may be found in 2-6% of woman (1) and 1% of men (2). Incidence of accessory mammary tissue also varies among ethnic groups and is more common in Asian women than in black or white woman (3). Axillary breast tissue is a common variant of supernumerary breast tissue (4) and is commonly bilateral and is often associated with a distinct areola or nipple (5). This tissue tends to become noticeable after hormonal stimulation usually during puberty, pregnancy, or lactation (6). Lactation has been reported through

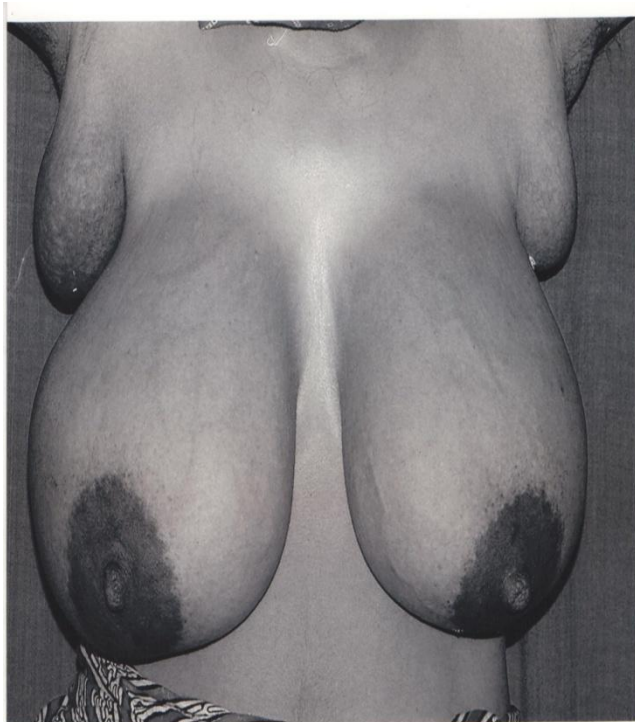
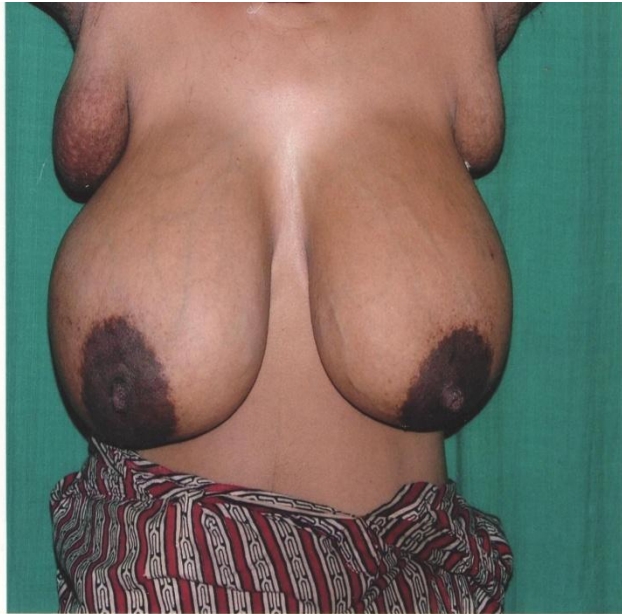skin pores overlying the axillary breasts (7). These structures tend to develop along the embryonic 'milk line' which extends from axilla to groin (8).

Case Report

A 26 year old female, para 2, who had undergone emergency caesarian section for fetal distress in Kamala Raja Hospital complained of painful lumps under her arms on post partum day 3. She admitted that she had small swellings in her axillae since childhood which suddenly enlarged to tender lumps after delivery. She had past history of similar problem but with less severity

during her last delivery also. She denied of having any such family history.

Examination: -- Patient's breasts were engorged without any signs of mastitis. She was afebrile. There were bilateral 5x5 cms, soft, and tender swellings in both axillae without any apparent nipples. There was a circular hyperpigmented area on bases of each swelling from where small amount of colostrum-like fluid could be expressed on applying pressure.



Investigations: All routine investigations were done and were within normal limits. FNAC from the swellings was done which was suggestive of breast tissue.

Management: On examination, diagnosis of accessory axillary breast tissue was made which was later confirmed by FNAC. After proper counseling and explanation the patient was advised either to continue breast feeding with pumping axillary breasts to decrease engorgement or to abandon breast feeding as it could aggravate her symptoms. Patient chose to continue breast feeding which she did for 5-6 months along with good support to breasts, pumping axillary breasts and symptomatic treatment like analgesics and anti-inflammatory drugs.

Follow-up: After six weeks interval patient came for a follow-up visit. Her axillary breasts were considerably reduced in size but were not totally regressed. She was advised regular follow up.

DISCUSSION

Axillary breast tissue may present a diagnostic challenge as many other benign and malignant lesions occur in this area. Patients may be misdiagnosed as having lipoma, axillary lymphadenopathy, hidradenitis suppurativa, enlarged sebaceous cysts etc. FNAC is a useful test to confirm the diagnosis.

Ectopic breast tissue is subject to the same pathologic events that occur in a normally positioned breast like mastitis, fibrocystic changes, fibroadenosis and phylloid tumor (1, 8, 9). But the incidence of malignancy is not more than normal breast tissue (10). Hence women with symptomatic axillary breast tissue should undergo the same screening as those with normally located breast tissue including mammography.

Management of ectopic breast tissue is usually conservative during puerperium and cessation of breast feeding leads to regression of the tissue (1, 4, 5). The enlargement and other associated symptoms are reported to worsen with subsequent pregnancies as in our case (5). Excision by elliptical incision may be required for diagnosis, treatment, or cosmetic purposes.

There is a possible familial inheritance of this embryonic variant. One theory is that an autosomal gene of variable expressivities is inherited that inhibits normal regression of the

embryonic mammary ridge (11). An association between supernumerary breast tissue and renal anomalies has been observed (9, 12). Investigations of the genitourinary tract can only be limited to patients with symptoms.

12. Mehes K- Association of supernumerary nipples with other anomalies. J.pediatr. 1979; 95: 274-275.

REFERENCES

1. Lesavoy MA, Gomez-Garcia A, Nejdil R, Yospur G, Syiau TJ, Chang P- Axillary breast tissue: Clinical presentation & surgical treatment. Ann plast Surg.1995; 35: 356-360.
2. Johnson CA, Felson B, Jolles H- Polythelia (supernumerary nipple): an update. South Med J 1986; 79: 1106-8.
3. Glimore HT, Milroy M, MelloBJ- Supernumerary nipple & accessory breast tissue. SDJ Med 1996; 49(5): 149-51.
4. Bland KI, Romrell LJ- Congenital & acquired disturbances of breast development and growth. In: Bland KI, Copeland EM III, editors. The Breast: Comprehensive Management of Benign & Malignant Diseases: Philadelphia, Pa : WB Saunders Co: 1991;69-86.
5. Greek KE- Accessory axillary breast tissue. Arch Dermatol, 1974; 109: 88-89.
6. Panaik P- Axillary & Vulval breasts, associated with pregnancy. BrJ Obstet Gynecol. 1978; 85: 156-7.
7. Roux JP- Lactation from axillary tail of breast. BMJ. 1955; 1:28.
8. Yerra L, Karnard AB, Vota WML- Primary breast cancer in aberrant breast tissue in the axilla. South Med J. 1997; 90:661-662.
9. Velanovich V- Ectopic breast tissue, supernumerary breasts, and supernumerary nipples. South Med J. 1995; 88: 903-6.
10. Berman MA, Davis GD- Lactation from axillary breast tissue in the absence of supernumerary nipple: a case report. Report Med. 1994; 39: 657-659.
11. Weinberg SK, Motulsky AG- Aberrant axillary breast tissue : a report of a family with six affected women in two generations. Clin Genet. 1976; 10: 325-328.