



Transintestinal migration of needle - Rare case of foreign body in kidney

Vikram Wagh

Email: vikramwagh@hotmail.com

Abstract:

Foreign bodies in the kidney are rare. We report a rare case of trans-intestinal migration of a sewing needle into the right kidney in a 23 year old female who was admitted for intermittent pain in the right flank for 3 years. Patient had history of swallowing a needle accidentally 3 years ago, and was diagnosed to have the same located within the Right renal parenchyma. Radiography revealed a linear metallic shadow in the right kidney. CT scan confirmed it to be in the right renal parenchyma. The foreign body was extracted operatively.

Key words: *Renal foreign body, Trans intestinal Migration of sewing needle in Kidney*

CASE DETAILS:

23 year female patient presented with complaints of Pain in the Right flank intermittent in nature since 3 months. Patient had similar episodes of pain in the past. She had no complaints of fever, haematuria, burning micturition, any trauma or surgery in the past. She revealed to have consumed a needle 3 years ago accidentally. X ray was suggestive of linear metallic shadow in the region of Right kidney directed along the postero-

supero axis at the level of L2-3 vertebra. USG abdomen revealed hyperechoic foreign body piercing upper end of Right kidney. CT abdomen revealed a thin linear non enhancing metallic needle like structure in Right hypochondriac region with contact with second part of duodenum without extravasation of the dye. Haematological investigations were within normal limits.

Right kidney was approached via right subcostal incision, there was a visible granuloma over the

gerota's fascia which on palpation revealed the needle tip protruding through it. Location was confirmed by Image intensifier. Needle grasped with haemostatic forceps and was delivered out. Wound was closed after haemostasis without keeping a drain. Post-operative recovery was uneventful. Patient discharged on 4th post-operative day.

DISCUSSION:

Foreign bodies may reach the kidney by one of three routes:

- through the urethra, bladder, and ureter;
- from the gastrointestinal tract;
- by means of Surgery or external violence

In this case a more bizarre route was taken by the foreign body that was swallowed and probably perforated the intestinal wall at the second portion of the duodenum to enter the Right kidney. The remarkable feature of this case is the behaviour of the foreign body. It had crossed the duodenum, and thereupon the sharp end slowly worked its way through the lateral wall and entered the kidney. This whole process was, completely silent.

“Any foreign body moves towards its least resistance, it can be luminal, transluminal or through tissues but not trophic towards another natural orifice” is the normal dictum. Embedded bodies may remain in the tissues for an indefinite period without giving rise to inconvenience. At any time, however, they may cause trouble, either as a result of infective complications, or by

inducing the formation of a mass of inflammatory tissue around them, which may simulate a gumma, a tuberculous focus or a sarcoma. This latter condition may give rise to difficulties in diagnosis, particularly if there is no history forthcoming of the entrance of the foreign body. In such cases the X-rays will reveal the presence of the foreign body if it is sufficiently opaque.

A similar case has been reported by T. INAI, HIRAIISHI and KUROKAWA, *Department of Urology, University of Tokushima, Japan*. Where a 31 year old male patient swallowed a sewing needle 4 years ago, and was removed operatively with nephrolithotomy.

We have been able to find reports of five cases in which swallowed foreign bodies have perforated the bowel quite silently and entered the kidney. All five were young children, and in all of them the symptoms were predominantly renal operated for nephrectomy.

To date, 12 other cases of foreign bodies in the kidney have been reported in the Japanese and English literature. In the eight cases reported in the Japanese literature there were four acupuncture needles, one sewing needle, a bullet, a piece of debris and a piece of glass from the atomic bomb explosion. In the remaining six cases (Osmond, 1953; Yue and Johnson, 1967; Baird *et al.*, 1968) there was one piece of wire that reached the right kidney trans-intestinally.

Fig 1: Shows Needle visualised in C-arm
Localised with haemostatic forceps

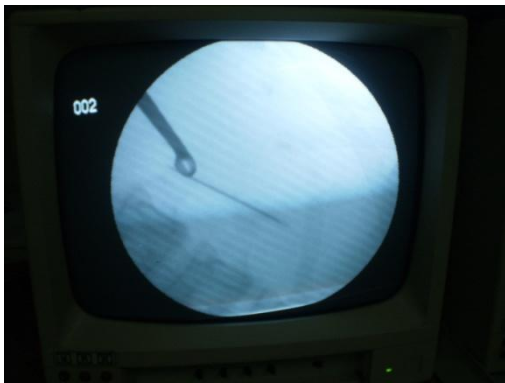

Fig 4 : CT image

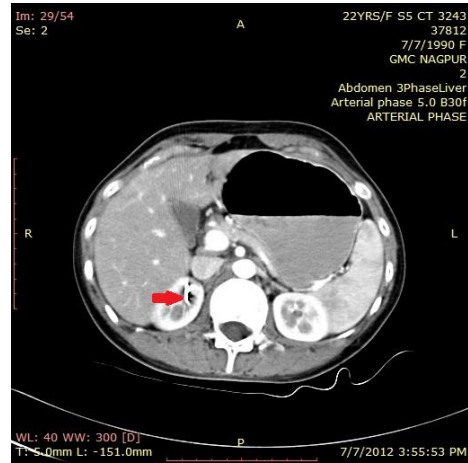


Fig 2: Intra op removal of needle from kidney

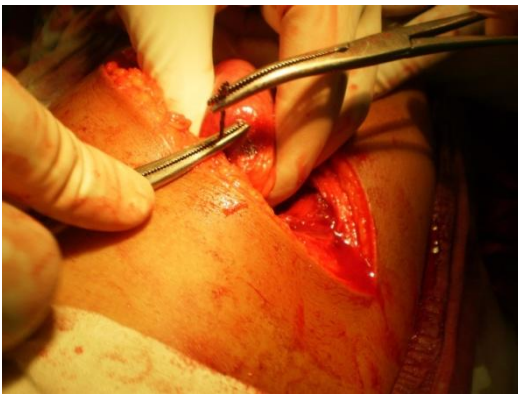

Fig 5 : Lateral view Abdomen showing position of needle

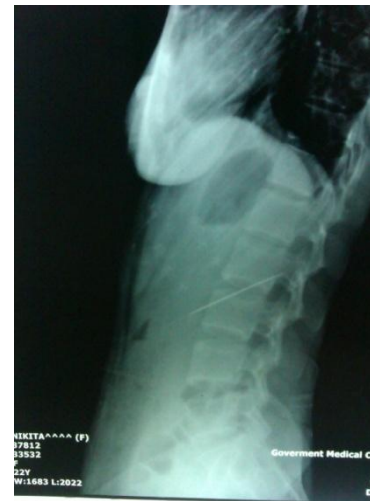

Fig 3 : X ray image of Foreign body

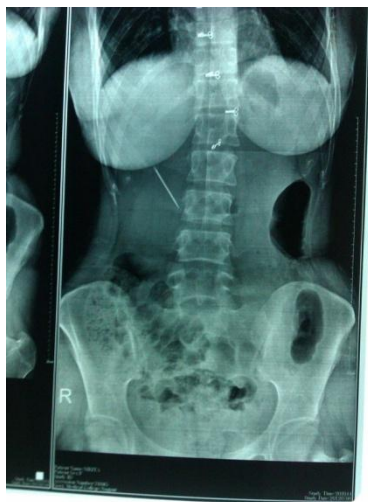

Fig 6 : Needle seen post op



References:

1. Baird, J. M. and Spence, H. M. (1968). Ingested foreign bodies migrating to the kidney from the gastrointestinal tract. *J. Urol.*, 99,675-480.
2. Foreign body in the kidney: report of a case
BRITISH JOURNAL OF UROLOGY Pg 360
Kyoku I, Fukatani T, Yasukawa S, Aoshi H, Hirano A, Komura T, Yamauchi T
3. Osmond, J. D. (1953). Foreign bodies in the kidney. *Radiology* 60,375-382.
4. Yue, K. P. and Johnson, H. W. (1967). Foreign body in the kidney: trans-intestinal migration. *J. Urol.*, 98, 172-174.